

The South American opossum, *Didelphis marsupialis*, from Brazil as another definitive host for *Sarcocystis speeri* Dubey and Lindsay, 1999

J. P. DUBEY^{1*}, C. E. KERBER², D. S. LINDSAY³, N. KASAI⁴ and H. F. J. PENA⁴

¹ United States Department of Agriculture, Agricultural Research Service, Livestock and Poultry Sciences Institute, Parasite Biology and Epidemiology Laboratory, Beltsville, Maryland, 20705-2350, USA

² Paddock Laboratório de Análises, Clínicas Veterinárias, Rua Pero Leão, 149-CEP 05423-060, São Paulo, Brazil

³ Center for Molecular Medicine and Infectious Diseases, Department of Biomedical Sciences and Pathobiology, Virginia–Maryland Regional College of Veterinary Medicine, Virginia Tech, 1410 Prices Fork Road, Blacksburg, VA 24061-0342, USA

⁴ Faculdade de Medicina Veterinária e Zootecnia da Universidade de São Paulo. AV. Prof. Dr. Orlando Marques de Paiva, 87, CEP 05508-000, São Paulo, Brazil

(Received 14 February 2000; revised 8 June 2000; accepted 19 June 2000)

SUMMARY

The North American opossum, *Didelphis virginiana*, is a definitive host for at least 3 species of *Sarcocystis*: *S. falcatula* Stiles 1983, *S. neurona* Dubey, Davis, Speer, Bowman, de Lahunta, Granstrom, Topper, Hamir, Cummings, Suter 1991, and *S. speeri* Dubey and Lindsay 1999. In order to identify species of *Sarcocystis* in the South American opossum, *D. marsupialis*, *Sarcocystis* sporocysts from the intestines of a naturally infected opossum (*D. marsupialis*) from Brazil were fed to 4 gamma-interferon knockout (KO) mice, a nude mouse, and 2 budgerigars (*Melopsittacus undulatus*). All 4 KO mice became ill and 1 died 42 days post-feeding (p.f.) of sporocysts, 1 was killed 44 days p.f. because of neurological signs, and 2 were killed 52 and 53 days p.f. because of abnormal gaits. Numerous sarcocysts were seen in the skeletal muscles of all 4 KO mice and they were structurally identical to *S. speeri* seen in KO mice fed sporocysts from *D. virginiana* from the United States and *D. albiventris* from Argentina. The nude mouse was killed 41 days p.f. because it appeared weak; schizonts were seen in sections of its liver and sarcocysts were seen in sections of skeletal muscles. *Sarcocystis speeri* was cultured in bovine turbinate cells inoculated with liver homogenate from this mouse. *Sarcocystis neurona* was not demonstrable in tissues of mice. The two budgerigars remained asymptomatic and *S. falcatula* was not found in their tissues when they were killed 29 days p.i. This is the first report of *S. speeri* from *D. marsupialis*.

Key words: *Sarcocystis speeri*, sporocysts, schizonts, *Didelphis marsupialis*, opossum.

INTRODUCTION

The North American opossum (*Didelphis virginiana*) is a definitive host for at least 3 pathogenic species of *Sarcocystis*; *S. falcatula* (Box, Meier & Smith, 1984), *S. neurona* (Fenger *et al.* 1997; Dubey & Lindsay, 1998), and *S. speeri* (Dubey & Lindsay, 1999). The sporocysts of these 3 species are similar morphologically, but can be distinguished by their pathogenicity and infectivity to birds and immunodeficient mice, e.g. *S. falcatula* is not infective for mice, whereas *S. neurona* and *S. speeri* are not infectious for birds and *S. falcatula* is infective to birds (Marsh *et al.* 1997; Dubey & Lindsay, 1998; Dubey, Speer & Lindsay, 1998). Both *S. neurona*

and *S. speeri* can induce encephalitis in mice associated with schizonts and merozoites (Dubey & Lindsay, 1999). Sarcocysts of *S. neurona* have not been detected in mice to date. However, sarcocysts were seen in gamma interferon knockout (KO) mice fed sporocysts of *S. speeri* (Dubey *et al.* 1998; Dubey & Lindsay, 1999). Recently, *S. speeri* and *S. falcatula* were reported from the South American opossum, *D. albiventris*, from Argentina (Dubey *et al.* 1999*b*, 2000*a–d*). We report *D. marsupialis* from Brazil as another definitive host for *S. speeri*.

MATERIALS AND METHODS

Sarcocystis sporocysts were obtained from an adult *D. marsupialis* submitted to the University of São Paulo, Brazil as part of a study of the *Sarcocystis* species observed in opossums in South America. The intestine was removed, the epithelium scraped from the small intestine in to a blender, homogenized and digested in 10% commercial bleach solution for

* Corresponding author: United States Department of Agriculture, Agricultural Research Service, Livestock and Poultry Sciences Institute, Parasite Biology and Epidemiology Laboratory, Beltsville, Maryland, 20705-2350, USA. Tel: +301 504 8128. Fax: +301 504 9222. E-mail: jdubey@lpsi.barc.usda.gov

Table 1. *Sarcocystis speeri* infections in mice fed sporocysts from an opossum, *Didelphis marsupialis*

Mouse type	Day p.i.*	Schizonts†	Sarcocysts†	Bradyzoites‡
KO 5880	Died 42	Brain	SKM, H, T	Not done
KO 5881	Killed 53	Not seen	SKM, H, T, O	Yes
KO 1248	Killed 52	Brain	SKM, H, T, O	Yes
KO 1249	Killed 44	Brain	SKM, T, O	Not done
Nude 6540	Killed 41	Liver	SKM	Not done
C57/Black	Killed 61	Not done	Not done	Negative
C57/Black	Killed 61	Not done	Not done	Negative

* Day post-inoculation.

† Results based on examination of tissue sections. H, heart; SKM, skeletal muscle; O, ocular muscles; T, tongue.

‡ Results based on acid-pepsin digestion.

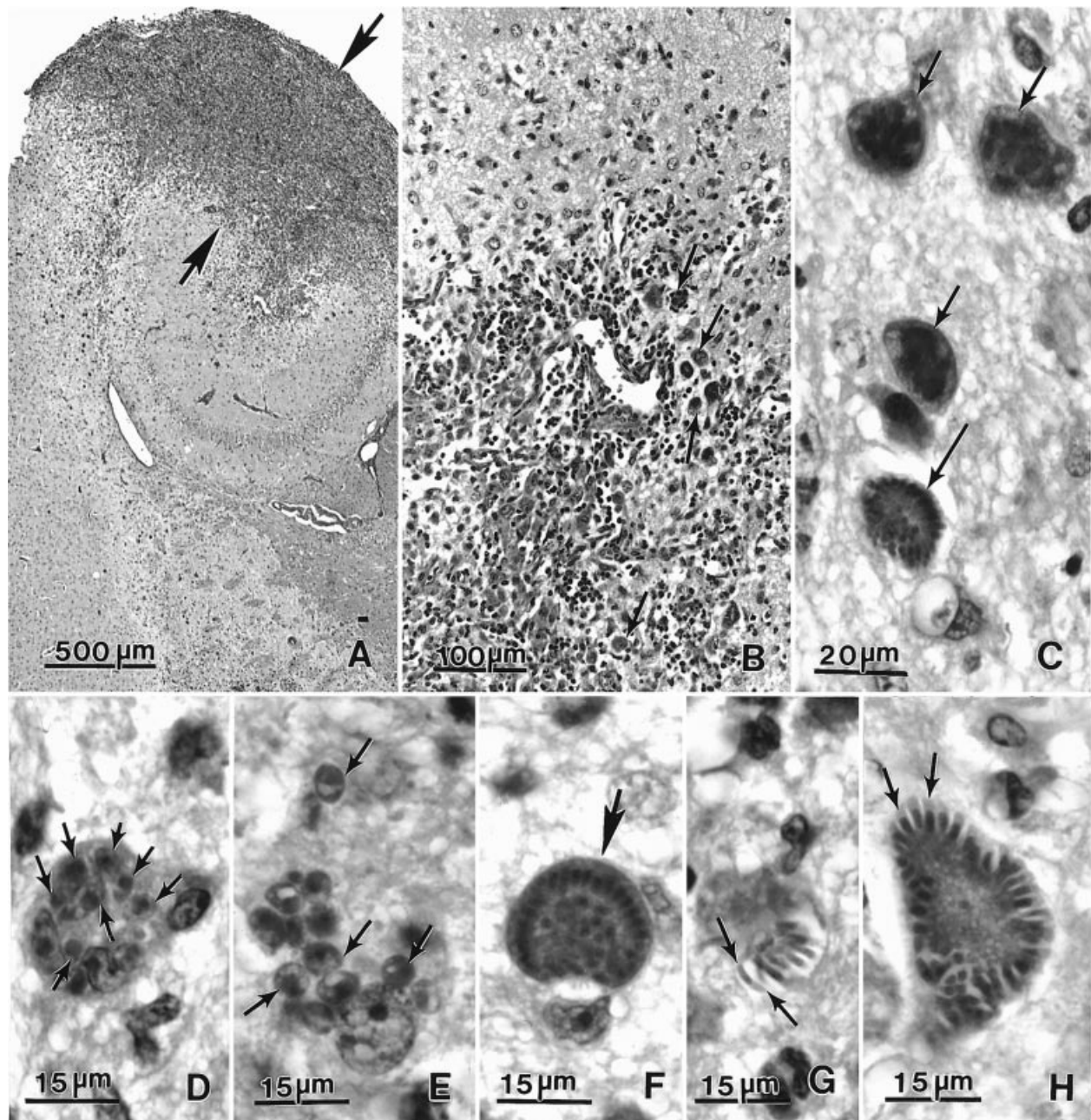


Fig. 1. For legend see opposite.

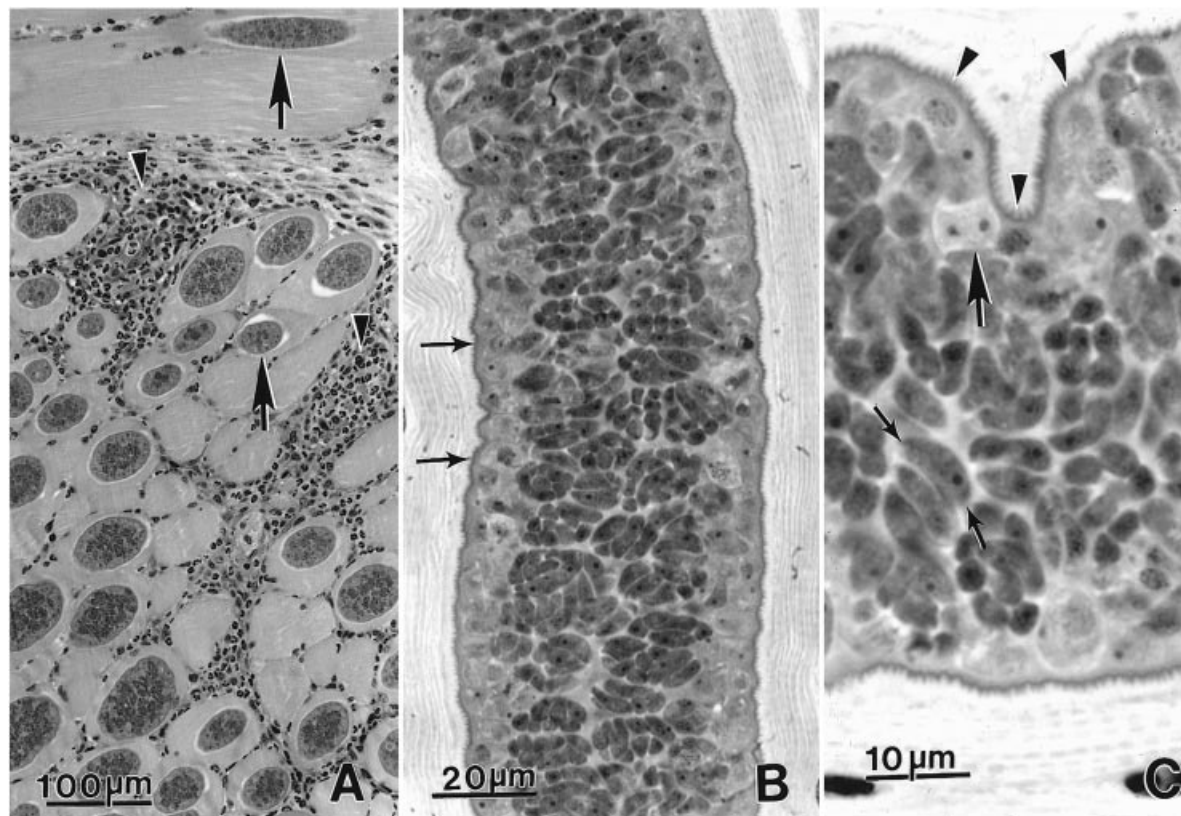


Fig. 2. Sarcocysts in sections of skeletal muscle of a KO mouse 53 days post-feeding of sporocysts from the opossum from Brazil. Haematoxylin and eosin stain. (A) Numerous sarcocysts (arrows) and focal inflammation (arrowheads) in abdominal muscle. (B) Longitudinal section of a sarcocyst. Note thin cyst wall (arrows). (C) Higher magnification of a sarcocyst showing cyst wall with villar protrusions (arrowheads), metrocytes (large arrow), and bradyzoites (small arrows).

10 min. After centrifugations to remove the bleach, the suspension was filtered through a series of metallic sieves (final exclusion 400 μm) and the sporocysts and debris concentrated by centrifugation ($\times 400\text{ g}$). The resulting material was stored in Hanks balanced salt solution (HBSS) containing 10 mg/ml streptomycin, 10000 U/ml penicillin, 500 U/ml myostatin, and 0.5 mg/ml fungizone. Sporocysts were shipped via air from São Paulo, Brazil to Beltsville, MD, USA. Sporocysts were stored at 4 °C until used in the present studies. At Beltsville sporocysts were fed to 4 KO mice (BALB/c-*lfn*^{im1Ts}), 1 nude (C57Bl/6JHFH11-Nu) mouse and 2 C57/Bl mice obtained from Jackson Laboratories (Bar Harbor, ME, USA). Two captive budgerigars (*Melopsittacus undulatus*) were each fed

the same dose of sporocysts fed to mice as described (Dubey & Lindsay, 1998). The budgerigars were killed 29 days post-feeding (p.f.) sporocysts.

Animals that were killed or died were necropsied. Portions of all internal organs, were fixed in 10% buffered formalin and processed for histology. Paraffin-embedded sections were cut at 5 μm and examined after staining with haematoxylin and eosin. For immunohistochemical staining, paraffin sections were reacted with anti-*S. neurona* and anti-*S. speeri* antibodies prepared in rabbits against culture-derived merozoites as described (Dubey & Lindsay, 1998, 1999; Dubey *et al.* 1999a). Briefly, anti-*S. neurona* serum was derived from an isolate obtained from a naturally infected opossum no. 8095 (Dubey *et al.* 1999a). The serum was diluted 1:10000 and it

Fig. 1. Lesions and schizonts of *Sarcocystis speeri* in the brain of knock-out mice 44 days after feeding sporocysts from *Didelphis marsupialis* from Brazil. Haematoxylin and eosin stain. (A) Severe inflammation (arrows) in the caudal lobe of cerebrum. (B) Higher magnification of the marked area (between arrows) in (A). Note gliosis, formation of new blood vessels, encephalitis and schizonts (arrows). (C) Four schizonts (arrows). (D–H) Schizonts in various stages of development under one magnification. (D) Eight young schizonts (arrows), presumably in one host cell. (E) A group of young schizonts (arrows) with individual nucleus. (F) Schizont with developing merozoites (arrow). (G) Schizont with elongated slender merozoites (arrows). (H) Schizont with thicker merozoites (arrows).

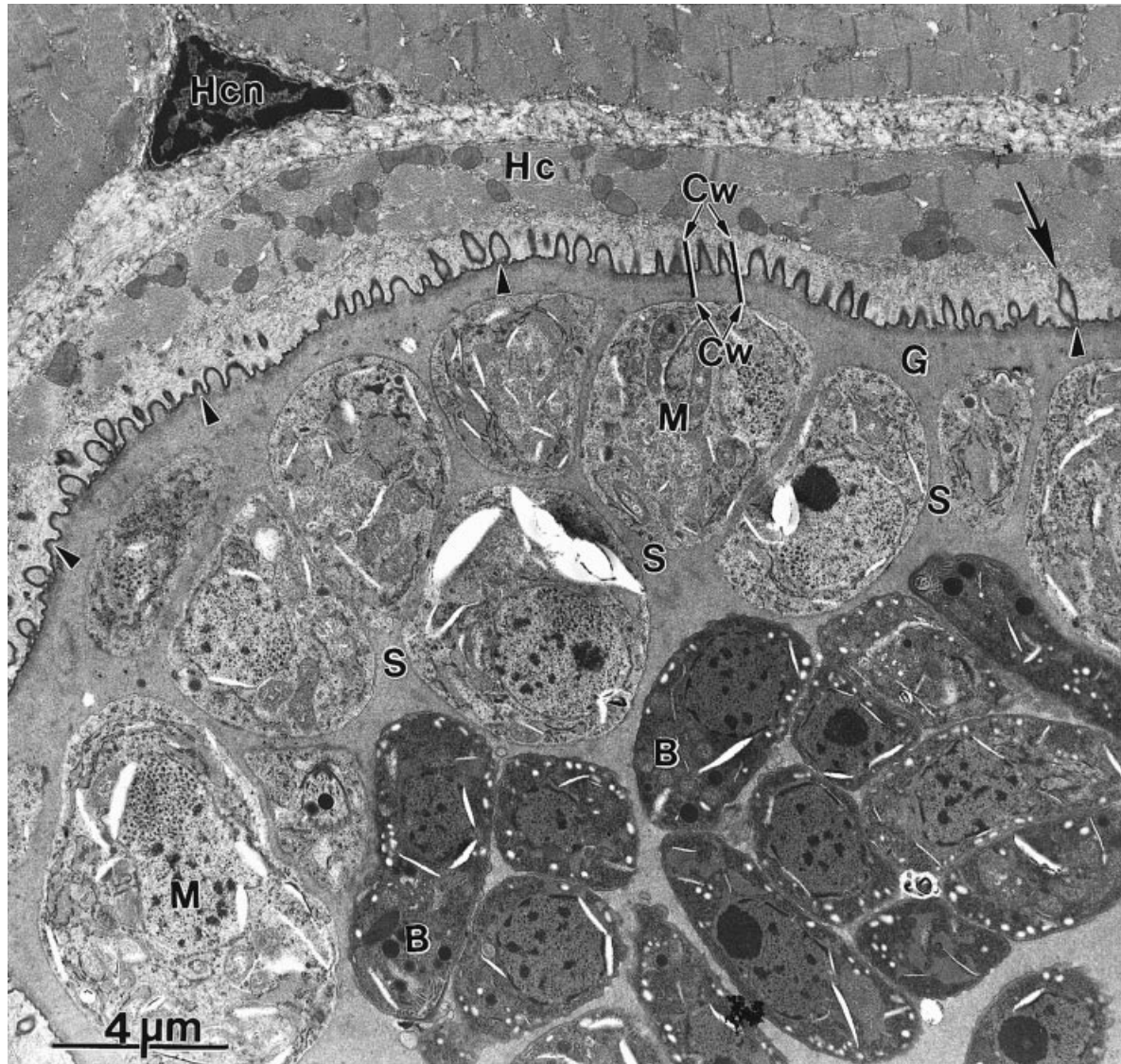


Fig. 3. Transmission electron photomicrograph of *Sarcocystis speeri* sarcocyst in the skeletal muscle of a KO mouse fed sporocysts from on the cyst wall (Cw) cut at different angles. One of the protrusions (arrow) is steple-shaped. Also note ground substance (G), metrocytes (M), bradyzoites (B), septa (S), host cell (Hc), and host cell nucleus (Hcn).

does not react with *S. speeri* schizonts and sarcocysts or with any other related apicomplexans (Dubey & Hamir, 2000). The anti-*S. speeri* serum was obtained using an isolate from a naturally infected opossum from Argentina (Dubey & Lindsay, 1999). It was diluted 1:5000 and it does not react with *S. neurona* schizonts.

The carcasses of KO mice killed 52 and 53 days p.f. and of C57/Bl mice killed 73 days p.f. were homogenized in a blender, digested in acid pepsin solution, and the digest examined microscopically for *Sarcocystis* bradyzoites (Dubey, Speer & Fayer, 1989).

The nude mouse was killed 41 days p.f. Attempts were made to cultivate *S. speeri* from the liver of this mouse. Liver homogenate was inoculated onto

bovine turbinate cells (BT cells, ATCC CRL 1390, American Type Culture collection, Rockville, MD, USA) as described (Dubey *et al.* 2000b).

Portions of skeletal muscle from KO mouse 5881 (Table 1) were fixed in 3% (v/v) glutaraldehyde in phosphate buffer and later processed for ultrastructural examination at the Center for Molecular Medicine and Infectious Diseases, Virginia–Maryland Regional College of Veterinary Medicine, Virginia Tech, Blacksburg, Virginia, USA. Tissues were post-fixed in 1% (w/v) osmium tetroxide, dehydrated in a series of ethanols, passed through 2 changes of propylene oxide, and embedded in Poly/Bed 812 resin (Polysciences Inc., Warrington, PA, USA). Thin sections were stained with uranyl acetate and lead citrate and examined with a JOEL-

100 CX II transmission electron microscope (TEM) operating at 80 kV.

RESULTS

All 4 KO mice fed sporocysts became ill around 40 days p.f. One mouse died 42 days p.f., and 3 were killed 44, 52, 53 days p.f. because they had neurological signs or had difficulty walking (Table 1). Mice that died or were killed 42 and 52 days p.f. had severe encephalitis associated with numerous schizonts and merozoites. In the mouse killed 52 days p.f., there was a large lesion in the caudal lobe of the cerebrum with necrosis of the neuropil and marked gliosis (Fig. 1A). Myriads of *Sarcocystis* schizonts in all stages of development were seen (Fig. 1B–H). There were groups of young round to oval-shaped small schizonts (Fig. 1D, E) that resembled metrocytes. These groups of schizonts in similar stages of development probably resulted from merozoites from parent schizonts without leaving the host cell. This phenomenon is typical of *S. falcatula*, *S. neurona* and *S. speeri* asexual development in cell culture (Lindsay *et al.* 1999; Dubey *et al.* 1999b, 2000b).

Sarcocysts were seen in all 4 KO mice. These sarcocysts were thin walled and had characteristic villar protrusions of *S. speeri* (Fig. 2). Numerous sarcocysts were seen in skeletal muscle including tongue, diaphragm, abdomen and ocular muscles. A few sarcocysts were seen in the myocardium. Bradyzoites were seen in pepsin digests of muscles of mice killed 52 and 53 days p.f. *Sarcocystis* zoites were not seen in muscle digests of the C57/Bl mice.

Schizonts in various stages of development were seen in cell culture by day 15 post-infection (p.i.). On day 28 p.i. several isolated groups of asexual development were seen. Occasionally, schizonts contained a residual body. The merozoites and schizonts were structurally similar to those of *S. speeri* cultured from the liver of *D. albiventris* from Argentina (Dubey *et al.* 2000).

Fourteen sarcocysts were examined using TEM. Metrocytes were the most abundant stage present in sarcocysts. The primary sarcocyst wall consisted of the parasitophorous vacuolar membrane and an underlying electron-dense layer. Villar protections came off the sarcocyst wall and contained only ground substance internally (Fig. 3). The ground substance was also present immediately below the primary sarcocyst wall and divided the sarcocyst into compartments. Bradyzoites were few in number but contained all the organelles typical of this stage.

Schizonts and merozoites in mice reacted positively with anti-*S. speeri* serum but not with anti-*S. neurona* serum. Neither schizonts nor sarcocysts were seen in tissues of the two budgerigars.

DISCUSSION

Schizonts observed in tissues of the KO and nude mice were structurally similar to those of *S. speeri* (Dubey & Lindsay, 1999). The results of the present study indicate the *S. speeri* occurs naturally in Brazil in *D. marsupialis*.

Sarcocystis neurona-induced equine protozoal encephalomyelitis (EPM) is a serious neurological disease of horses in North America, Brazil and Panama (Dubey *et al.* 1991; MacKay, 1997). The distribution of EPM closely parallels the range and distribution of the opossum, *D. virginiana*. Whether *D. albiventris* and *D. marsupialis* are also a host for *S. neurona* is unknown. One way to identify the presence of *S. neurona* in opossum faeces is by bioassay in gamma interferon knockout or nude mice (Dubey & Lindsay, 1998). The results of the present investigation indicate that *D. marsupialis* is another definitive host for *S. speeri* and should be considered when attempting to isolate *S. neurona* sporocysts from opossums in South America.

REFERENCES

- BOX, F. D., MEIER, J. L. & SMITH, J. H. (1984). Description of *Sarcocystis falcatula* Stiles, 1893, a parasite of birds and opossums. *Journal of Protozoology* **31**, 521–524.
- DUBEY, J. P., DAVIS, S. W., SPEER, C. A., BOWMAN, D. D., DE LAHUNTA, A., GRANSTROM, D. E., TOPPER, M. J., HAMIR, A. N., CUMMINGS, J. F. & SUTER, M. M. (1991). *Sarcocystis neurona* n. sp. (Protozoa: Apicomplexa), the etiologic agent of equine protozoal myeloencephalitis. *Journal of Parasitology* **77**, 212–218.
- DUBEY, J. P. & HAMIR, A. (2000). Immunohistochemical confirmation of *Sarcocystis neurona* infections in raccoons, mink, cat, skunk and pony. *Journal of Parasitology* (in the Press).
- DUBEY, J. P. & LINDSAY, D. S. (1998). Isolation in immunodeficient mice of *Sarcocystis neurona* from opossum (*Didelphis virginiana*) feces, and its differentiation from *Sarcocystis falcatula*. *International Journal for Parasitology* **28**, 1823–1828.
- DUBEY, J. P. & LINDSAY, D. S. (1999). *Sarcocystis speeri* n. sp. (Protozoa: Sarcocystidae) from the opossum (*Didelphis virginiana*). *Journal of Parasitology* **85**, 903–909.
- DUBEY, J. P., LINDSAY, D. S., REZENDE, P. C. B. & COSTA, A. J. (2000a). Characterization of a new *Sarcocystis falcatula*-like parasite from the South American opossum, *Didelphis albiventris* from Brazil. *Journal of Eukaryotic Microbiology* (in the Press).
- DUBEY, J. P., MATTSO, D. E., SPEER, C. A., BAKER, R. J., MULROONEY, D. M., TORNQUIST, S. J., HAMIR, A. N. & GERROS, T. C. (1999a). Characterization of *Sarcocystis neurona* isolate (SN6) from a naturally infected horse from Oregon. *Journal of Eukaryotic Microbiology* **46**, 500–506.
- DUBEY, J. P., SPEER, C. A. & FAYER, R. (1989). *Sarcocystosis of Animals and Man*. CRC Press, Boca Raton, Florida.

- DUBEY, J. P., SPEER, C. A. & LINDSAY, D. S. (1998). Isolation of a third species of *Sarcocystis* in immunodeficient mice fed feces from opossums (*Didelphis virginiana*) and its differentiation from *Sarcocystis falcatula* and *Sarcocystis neurona*. *Journal of Parasitology* **84**, 1158–1164.
- DUBEY, J. P., SPEER, C. A. & LINDSAY, D. S. (2000*b*). *In vitro* cultivation of schizonts of *Sarcocystis speeri* Dubey and Lindsay, 1999. *Journal of Parasitology* **86**, 671–678.
- DUBEY, J. P., SPEER, C. A., BOWMAN, D. D., HORTON, K. M., VENTURINI, C. & VENTURINI, L. (2000*d*). Experimental transmission of *Sarcocystis speeri* from the South American opossum (*Didelphis albiventris*) to the North American opossum (*Didelphis virginiana*). *Journal of Parasitology* **86**, 624–627.
- DUBEY, J. P., VENTURINI, L., VENTURINI, M. C. & SPEER, C. A. (2000*c*). Isolation of *Sarcocystis speeri* Dubey and Lindsay, 1999 from the South American opossum (*Didelphis albiventris*) from Argentina. *Journal of Parasitology* **86**, 160–163.
- DUBEY, J. P., VENTURINI, L., VENTURINI, C., BASSO, W. & UNZAGA, J. (1999*b*). Isolation of *Sarcocystis falcatula* from the South American opossum (*Didelphis albiventris*) from Argentina. *Veterinary Parasitology* **86**, 239–244.
- FENGER, C. K., GRANSTROM, D. E., GAJADHAR, A. A., WILLIAMS, N. M., MCCRILLIS, S. A., STAMPER, S., LANGEMEIER, J. L. & DUBEY, J. P. (1997). Experimental induction of equine protozoal myeloencephalitis in horses using *Sarcocystis* sp. sporocysts from the opossum (*Didelphis virginiana*). *Veterinary Parasitology* **68**, 199–213.
- LINDSAY, D. S., DUBEY, J. P., HORTON, K. M. & BOWMAN, D. D. (1999). Development of *Sarcocystis falcatula* in cell cultures demonstrates that it is different from *Sarcocystis neurona*. *Parasitology* **118**, 227–233.
- MACKAY, R. J. (1997). Equine protozoal myeloencephalitis. *Veterinary Clinics of North America: Equine Practice* **13**, 79–96.
- MARSH, A. E., BARR, B. C., TELL, L., KOSKI, M., GREINER, E., DAME, J. & CONRAD, P. A. (1997). *In vitro* cultivation and experimental inoculation of *Sarcocystis falcatula* and *Sarcocystis neurona* merozoites into budgerigars (*Melopsittacus undulatus*). *Journal of Parasitology* **83**, 1189–1192.