

The Effects a Novel Extracapsular Suture Technique (Lateral Extracapsular Suture System or LESS^a) on the Kinematics of the Cranial Cruciate Deficient Stifle.

Laura L. D'Amico

Thesis submitted to the faculty of the Virginia Polytechnic Institute and State University in partial fulfillment of the requirements for the degree of

Master of Science
In
Biomedical and Veterinary Sciences

Otto I. Lanz, Committee Chair
Tisha A. Harper
Ron M. McLaughlin

May 17, 2013
Blacksburg, VA

Keywords: Lateral extracapsular suture system, Cranial cruciate ligament, Kinematics, Cranial tibial translation, Internal rotation

Copyright 2013, Laura L. D'Amico

The Effects a Novel Extracapsular Suture Technique (Lateral Extracapsular Suture System or LESS^a) on the Kinematics of the Cranial Cruciate Deficient Stifle.

Laura L. D'Amico

ABSTRACT

Objective: To evaluate the relative position of the femur and tibia in cranial cruciate ligament (CCL) intact stifles, CCL deficient stifles, and stifles following a novel extracapsular procedure (lateral extracapsular suture system or LESS^a) under load at specific joint angles.

Study Design: In vitro biomechanical study.

Methods: Twenty pelvic limbs from 11 dogs were used to evaluate the relative position of the femur and tibia between 3 stifle conditions (CCL intact, CCL deficient, and LESS^a treated) at a load of 30 % and stifle angles of 125°, 135°, and 145° using electromagnetic tracking sensors.

Results: Cranial cruciate ligament deficient stifles had significantly greater ($p < 0.0001$) cranial displacement and internal rotation of the tibia relative to the femur than CCL intact stifles or LESS^a treated stifles at all stifle angles. Cranial displacement of the tibia relative to the femur for CCL intact and LESS^a treated were not significantly different from one another at stifle angles of 125°, but were significantly different at stifle angles of 135° ($p = 0.0182$) and 145° ($p = 0.0012$). There was no significant difference in internal rotation of the tibia relative to the femur between CCL intact and LESS^a treated stifles at any of the stifle angles.

Conclusion: LESS^a effectively decreases cranial tibial displacement and eliminates internal rotation of the tibia relative to the femur in the CCL deficient stifle at stifle angles (125°, 135°, and 145°).

ACKNOWLEDGEMENTS

Grant Information: The author would like to recognize the Virginia Veterinary Medical Association for financial support through the Veterinary Memorial Fund and Kyon, Pharma, Inc. for donating testing materials for the project.

Acknowledgements: The author would like to thank Kyon Pharma, Inc. for donating testing materials for this project, Pam Arnold for her help with acquisition and storage of the cadaver specimens, Dr. Steve Elder for providing the custom-built mounting bracket and loading frame, and Dr. Stephen Werre for his help with statistical analysis. The author would additionally like to thank the graduate committee members listed above as well as Dr. Karanvir Aulakh and Dr. Ryan Butler for their assistance in project design and document preparation.

TABLE OF CONTENTS

ABSTRACT.....	ii
ACKNOWLEDGEMENTS.....	iii
TABLE OF CONTENTS.....	iv
INTRODUCTION	1
CHAPTER I. Literature Review	2
A. Canine Stifle Anatomy and Function	2
1. Joint.....	2
2. Bones.....	2
3. Muscles	4
4. Fascia	6
5. Arterial Blood Supply	6
6. Venous Drainage.....	8
7. Lymphatic Drainage.....	8
8. Nerves	8
9. Joint Capsule.....	9
10. Synovial Fluid.....	10
11. Articular Cartilage	10
12. Meniscus	11
13. Ligaments.....	12
B. Kinematics of the Normal and Cranial Cruciate Ligament Deficient Stifle	15
C. Pathophysiology of Cranial Cruciate Ligament Disease	18
1. General.....	18
a. Trauma	19
b. Genetics.....	19
c. Conformation	19
d. Blood Supply	21
e. Degeneration	21
2. Meniscus	23
3. Osteoarthritis.....	23
D. Diagnosis.....	24
1. Signalment	24
2. History.....	24
3. Physical exam	24
a. Lameness.....	24
b. General Palpation.....	24
c. Cranial Drawer	25
d. Tibial Compression Test.....	25
4. Arthrocentesis	25
5. Imaging	26
a. Radiographs.....	26
b. Computed Tomography	26
c. Ultrasound	26
d. Magnetic Resonance Imaging.....	26
6. Arthrotomy/Arthroscopy.....	27
E. Treatment.....	27

1. Conservative Management.....	27
2. Surgical Options.....	27
a. Intracapsular Techniques	27
i. Paatsama	27
ii. Over the Top	28
iii. Under and Over.....	28
b. Extracapsular Techniques	28
i. Imbrication.....	28
ii. Lateral Retinacular Imbrication	29
iii. Modified Retinacular Imbrication	29
iv. Three-in-one	29
v. Four-in-one Over the Top.....	29
vi. Lateral Suture.....	29
vii. Fibular Head Transposition	30
c. Extracapsular Osteotomy Techniques.....	30
i. Cranial Tibial Wedge Osteotomy (CTWO).....	30
ii. Tibial Plateau Leveling Osteotomy (TPLO)	30
iii. Combined CTWO and TPLO	31
iv. Tibial Tuberosity Advancement (TTA).....	31
v. Proximal Tibial Intraarticular Osteotomy (PTIO)	32
vi. Triple Tibial Osteotomy (TTO).....	32
vii. Chevron Wedge Osteotomy (CVWO)	32
F. Lateral Suture.....	32
1. Surgical Technique	33
2. Modifications	33
a. Suture Configurations	33
b. Suture Types	33
c. Suture Securing Methods	33
d. Suture Anchors.....	34
e. Isometry	34
f. Tightrope.....	35
CHAPTER II. The effects a novel extracapsular suture technique (lateral extracapsular suture system or LESS ^a) on the kinematics of the cranial cruciate deficient stifle	36
A. Objectives.....	36
B. Materials and Methods	36
1. Specimen Preparation	36
2. Radiographic Analysis.....	36
3. Cranial Cruciate Ligament Rupture Simulation and Lateral Extracapsular Suture System Procedure ^a	36
4. Testing Protocol.....	37
5. Biomechanical Testing Protocol	38
6. Data Analysis	38
7. Statistical Analysis.....	38
C. Results	39
1. General.....	39
2. Cranial-Caudal Tibial Displacement.....	39

3. Proximal-Distal Tibial Displacement	40
4. Medial-Lateral Tibial Displacement	40
5. Azimuth.....	40
6. Elevation	41
7. Roll.....	41
D. Discussion	41
1. Hypotheses.....	41
2. Design	42
3. Materials	42
4. Complications	42
5. Cranial-Caudal Tibial Displacement.....	43
6. Proximal-Distal Tibial Displacement	43
7. Medial-Lateral Tibial Displacement.....	44
8. Azimuth.....	44
9. Elevation	44
10. Roll.....	45
11. Limitations	45
E. Conclusions.....	45
REFERENCES	47
APPENDIX.....	58
A. Figures.....	58
1. Figure 1: Femoral Screws	58
2. Figure 2: Lateral View of LESS ^a	59
3. Figure 3: Left Cranial-Caudal Radiograph	60
4. Figure 4: Left Lateral Radiograph	61
5. Figure 5: Right Cranial-Caudal Radiograph	62
6. Figure 6: Right Lateral Radiograph	63
7. Figure 7: Cannulated Tibial Screw	64
8. Figure 8: Medial view of LESS ^a	65
9. Figure 9: Plastic Stopper.....	66
10. Figure 10: Placement of the Plastic Stopper	67
11. Figure 11: Placement of Suture Knots	68
12. Figure 12: Loading Frame	69
13. Figure 13: Biomechanical Testing Setup.....	70
14. Figure 14: Six Degrees of Freedom.....	71
15. Figure 15: Six Degrees of Freedom	72
B. Tables.....	73
1. Table 1: Mean +/- Standard Deviation (x, y, z).....	73
2. Table 2: Mean +/- Standard Deviation (azimuth, elevation, roll).....	73
3. Table 3: Least Square Mean Difference (x, y, z).....	74
4. Table 4: Least Square Mean Difference (azimuth, elevation, roll).....	74
5. Table 5: Comparisons of Treatment (x, y, z).....	75
6. Table 6: Comparisons of Treatment (azimuth, elevation, roll).....	75
7. Table 7: Comparisons of Stifle Angle (x, y, z).....	76
8. Table 8: Comparisons of Stifle Angle (azimuth, elevation, roll).....	76

INTRODUCTION

Cranial cruciate ligament (CCL) rupture is an important orthopedic condition affecting the canine stifle (1). The precise pathophysiologic process responsible for rupture still remains largely unknown (2, 3) and may be the combined result of multiple predisposing factors (3, 4). It is the most significant cause of lameness in canine patients (1, 2, 5-8) and leads to severe and potentially debilitating osteoarthritis (2, 4, 6).

The CCL serves to counteract cranial tibial displacement, internal rotation of the tibia relative to the femur, as well as hyperextension of the stifle (9). Despite the numerous treatment options available, complete restoration of normal joint mechanics is difficult to achieve and osteoarthritis continues to progress (8, 10-16). The ideal procedure would restore normal joint function and stifle biomechanics, and thus prevent the progression of osteoarthritis (14). To restore normal joint function and biomechanics, elimination of cranial tibial displacement and internal rotation of the tibia relative to the femur resulting from CCL rupture at all stifle angles, while maintaining normal range of motion of the stifle is necessary.

The lateral extracapsular suture system (LESS)^a is a novel technique that utilizes a cortical bone screw in the femur and a cannulated cortical bone screw in the tibia to connect two strands of suture (Dyneema^b and Gortex^c leader line material). The screws are positioned at points in the stifle joint that are approaching isometry (17-19). The suture is wrapped around the femoral screw as it exits providing additional length as the stifle moves from extension to flexion. This is important, because significant increases in suture tension can occur in stifle angles representing flexion (19). Potential advantages of this system are bony fixation of the suture, near isometric placement of suture, and improved range of motion of the stifle due to lengthening of the suture during stifle flexion.

CHAPTER I. Literature Review

A. Canine Stifle Anatomy and Function

1. Joint

The canine stifle is classified as a complex condylar synovial joint (20). It is a complex joint, meaning that it has more than one functional articulation (21). The stifle is composed of two functional articulations: the femorotibial articulation and the femoropatellar articulation (20, 21). The femorotibial component consists of the articulation between the spherical condyles of the femur and the elliptical cavity of the tibial condyles (20). The femoropatellar component consists of the articulation between the smooth convex caudal surface of the patella and the concave femoral trochlea (20, 22). The stifle is also a condylar joint, which means that it contains an articulation between a bone with a spherical shape and another bone with an elliptical cavity (23). The condylar component of the stifle is the femorotibial articulation (20). In addition, the stifle is a synovial joint which means that it is a joint that allows relatively free movement and it is composed of an articular cavity, articular capsule, synovial fluid, articular cartilage, and subchondral bone (20, 24, 25). The stifle is a unique joint that has many different components that lend to its complexity (26).

The predominant motion that occurs in the stifle is extension and flexion in the cranial-caudal plane (21, 22, 26, 27). However, due to the complex condylar articulation of the femur and tibia, other motions can also occur (26, 27). In addition to extension and flexion of the stifle, cranial-caudal, proximal-distal (distraction-compression), and medial-lateral motion of the femur and tibia can occur (27). Varus-valgus angulation (adduction-abduction) and internal-external rotation can occur as well (27). The degree and situations in which these motions are seen are largely dependent on the complex anatomy of the stifle and how these anatomic structures interact (26).

Joints are composed of bones which serve as sites for muscle and ligamentous attachment as well as act as levers for muscular actions (26, 28). The bones that compose the stifle consist of long bones and sesamoid bones (20, 22, 26, 29). There are three long bones present which include the femur, tibia, and fibula (20, 26, 30). There are also four sesamoid bones in the stifle which are the patella, medial and lateral fabellae, and the popliteal sesamoid (20, 22, 26, 29).

2. Bones

The most proximal bone of the stifle is the distal aspect of the femur and its unique anatomy contributes to the movement of the stifle (20). The distal diaphysis of the femur curves cranially and is cylindrical in shape cranially, medially, and laterally, with the caudal aspect assuming a more flat shape (28). Distally toward the metaphysis and epiphysis, the femur is directed more caudally and four distinct surfaces become apparent (28). The cranial aspect of the distal femur contains the site of its articulation with the patella, the femoral trochlea (20, 22, 26, 28). The femoral trochlea is a smooth, concave surface with two trochlear ridges forming its medial and lateral boundaries (28, 29). The caudal and lateral aspect of the distal femur comprises the lateral femoral condyle and the caudal and medial aspect of the distal femur

comprises the medial femoral condyle (28). Each condyle contains a site of articulation with the tibia (20, 26, 28). The lateral condyle is convex cranially and laterally, and the medial condyle is convex cranially and medially (28). The lateral condyle contains a small depression cranially lateral to the lateral trochlear ridge known as the extensor fossa (29). The medial condyle differs from the lateral condyle in that it is smaller and it is less convex in shape (28). The caudal aspect of each condyle contains a depression on the proximal surface, which is the site of articulation with the fabellae (22, 26, 28). Two protuberances are located proximal to these depressions one on the medial and one on the lateral aspect, referred to as the medial and lateral supracondylar tuberosities, respectively (26, 28). Distal to these tuberosities and proximal to the areas of articulation with the fabella on the caudal aspect of the femur is the popliteal surface (28). Between the two condyles is a space known as the intercondylar fossa, which is proximolateral to distomedial in orientation, causing it to be slightly oblique and the caudal outlet to be oriented more laterally relative to the cranial outlet (28, 31). Medial and lateral epicondyles are located cranially and proximally to the medial and lateral condyles respectively (28). Alterations in the unique anatomy of the femur can alter function of the stifle as well as lead to damage to other anatomic structures (26).

The distal aspect of the stifle includes the proximal aspect of the tibia (20). This aspect of the tibia is triangular in shape, with the apex oriented cranially and the base oriented caudally (28). The dorsal surface of the tibia is relatively flat and is composed of a medial and lateral condyle and central intercondylar area caudally and the proximal aspect of the tibial tuberosity cranially (22, 28, 29). The medial and lateral tibial condyles are the sites of articulation with the medial and lateral femoral condyles, respectively (20). The medial tibial condyle is more elliptical in shape and the lateral tibial condyle is more circular in shape (26, 28). Both condyles are sloped caudally in the cranial-caudal direction (32). The area between the tibial condyles is divided into a cranial intercondylar area, intercondylar eminence and caudal intercondylar area (28). The cranial intercondylar area is an elliptical recessed area cranial to the intercondylar eminence (26, 28). The intercondylar eminence extends outward from the dorsal surface and has two articular projections on its medial and lateral sides that are referred to as the medial and lateral intercondylar tubercles (28, 29). The caudal intercondylar area is an elliptical recessed area, similar to the cranial intercondylar area, although it is smaller and located caudal to the intercondylar eminence (22, 28). The popliteal notch is a recessed area on the caudal aspect of the tibia between the tibial condyles (22, 26, 28). The caudal and lateral surface of the lateral tibial condyle contains an oblique depression which articulates with the fibular head (26, 28). Cranial to the cranial intercondylar area is the tibial tuberosity (28). The tibial tuberosity is a four-sided polygonal projection that extends from the cranial surface of the tibia proximally (22, 28). Lateral to the tibial tuberosity is a depression that extends caudally to the articular surface of the lateral tibial condyle, which is referred to as the extensor groove (22, 26, 28). Like the femur, alterations in the precise anatomy of the tibia can lead to dysfunction of the stifle and damage to other important anatomic structures (26).

The proximal aspect of the fibula is located laterally at the distal extent of the stifle (28). The fibula is similar in length to the tibia, however it is much smaller in width relative to the tibia (26, 28). The fibular head is the most proximal extent of the fibula and is flattened in the medial to lateral direction but is rounded in the cranial to caudal direction (28). The fibular head contains a small projection medially that articulates with the depression located caudally and

laterally to the tibial condyle (22, 26, 28). The fibula is not directly involved with the motion of the stifle, but it does serve a role for the attachment of ligaments and muscles that influence movements of the joint (21, 28).

The patella is a sesamoid bone located cranially and proximally in the stifle (28). The patella is rounded at its base proximally and tapers at its apex distally (26, 28, 33). It also curves cranially along the trochlea of the femur (28). The caudal surface of the patella that articulates with the trochlea of the femur is smooth and convex (22, 28). Two fibrocartilages are present on the medial and lateral aspect of the patella referred to as the parapatellar fibrocartilages that articulate with the medial and lateral trochlear ridges of the femur respectively (22, 28). The patella is the largest sesamoid bone present in the canine skeletal system and arises as an ossification center in the tendon of the quadriceps muscle group (28).

The medial and lateral fabellae are sesamoid bones located caudally and proximally to the medial and lateral femoral condyles, respectively (29). The medial fabella is smaller than the lateral fabella and it is rounded distally and more pointed proximally (22, 28). The larger lateral fabella is more rounded in shape, except for a relatively level articular surface and a truncation at its distal extent (28).

The popliteal sesamoid is located caudally in the area of the stifle and articulates with the lateral tibial condyle (28). It is oriented at the level of or proximal to the tibial plateau (34). It is the smallest sesamoid of the four sesamoids of the stifle and can occasionally be absent (28, 29, 34).

3. Muscles

The muscles of the pelvic limb are an important component of the stifle. The muscles that influence the stifle can be divided into rump muscles, thigh muscles, and muscles of the distal limb (26, 35). These muscles play a role in movement and stability of the stifle (35, 36).

For the most part the rump muscles, located on the lateral aspect of the pelvis, are muscles that influence the hip, however the tensor fasciae lata muscle does have some influence on the stifle (26, 35). This muscle originates on the ventral iliac spine and inserts on the lateral fascia of the femur and therefore the patella (26, 35). The tensor fasciae lata muscle, has some influence on extension of the stifle, because of the location of its insertion (35).

Muscles of the thigh have the greatest influence on the stifle (35). This group of muscles can be further divided into cranial, caudal, and medial muscles of the thigh (26, 35). The muscles of the caudal thigh are the biceps femoris, caudal crural abductor, semitendinosus, and semimembranosus (35). The biceps femoris is located on the caudolateral aspect of the thigh (26). It has a cranial (superficial) and caudal (deep) head (35). The origin of the cranial head is the sacrotuberous ligament and the ischiatic tuberosity and the origin of the caudal head is the ischiatic tuberosity (26, 35). The cranial head inserts on the tibial tuberosity through an aponeurosis that fuses with the fascia lata and fascial covering of the quadriceps, which connect to the patella and patellar ligament (35). The caudal head inserts on the cranial border of the tibia (26, 35). The cranial head extends the stifle and the caudal head flexes the stifle (26). The

caudal crural abductor is located beneath the caudal border of the biceps femoris muscle, it originates from the sacrotuberous ligament, inserts on the crural fascia, and flexes the stifle (35). The biceps femoris muscle also imposes a caudal force on the tibia (36). The semitendinosus muscle is located on the caudal aspect of the thigh, originates on the ischiatic tuberosity, inserts on the medial aspect of the body of the tibia, and flexes the stifle (26, 35). The semimembranosus muscle is located on the caudal and medial aspect of the thigh, it originates from the ischiatic tuberosity, contains a cranial belly that inserts through an aponeurosis to the gastrocnemius and medial femoral lip, a caudal belly that inserts under the medial collateral ligament at the medial tibial condyle, flexes the stifle, and imposes a caudal force on the tibia (35, 36).

The muscles of the cranial thigh that influence the stifle include the quadriceps femoris and the muscularis articularis genus (26, 37). The quadriceps femoris muscle group is further divided into the rectus femoris, vastus medialis, vastus lateralis, and vastus intermedius (26, 35). The rectus femoris is located cranially, originates on the iliopubic eminence, inserts on the patella and tibial tuberosity through the patellar ligament, and extends the stifle (26, 35). The vastus medialis is located cranially and medially, it originates on the trochanteric crest of the femur cranially and the medial lip of the femur medially, inserts on the patella, and extends the stifle (35). The vastus lateralis is located cranially and laterally, it originates on the transverse line of the femur and the lateral lip of the femur, it inserts on the patella, and extends the stifle (35). The vastus intermedius is located cranially and laterally, it originates with the vastus lateralis at the lateral aspect of the proximal femur, it inserts on the vastus medialis and extends the stifle (26, 35). The vastus intermedius is considered the weakest component of the quadriceps femoris muscle (35). The quadriceps muscle group also imposes a cranioproximal force on the tibia (36). The muscularis articularis genus originate on the cranial aspect of the distal femur proximal to the joint capsular attachment of the femoropatellar joint and insert on the joint capsule of the femoropatellar joint (37). It is thought to extend the stifle and provide tension on the proximal portion of the joint capsule of the stifle to prevent interposition between the femur and patella as the stifle moves (35, 37). It may also influence limb movement through receiving and transmitting proprioceptive information about the stifle (37).

The medial muscles of the thigh that influence the stifle are the sartorius and the gracillis muscles (26). The sartorius muscle is located cranially and is further divided into a cranial and caudal part (26, 35). The cranial portion originates on the iliac crest as well as the cranial aspect of the ventral iliac spine, it inserts on the medial fascia of the femur proximal to the patella, and it extends the stifle (26, 35). The caudal portion originates on the central portion of the tuber coxae between the two ventral iliac spines, it inserts on the medial aspect of the cranial tibia, flexes the stifle, and imposes a caudal force on the tibia (26, 35, 36). The gracillis muscle is located medially, it originates from the pelvic symphysis, it inserts on the cranial tibial border, it flexes the stifle, and imposes a caudal force on the tibia (26, 35, 36).

The muscles of the distal limb that are associated with the stifle are the long digital extensor, the gastrocnemius, the superficial digital flexor and the popliteus muscles (26). The long digital extensor muscle is located cranially and laterally, it originates from the extensor fossa of the lateral femoral condyle, it passes through the extensor groove on the lateral tibial condyle, and inserts on the distal phalanges (35). It spans the stifle, but does not appear to play a

role in movement or stability of the stifle (26, 36). The gastrocnemius muscle is located caudally and divided into medial and lateral heads (35). The medial and lateral heads originate on the medial and lateral supracondylar tuberosities of the femur, respectively and their origins contain the medial and lateral fabella, respectively (35). The two heads fuse distally and insert on the calcanean tuberosity and compose one portion of the common calcanean tendon (26, 35). The gastrocnemius causes slight flexion of the stifle and during contraction imposes a caudodistal force on the femur (26, 36). The superficial digital flexor muscle is located caudally, originates on the femur at the lateral supracondylar tuberosity, it inserts on the calcanean tuberosity and the middle phalanges, and flexes the stifle (26, 35). The popliteus muscle originates on the distal surface of the lateral femoral condyle and its origin contains the popliteal sesamoid (35). Its tendon crosses under the lateral collateral ligament and causes an invagination of the joint capsule of the femorotibial joint (26, 35). It spans the caudal aspect of the stifle, courses through the popliteal notch of the tibia, and inserts on the medial border of the tibia proximally (35). It rotates the tibia medially, flexes the stifle, provides lateral stability to the stifle, and may also influence limb movement through receiving and transmitting proprioceptive information about the stifle (35).

4. Fascia

Fascia is a form of connective tissue that serves several purposes including separating and connecting muscles, forming aponeurosis for origin or insertion of muscles, stabilizing tendons, and providing passages for vascular structures and nerves (35). The fascia that is important to the stifle is broken down into superficial and deep fascia of the medial and lateral thigh, fascia of the stifle, and crural fascia (35). The superficial lateral fascia of the thigh originates from the superficial trunk fascia of the lateral abdominal wall, courses over the thigh to just proximal to the patella, surrounds the distal femur and unites with the deep lateral fascia of the thigh (35). The deep lateral fascia of the thigh also referred to as the fascia lata originates from the lumbodorsal fascia and is continuous with the gluteal fascia (35). The fascia lata extends from the tensor fascia lata muscle proximally, to the cranial and caudal contours of the thigh to connect with the deep medial fascia of the thigh medially, and to the patella and lateral femoral condyle distally (35). It also has a connection to the lateral lip of the femur, which is through an intermuscular septum that is located between the biceps femoris and vastus lateralis muscles (35). The superficial and deep medial fascia of the thigh connect with the superficial and deep medial fascia of the thigh medially and extend over the medial surface from the caudal aspect of the quadriceps to the cranial border of the semitendinosus caudally and to the patella and medial femoral condyle distally (35). The deep medial fascia of the thigh has a connection to the to the medial lip of the femur through a septum caudal to the vastus medialis muscle (35). The fascia of the stifle joint extends proximally from the patellar ligament and continues distally over the stifle and then becomes the crural fascia, which surrounds the distal limb (35).

5. Arterial Blood Supply

The arterial blood supply to the stifle largely originates from the external iliac artery, which is a lateral branch of the abdominal aorta (38, 39). There are two branches of this artery that are important to the blood supply of the stifle, the deep femoral artery and the femoral artery (38). The deep femoral artery originates from the caudomedial aspect of the external iliac artery

within the abdomen and after coursing caudodistally it exits the abdomen and gives off a branch referred to as the medial circumflex femoral artery (38). The medial circumflex femoral artery exits the caudomedial aspect of the deep femoral and supplies the vastus medialis muscle, and the nutrient artery of the femur (38). A caudal branch of the medial circumflex femoral artery, the obturator branch supplies the semimembranosus muscle (38). The other important branch of the external iliac artery, the femoral artery gives off several branches that are important to the blood supply of the stifle, which are the superficial circumflex iliac artery, the lateral circumflex femoral artery, muscular branches, the proximal caudal femoral artery, the middle caudal femoral artery, the saphenous artery, the descending genicular artery, the distal caudal femoral artery, and its distal continuation, the popliteal artery (38, 39). The superficial circumflex iliac artery exits from the craniodorsal aspect of the femoral artery and it supplies the tensor fascia lata, the rectus femoris, and the cranial sartorius muscles (38). The lateral circumflex femoral artery exits from the caudolateral aspect of the femoral artery and supplies the vastus lateralis, and tensor fascia lata muscles before dividing into an ascending and descending branch (38, 39). The ascending branch supplies the tensor fascia lata muscle and the descending branch supplies the rectus femoris, vastus medialis, vastus lateralis, vastus intermedius, and tensor fascia lata muscles (38). Muscular branches of the femoral artery may supply the biceps femoris, vastus lateralis, semimembranosus, semitendinosus, and caudal sartorius muscles (38). The proximal caudal femoral artery exits the caudal aspect of the femoral artery and supplies the vastus medialis muscle (38, 39). The middle caudal femoral artery exits the caudodistal aspect of the femoral artery and supplies the semimembranosus muscle (38, 39). The saphenous artery exits the medial aspect of the femoral artery and supplies the caudal sartorius and gracillis muscles (38, 39). A medial branch of the saphenous artery, the genicular branch supplies the medial skin and superficial fascia of the stifle (38). A cranial branch of the saphenous artery exits the saphenous artery and courses distocranially and supplies the cranial periosteum, fascia, and skin of the tibia (38, 39). The descending genicular artery is considered to be the predominant blood supply to the stifle, it originates from the femoral artery and courses distomedially to supply the vastus medialis muscle and medial femoropatellar and femorotibial joint capsule (38). The distal caudal femoral artery originates from the caudolateral aspect of the femoral artery and courses caudodistally to supply the biceps femoris, vastus lateralis, gastrocnemius, semimembranosus, and semitendinosus muscles and the lateral skin of the thigh (38, 39). The distal continuation of the femoral artery is referred to as the popliteal artery (38, 39). The popliteal artery gives off several branches that are important to the blood supply to the stifle, the caudal genicular arteries, muscular branches, the caudal tibial artery, and the cranial tibial artery (38). The medial and lateral caudal genicular arteries exit the popliteal artery caudally and supply the medial and lateral collateral ligaments of the stifle, respectively and the medial and lateral heads of the gastrocnemius muscle, respectively (38). Small genicular arteries originating from the popliteal artery also supply the cruciate ligaments of the stifle and the caudal aspect of the femorotibial joint capsule (38). Muscular branches from the popliteal artery supply the gastrocnemius muscle, the popliteus muscle, the medial and lateral collateral ligaments, and the proximal aspect of the tibiofibular joint capsule (38). The caudal tibial artery exits the popliteal artery caudally and supplies the tibia through the nutrient artery (38). The cranial tibial artery exits the popliteal artery distolaterally and supplies the long digital extensor muscle and lateral aspect of the femorotibial joint capsule (38).

6. Venous Drainage

The veins that are important to the stifle mostly consist of veins that course alongside the arteries of the pelvic limb (40). The cranial and caudal tibia vein are divisions of the popliteal vein (40). The cranial tibial vein originates on the cranial surface of the tibia, drains the cranioproximal aspect of the distal limb muscles, and courses caudoproximally to join the caudal tibial vein and form the popliteal vein (40). The popliteal vein continues proximally and proximal to the stifle it receives venous branches from the medial and lateral aspects of the stifle before becoming the femoral vein (40). The lateral saphenous vein drains the gastrocnemius muscle then continues as the distal caudal femoral vein before it enters the femoral vein (40). The middle caudal femoral vein drains the gastrocnemius, quadriceps, semimembranosus, semitendinosus, gracillis, and biceps femoris before joining the femoral vein (40). The descending genicular vein is the next vein to join the femoral vein and enters at the craniomedial aspect (40). Cranial and caudal divisions of the medial saphenous vein join to form the medial saphenous vein (40). The medial genicular vein then enters the medial saphenous vein craniomedially before it joins the femoral vein medially (40). The proximal caudal femoral is the next vein to join the femoral vein, followed by the lateral circumflex femoral vein, which drains the lateral thigh and skin, and then the superficial branch of the deep circumflex iliac vein, which drains the proximal thigh (40). The femoral vein then joins deep femoral vein before continuing proximally as the external iliac vein (40). The deep femoral vein drains the caudal thigh, semimembranosus, semitendinosus, and biceps femoris before it joins the external iliac vein (40). The external iliac then joins the common iliac proximally, which then enters the caudal vena cava (40).

7. Lymphatic Drainage

The lymphatics that are important to the stifle consist of the superficial medial and lateral systems and the deep medial system and the popliteal, femoral, and superficial inguinal lymph nodes (41). The superficial lateral system is closely associated with the lateral saphenous vein and it courses over the gastrocnemius muscle to pass into to the popliteal lymph node (41). The popliteal lymph node is located caudal to the stifle and drains the limb distal to the stifle (39, 41). The superficial medial lymphatics are located close to the skin in the distal limb, course over the gracillis and vastus medialis muscles and enter the superficial inguinal lymph node (41). The superficial inguinal lymph node is located between the abdominal wall and the medial aspect of the thigh, and drains the popliteal lymph node, stifle, distal limb, and medial thigh (39, 41). The iliac lymph nodes receive drainage from the superficial inguinal lymph node (41). The deep medial lymphatics course over the gastrocnemius muscle distally and the gracillis muscle proximally and enter into the iliac lymph nodes (41). The femoral lymph node is inconsistent and when present drains the distal limb, stifle and the popliteal lymph node (41).

8. Nerves

The nerves that are important to the stifle are the obturator nerve, cranial gluteal nerve, caudal gluteal nerve, lateral cutaneous femoral nerve, femoral nerve, and sciatic nerve (42, 43). The obturator nerve originates from lumbar nerves four, five and six (42). The main contribution to the obturator is from lumbar nerve six and lumbar nerve four contributes the least

and is occasionally not present (43). The obturator nerve arises in the iliopsoas muscle, then travels medially along the ilium, then through the obturator foramen and supplies the gracilis muscle (35, 42, 43). The cranial gluteal nerve originates from lumbar nerves six and seven as well as from sacral nerve one (43). It exits the pelvis through the greater sciatic foramen and enters the rump muscles, travels lateral to the ilium, continues cranially and ventrally through the gluteal muscles and then terminates and supplies the tensor fascia lata muscle (35, 42, 43). The caudal gluteal nerve originates from either the lumbosacral trunk or from lumbar nerve seven (43). It exits through the greater sciatic foramen, travels along the medial aspect of the ilium, continues through the gluteal muscles and supplies the cranial portion of the biceps femoris muscle and a small portion of the semimembranosus and semitendinosus muscles (35, 42, 43). The lateral cutaneous femoral nerve originates mainly from the ventral branch of lumbar nerve four, but also a lesser extent from lumbar nerves three and five (43). It courses caudally and laterally, passing through the abdominal wall, and supplies the skin over the thigh and the lateral aspect of the stifle (43). The femoral nerve originates mainly from lumbar nerve five, but also a lesser extent from lumbar nerves four and six (42, 43). It arises in the iliopsoas muscle, courses caudally, exits the abdominal wall, gives off its large saphenous branch, and enters the quadriceps muscles to supply the rectus femoris muscle, vastus medialis muscle, vastus lateralis muscle, vastus intermedius muscle, and the muscularis articularis genus (35, 42, 43). The saphenous branch of the femoral nerve courses medially to the tensor fascia lata muscle before dividing into a muscular and cutaneous branch (43). The muscular branch of the saphenous nerve divides with one branch supplying the cranial belly of the sartorius and one branch supplying the caudal belly of the sartorius (42, 43). The cutaneous branch of the saphenous nerve courses distally along the medial aspect of the quadriceps muscles and supplies the medial skin of the thigh, the deep structures of the medial stifle, and the medial skin of the stifle (43). The sciatic nerve originates from lumbar nerves six and seven as well as sacral nerve one (43). The sciatic nerve enters the gluteal muscles, then courses along the caudal aspect of the coxofemoral joint, and travels medial to the biceps femoris muscle and lateral to the semitendinosus muscle, and gives off a muscular branch that supplies the biceps femoris muscle, caudal crural abductor muscle, semitendinosus muscle and semimembranosus muscle (42, 43). After giving off a muscular branch the sciatic nerve divides into the peroneal and tibial nerves (42, 43). The peroneal nerve arises at the distal aspect of the biceps femoris muscle, crosses the lateral head of the gastrocnemius muscle, courses distally along the caudal and lateral aspect of the stifle, supplies articular branch to the lateral collateral ligament and supplies a superficial branch to the long digital extensor muscle (35, 42, 43). The tibial nerve arises at the distal aspect of the biceps femoris muscle, supplies the biceps femoris muscle, semitendinosus muscle, semimembranosus muscle, courses between the medial and lateral head of the gastrocnemius muscle, and supplies the gastrocnemius muscle, superficial digital flexor muscle and popliteus muscle (35, 42, 43).

9. Joint Capsule

The stifle is a synovial joint with a joint capsule that is composed of synovial membrane on the inside of the joint and a fibrous membrane on the outside of the joint (20). The synovial membrane is composed of connective tissue that is highly vascular and synoviocytes, which produce synovial fluid (20, 25). With the exception of the articular cartilage and the meniscus, all structures contained in the joint are covered by the synovial membrane (20). As the synovial

membrane attaches to the bones of the stifle it integrates into the periosteum (25). The synovial membrane surrounds ligaments inside the joint, tendons in close proximity to the joint, and can extend beyond the outer fibrous membrane and form bursa beneath tendons and ligaments (20, 25). The outer fibrous membrane of the joint capsule is composed of fibrous and elastic tissue, attaches at or close to the articular cartilage margin, and integrates into the periosteum (20).

The joint capsule of the stifle is divided into three intercommunicating sacs (20). These sacs consist of the medial and lateral sacs that are formed by the articulation of the medial and lateral femoral and tibial condyles and the patellar sac formed by the articulation of the femur and the patella (20, 22, 26). The medial and lateral sacs are divided in part into femoromeniscal and tibiomensical components by the menisci (20, 22). The only communication that exists between the femoromeniscal and tibial components is along the axial borders of the menisci due to the firm attachment of the outer fibrous membrane of the joint capsule along the abaxial borders of the menisci (20). The medial and lateral sacs communicate freely transversely and extend to the caudal and proximal extent of the femoral condyles and their respective fabellae (20, 22). The medial sac has one subpouch between the medial femoral condyle and the medial fabella (20, 26). The lateral sac has four subpouches one between the lateral femoral condyle and lateral fabella, one between the lateral tibial condyle and the fibular head, one in the extensor groove of the tibia where the synovial membrane surrounds the long digital extensor tendon, and one on the lateral femoral epicondyle where the synovial membrane partially surrounds the popliteus tendon (20). The patellar sac is attached to and continues beyond both medial and lateral parapatellar fibrocartilages to just slightly past the trochlear ridges of the femur toward the medial and lateral epicondyles of the femur (20, 26). It contains a small subpouch under the quadriceps tendon and is separated between its inner synovial and outer fibrous layer distal to the patella by the infrapatellar fat pad (20).

10. Synovial Fluid

Synovial fluid is composed of a dialysate of blood and glycosaminoglycans produced by synoviocytes, which are fibroblasts contained in the synovial membrane of the joint capsule (20, 25). The main glycosaminoglycan in the synovial fluid is hyaluronic acid, which serves to protect the synovial fluid from entrance of high molecular weight proteins (25). The synovial fluid contacts all surfaces within the joint and serves to lubricate the joint, provide nutrition to the articular cartilage of the joint, and provides leukocytes for phagocytosis of debris within the joint (20).

11. Articular cartilage

The articular surfaces of the bones of the stifle are lined with articular cartilage (20). This cartilage is usually composed of hyaline cartilage which is avascular, contains no nerve endings, and receives most of its nutrients from the synovial fluid (20, 25). Hyaline cartilage consists of chondrocytes, collagen fibers, and matrix (25). Articular cartilage is composed of a surface membrane, a surface or tangential layer, an intermediate or transitional layer, a deep or radial layer, and a calcified layer, which are distinguished based on the shape of the chondrocytes and orientation of the collagen fibers (25). The articular cartilage possesses both

elastic and compressible physical properties that allow it absorb shock, protecting the bones of the stifle from fracture (20).

12. *Meniscus*

The stifle contains two fibrocartilaginous structures, the medial and lateral menisci that are located between the medial and lateral femoral and tibial condyles, respectively (20, 44). The distal portion of the menisci in contact with the condyles of the tibia is flat, while the proximal portion in contact with the condyles of the femur is concave (22). The menisci are semilunar shaped discs and are convex and thick along their abaxial border and concave and thin along their axial border (20). These structures are wedge shaped in cross section, with the lateral meniscus being thicker, more concave, and forming a greater arc than the medial meniscus (20, 44). The thick abaxial border of the meniscus is attached to the to the inner surface of the joint capsule, while the thin axial border remains unattached or free (22). The medial meniscus is also attached to the medial collateral ligament, the lateral meniscus is attached to the medial femoral condyle, and both menisci are attached to each other through ligaments (20, 22, 44).

The fibrocartilaginous menisci are composed of water, chondrocytes, collagen, elastin, proteoglycans, and matrix glycoproteins (22, 44). Water is the primary component of the canine meniscus comprising 60-70% of its weight (44-46). The water content of the central portion of the medial meniscus is significantly less than the water content of the central portion of the lateral meniscus (46). Chondrocytes are found interposed in the network of collagen fibers in the menisci (22, 47). Collagen composes 15-20% of the weight of the meniscus and 60-70% of its dry weight (44). The collagen fibers in the menisci are a type I and type II collagen, with type I collagen making up 90% of the collagen content (44, 47). The surface of the menisci that articulates with the femoral condyles has collagen fibrils that are arranged randomly, similar to a mesh and functions to counteract shear stresses and allow motion with minimal friction (22, 44). In the outer two thirds of the menisci below the surface collagen fibrils are oriented circumferentially, which may function to counteract tensile forces (22, 44). The inner third of the menisci has collagen fibrils oriented radially, which may function to counteract compressive forces (22). Additionally radial fibers, called tie fibers, can be present throughout the menisci, connect circumferential fibers and may function to counteract longitudinal splitting (22, 44, 47). Small amounts of elastin are also present in the menisci and contribute a portion of the remaining dry weight of the menisci not composed of collagen (44). Proteoglycans also contribute a portion of the remaining dry weight of the menisci not composed of collagen and are molecules that function to control solute concentration in the menisci, counteract compressive forces, and maintain tissue health (22, 45). The last component of the remaining dry weight of the meniscus not composed of collagen are the matrix glycoproteins (22, 44).

The blood supply to the menisci is derived mainly from the medial and lateral genicular arteries (48). These arteries give off branches that form a capillary plexus within the synovial and fibrous membranes of the joint capsule around the meniscus (44, 48). This capillary plexus supplies the peripheral 15-25 % of the menisci where they are attached to the joint capsule and this is referred to as the red zone of the menisci (22, 44, 48). The portion of the lateral meniscus with no capsular attachment, located caudally and laterally near the popliteal tendon is not supplied by these vessels (48). Cranially and caudally a vascular synovial tissue which is

continuous with the synovial tissue around the cruciate ligaments supplies the meniscal ligamentous attachments and these vessels also penetrate the menisci for a short distance (44, 48). The remaining relatively avascular areas of the meniscus are divided into an intermediate zone and axial zone, referred to as the red-white zone and the white zone respectively (22, 44). The names of the different zones of the menisci indicate the healing potential of that area and the healing potential decreasing from the red to the white zone (22, 44, 48).

The innervation of the mensici occurs around the peripheral margin and provides sensation (44). Mechanoreceptors are also present in the cranial and caudal poles of the menisci, which allow pressure to be detected and may also allow exchange of proprioceptive information (44). The menisci also communicate with myotactic receptors, which allow a muscular response to be generated when certain stresses are generated within the joint (44).

The menisci have several proposed functions, which include distributing load, stabilizing the joint, absorbing shock, providing lubrication, and providing sensory information (22, 44). When a load is placed across the stifle, the menisci and femoral condyles come into contact with one another and the load is distributed across the menisci, which decreases the stress transmitted to the femoral and tibial condyles and reduces mechanical damage to those structures (22). As the menisci are loaded they also elongate, which allows them to absorb energy (22, 44). The menisci act to fill in the incongruencies between the femoral and tibial condyles, making the stifle more congruent and increasing its stability (22, 44). The sensory information provided by the menisci can help elicit an appropriate response to prevent injury (44). The menisci are thought also to provide lubrication to the stifle and this decreases the amount of friction that occurs during stifle motion (44).

13. Ligaments

The ligaments of the stifle consist of the meniscal ligaments, patellar ligament, femoropatellar ligaments, fabellar ligaments, ligaments of the fibular head, collateral ligaments and cruciate ligaments (20). The meniscal ligaments can be further divided into the coronary ligament, cranial and caudal meniscotibial ligaments, the meniscofemoral ligament and the intermeniscal ligament (20, 22, 44). The medial meniscus is attached through the coronary ligament to the medial collateral ligament and the medial aspect of the joint capsule (22). The medial meniscus is attached to the tibia cranially through the cranial tibial ligament of the medial meniscus, which connects the axial portion of the cranial medial meniscus to the cranial tibial intercondyloid area (20). The medial meniscus is also attached to the tibia caudally through the caudal tibial ligament of the medial meniscus, which is thin and fan-shaped and extends from the axial portion of the caudal medial meniscus to the caudal intercondyloid area (20, 22). The lateral meniscus is attached to the tibia through the cranial tibial ligament of the lateral meniscus, which connects the axial portion of the cranial lateral meniscus to the cranial tibial intercondyloid area caudal to where the cranial tibial ligament of the medial meniscus is located (20). The lateral meniscus is also attached to the tibia caudally through the caudal tibial ligament of the lateral meniscus, which can be small and multiple or even absent and extends from the axial portion of the caudal lateral meniscus to the tibial popliteal notch, caudal to the attachment of the caudal tibial ligament of the medial meniscus (20, 22). The meniscofemoral ligament connects the axial portion of the caudal lateral meniscus to the medial condyle of the

femur near the intercondyloid fossa and represents the only connection of the menisci to the femur (20). The intermeniscal ligament also referred to as the transverse ligament connects the cranial tibial ligament of the medial meniscus caudally to the cranial tibial ligament of the lateral meniscus cranially and is located just cranial to the insertion of the cranial cruciate ligament on the tibia (20, 44).

The patella is as previously discussed a sesamoid bone located in the tendon of the quadriceps muscle group (28). In addition to its tendinous attachment proximally it has ligamentous attachments to the stifle both medially and laterally and also distally (20). These are the medial femoropatellar ligament, the lateral femoropatellar ligament, and patellar ligament, respectively (20, 26). The medial femoropatellar ligament extends from the medial aspect of the patella to the medial femoral epicondyle and is weaker than the lateral femoropatellar ligament (20). The lateral femoropatellar ligament extends from the lateral aspect of the patella to the lateral fabella (20). Both of these ligaments are composed of collagen fibers that form slender bands that converge with the fascia of the femur and serve to hold the patella in the trochlea of the femur (20, 26). The patellar ligament originates from the distal aspect of the patella to insert on the tibial tuberosity (20).

The medial and lateral fabellofemoral ligaments are not true ligaments, but are actually portions of tendons (22). The structure referred to as the medial fabellofemoral ligament is the tendon of the origin of the medial head of the gastrocnemius muscle (35). The structure referred to as the lateral fabellofemoral ligament is the tendon of the origin of the lateral head of the gastrocnemius muscle (22, 35). Both of these tendons provide an attachment for their respective fabellae to the respective supracondylar tuberosities of the femur (35).

Two ligaments, the cranial and caudal ligaments of the head of the fibula are present in the tibiofibular joint (26). The cranial ligament of the head of the fibula originates from the lateral tibial condyle to the head of the fibula (20). The caudal ligament of the head of the fibula originates from the caudal aspect of the tibia to the head of the fibula (20).

Ligaments that serve the function of providing stability to the stifle are the medial collateral ligament, the lateral collateral ligament, the cranial cruciate ligament and the caudal cruciate ligament (26). The medial collateral ligament originates proximally from an oval area on the medial femoral epicondyle, attaches firmly to the medial aspect of the joint capsule as well as the medial meniscus, then inserts on a long rectangular area distal to the medial condyle of the tibia (20, 26, 49). A bursa is located between the medial collateral ligament and the tibia and is fluid filled (49). The lateral collateral ligament originates just proximal to the origin of the popliteus muscle on an oval area of the lateral femoral epicondyle, connects to the joint capsule through loose connective tissue, and then inserts on the head of the fibula (26, 49). A few fibers of the distal aspect of the lateral collateral ligament also insert on the lateral tibial condyle (20). A superficial portion of the lateral collateral ligament also exists (49). This portion originates in the area of the lateral fabellofemoral ligament, extends along the caudal border of the main portion of the ligament and then inserts diffusely on the peroneus longus fascia (26, 49). The collateral ligaments are the primary stabilizers of the stifle against varus or valgus forces (49, 50). The medial collateral ligament is the primary stabilizer against valgus forces and the lateral collateral ligament is the primary stabilizer against varus forces (50). In flexion the lateral

collateral ligament becomes less taut due to the origin and insertion of the ligament moving closer together (26, 49). This causes the lateral femoral condyle to be displaced caudally and the tibia to internally rotate (49). The medial collateral ligament counteracts a moderate amount of internal rotation during extension, slight amount of external rotation in extension, moderate amount of external rotation in flexion, and slight amount of valgus angulation in both extension and flexion (49). The lateral collateral ligament counteracts a moderate amount of internal rotation during extension, moderate amount of external rotation in extension, slight amount of external rotation in flexion, and slight amount of varus in both extension and flexion (49).

The cranial and caudal cruciate ligaments are intraarticular and covered by synovial membrane of the joint capsule and cross one another (20). The cranial cruciate ligament originates in a fossa present caudally on the medial aspect of the lateral condyle of the femur (9, 20). Some of the fibers of the cranial and proximal portion of the ligament also originate in the caudal lateral aspect of the intercondylar fossa of the femur (9). As the cranial cruciate ligament continues distally through the intercondylar fossa of the femur it courses cranially and medially (51). The cranial cruciate ligament then inserts on the cranial intercondylar area of the tibia and its insertion is broad and fan-shaped (9, 26, 51). Some of the fibers of the insertion of the cranial cruciate ligament also attach to the cranial and lateral aspect of the medial tubercle of the intercondylar eminence of the tibia (9). The caudal cruciate ligament originates from a fossa on the ventral and lateral aspect of the medial condyle of the femur in the most cranial aspect of the intercondylar notch of the femur (20, 26, 52). The caudal cruciate ligament continues distally through the intercondylar notch and courses caudally (9, 26). The insertion of the caudal cruciate ligament is medial to the popliteal notch of the tibia (9).

The cranial cruciate ligament is morphologically made up of two components (51). One portion is the craniomedial band which is spiral, originates more proximally in the intercondylar notch and is taut in both extension and flexion (9, 51). The other portion is the caudolateral band which is straight and is taut in extension, but not in flexion (9, 51).

The cruciate ligaments are mostly composed of multiple fascicles of collagen that are in large part oriented parallel to one another (51, 52). The individual collagen fibers have a crimped appearance and the predominant type of collagen is type I, although some type III collagen is also present (44). Interposed between the collagen fascicles in loose connective tissue are fibroblasts that run parallel to these fascicles and are usually spindle or oval in shape (51). The synovial membrane component of the joint capsule that covers the cruciate ligaments is composed of thick connective tissue and fibroblasts (51, 52).

The vascular supply to the cruciate ligaments is derived mainly from periligamentous soft tissues, in particular the synovial membrane portion of the joint capsule that surrounds the ligaments (9, 53). The blood supply to this synovial membrane comes mainly from the middle genicular artery, but also from the lateral genicular artery and the descending genicular artery (26, 38, 52, 53). The vessels in the synovial membrane that surround the cruciate ligaments, enter the ligaments transversely, and join to vessels within the ligamentous tissue (52, 53). The density of vessels seems to be decreased in the midportion of the ligament when compared to the proximal and distal aspects of the ligament (53). The vessels that supply the bones of the femur

and tibia have a few connections to the vessels in the cruciate ligaments, however these vessels are not thought to contribute to the blood supply of the ligaments (52, 53).

Innervation of the cruciate ligaments has been evidenced by the presence of mechanoreceptors in the ligaments (54, 55). These receptors are most prevalent in the proximal aspect of the cruciate ligaments (55). The presence of these mechanoreceptors indicates that the cruciate ligaments have a role in proprioception (54).

The cranial cruciate ligament serves to limit cranial motion of the tibia relative to the femur (9, 51, 56). The craniomedial portion of the ligament limits this motion in both extension and flexion and functions as the primary restraint (9, 51). The caudolateral portion of the ligament limits cranial motion of the tibia relative to the femur in extension only and therefore functions as the secondary restraint (9). Another function of the cranial cruciate ligament is to limit internal rotation of the tibia relative to the femur (9, 56). The cranial cruciate ligament also functions to limit hyperextension of the stifle and is the primary restraint against this motion. (9). The caudal cruciate ligament serves to limit caudal motion of the tibia relative to the femur (9, 56). Along with the cranial cruciate ligament, the caudal cruciate ligament functions in the same capacity to limit internal rotation of the tibia relative to the femur (9, 56). The caudal cruciate ligament also functions to limit hyperextension of the stifle, but is the secondary restraint against this motion (9).

B. Kinematics of the Normal and Cranial Cruciate Ligament Deficient Stifle

The term kinematics refers to the study of movement and is used to describe motion of individual joints as well as motion of the entire animal (57, 58). Kinematics is often used to assess joint function and gait patterns (57). In addition to the stability provided by the ligaments of the stifle, bone congruity and muscular contractions also aid in stability and together all of these things influence the resultant function of the joint and the gait pattern of the hindlimb (27).

The motion of the stifle consists mainly of extension and flexion of the joint along the axis of the body (22). Motion of the stifle, however can occur to a lesser degree in other planes, resulting in 6 degrees of freedom of the stifle (27, 59-61). The six degrees of freedom consist of three translations and three rotations of the tibia relative to the femur (59-61). The translations consist of cranial-caudal, proximal-distal (compression-distraction), and medial-lateral movement of the tibia relative to the femur (27, 59, 60). The rotations consist of extension-flexion of the stifle, internal-external rotation of the tibia relative to femur, and varus-valgus (adduction-abduction) movement of the stifle (27, 59, 61). Evaluation of all of the six degrees of freedom together provides three-dimensional information regarding the motion of the stifle (59).

Assessments of these different movements can be measured in the passive state, which means that influences of muscular contractions, bone congruity during weight bearing are not present (27). Measurements of the primary movements that the cranial cruciate ligament counteracts, such as cranial displacement of the tibia relative to the femur, internal rotation of the tibia relative to the femur, and hyperextension of the stifle can be made in the passive state (9). These measurements can be compared to reference values in animals free of evidence of orthopedic disease of the hindlimb for evaluation of cranial cruciate ligament abnormalities (9,

27). In one study, Arnoczky found that both cranial and caudal movement of the tibia relative to the femur was 0 mm when measured directly in cadaveric specimens free of orthopedic disease of the stifle (9). Cranial movement of the tibia relative to the femur in the passive state at all stifle angles examined was less than 1 mm in another study conducted by Korvick using instrumented spatial linkage and radiophotogrammetry in anesthetized dogs free of orthopedic disease of the stifle (27). In Arnoczky's study, internal rotation was 6° in extension and 19° in 90° of flexion and external rotation was 5° in extension and 8° in 90° of flexion (9). Passive maximum extension and flexion of the stifle, as obtained by Jaegger using goniometry from a reference population of sedated dogs free of orthopedic disease of the stifle, was estimated to be 162° and 42°, respectively, resulting in 121° of motion (62). After transection of the cranial cruciate ligament, cranial movement of the tibia relative to the femur was 2 mm in extension and 9.5 mm at 90° of flexion when measured directly in Arnoczky's study (9). Cranial movement of the tibia relative to the femur after transection of the cranial cruciate ligament in the passive state at all stifle angles examined was 10 mm as demonstrated by Korvick's study (27). After transection of the cranial cruciate ligament in Arnoczky's study internal rotation was 15° in extension and 45° in 90° of flexion and external rotation was unchanged (9). In this same study, extension of the stifle increased by 8 % after transection of the cranial cruciate ligament (9). Although this information may be helpful in identifying and underlying ligamentous abnormality in the stifle (9, 49), it is not useful in determining the ultimate function of the joint in an animal with a ligamentous injury such as a cranial cruciate ligament rupture (27).

Muscular contractions and bone congruity during weightbearing may allow an animal to compensate for or may cause exacerbation of an abnormality in the stifle (27, 32, 36). Muscular contractions from the quadriceps group of muscles exerts a cranial and proximal force on the tibia and contractions of the gastrocnemius muscle exert a caudal and distal force on the femur (36). The resultant forces of the quadriceps and gastrocnemius muscles act to antagonize the forces of the cranial cruciate ligament (36, 63). The biceps femoris, gracillis, semimembranosus, and semitendinosus muscles, as well as the caudal belly of the sartorius exert a caudal force on the tibia, therefore these muscle act as agonists to the forces of the cranial cruciate ligament (36, 63). Weight bearing causes compression of the tibia between the femur and the bones of the tarsus (36). The tibial plateau is the articular surface of the proximal tibia and has an angle of inclination that is directed from cranial and proximal to caudal and distal (28, 32). When weight bearing occurs, a force is generated in the direction of the long axis of the tibia causing a shear force across the tibial plateau and cranial displacement of the tibia (32). Measurements made during movement are more likely to be clinically relevant and provide important information about the effects of cranial cruciate rupture (27).

Movement can be assessed during ambulation by the use of computer assisted kinematic evaluation, which involves the use of reference markers placed on specific landmarks of the limb being assessed and a video camera that records the movement of the limb (7, 57, 58, 64). This information is collected and analyzed through a computer, which provides information about joint movement (58). This information can also be integrated with force-plate data (7, 57, 58, 64), which adds information about weight distribution, speed of movement, and force applied on that limb (7, 65).

The characteristics of the hindlimb gait at both a walk and a trot were studied in a reference population of animals free of evidence of orthopedic disease (57, 58). The stride of each limb is divided into two phases: a stance phase in which the foot contacts the ground and a swing phase in which the limb is elevated off the ground (66). At a walk the hip and tarsus are extended and the stifle is flexed during the stance phase and all of the joints flex then extend during the swing phase (58). At a trot the hip and tarsus have a significant peak of extension and the stifle has a lesser peak of extension during stance and the stifle and tarsus have a significant peak of extension and the hip has a slowed extension in the swing phase preceding the stance phase (57). The range of motion at a walk was 100°-140° in the hip, 150°-110° in the stifle, and 125°-170° in the tarsus during stance phase and 130° to 95° in the hip, 100°-150° in the stifle, and 120°-160° in the tarsus during swing phase (58). At a trot the mean joint angle was 123° for the hip, 135° for the stifle, and 144° for the tarsus during stance and 104° for the hip, 129° for the stifle, and 137° in the swing phase preceding the stance phase (57). The walk involves more complex movement, more consistency, and longer stance phase than the trot (58).

There are several studies that have used computer assisted kinematic and force plate data to compare the gait of animals with no evidence of orthopedic disease to those with cranial cruciate ligament rupture (7, 64, 65). In one study Bustinduy found with both computer assisted kinematic and force plate data that at a walk the length of a dog's stride as well as a dog's paw velocity were significantly less in dogs with cranial cruciate ligament rupture (7). In another study using computer assisted kinematic and force plate, DeCamp found that during the stance phase of a trot gait dogs had increased flexion of the stifle and increased extension of the hip and tarsus (64). In a study using force plate data, Budsberg found that at a walk the measured values peak force, impulse, weight distribution were significantly less in dogs with cranial cruciate rupture limb (65). All of these findings were indications that the dogs were avoiding loading on the limb with the cranial cruciate ligament rupture, but do not give information about how the dynamics between the tibia and femur are changing (7, 64, 65).

Assessment of six degrees of freedom can be performed during ambulation (22, 27, 60). In a reference population of animals free of evidence of orthopedic disease 6 degrees of freedom were measured using radiophotogrammetry in previous studies (22, 27, 60). This involves implantation of radiographically detectable markers in the femur and tibia, detection by a radiographic unit and transfer of information to a computer which creates a coordinate system for three-dimensional analysis of motion between the femur and tibia (27, 60). In one of the studies Korvick studied and approximated the 6 degrees of freedom in the stance and swing phase of a trot gait (22, 27). In the stance phase cranial displacement of the tibia relative to the femur was 2 mm, proximal displacement of the tibia relative to the femur (compression) was 2 mm, medial-lateral displacement of the tibia relative to the femur was not present, the stifle was flexed to 125°, external rotation was less than 1°, and abduction (valgus) of the stifle was less than 1° (27). In this same study in the swing phase cranial-caudal displacement of the tibia relative to the femur was 2 mm cranially and 5 mm caudally, proximal-distal displacement of the tibia relative to the femur (compression-distraction) was 4 mm proximally and 2 mm distally, medial-lateral displacement of the tibia relative to the femur was 2 mm medially, the stifle was flexed to 80°, internal-external rotation of the stifle was 10° of internal rotation and 5° of external rotation, and abduction (valgus) was 8 mm (27). In the other study Tashman studied and approximated the 6 degrees of freedom during the stance phase of trot gait (22, 60). Over the course of stance phase

caudal displacement of the tibia relative to the femur was less than 1 mm, distal displacement relative to the femur was 2 mm, medial displacement was less than 1mm, flexion of the stifle was 120°, external rotation was 2°, and abduction (valgus) was 5° (60). Results from these two studies are similar and provide information about dogs without evidence of orthopedic disease, which is useful as a reference for dogs with as suspected cranial cruciate ligament rupture (27, 60).

Assessment of six degrees of freedom in a population of animals that had the cranial cruciate ligament surgically transected was also performed using radiophotogrammetry in previous studies (22, 27, 60). In the Korvick's study 6 degrees of freedom was approximated in the stance and swing phase of gait (22, 27). In the stance phase cranial displacement of the tibia relative to the femur was 14 mm, proximal displacement of the tibia relative to the femur (compression) was 10 mm, medial displacement of the tibia relative to the femur was 5mm, the stifle was flexed to 120°, internal rotation was 8°, and abduction (valgus) of the stifle was 5° (27). In this same study in the swing phase cranial-caudal displacement of the tibia relative to the femur was 6 mm cranially and 2 mm caudally, proximal displacement of the tibia relative to the femur (compression) was 4 mm, medial displacement of the tibia relative to the femur was 5 mm medially, the stifle was flexed to 75°, internal-external rotation of the stifle was 8° of internal rotation and 5° of external rotation, and abduction (valgus) was 8 mm (27). In the Tashman's study the 6 degrees of freedom were approximated during the stance phase of gait two months and two years after surgical transection (22, 60). Over the course of stance phase caudal displacement of the tibia relative to the femur was 2 mm at 2 months and 5 mm at 2 years, proximal displacement relative to the femur was 5 mm at 2 months and 4 mm at 2 years, medial displacement was 1 mm at 2 months and 2 mm at 2 years, flexion of the stifle was 115° at 2 months and 120° at 2 years, internal rotation was 3° at 2 months and 5° at 2 years, and abduction (valgus) was 7° at 2 months 5° at 2 years (60). Cranial, proximal, and medial displacement of the tibia relative to the femur as well as flexion, internal rotation, and abduction of the stifle increased after transection of the cranial cruciate ligament, but the changes in the swing phase were minimal due to the lack of muscular forces and influence of bone congruity (27, 60). Cranial displacement of the tibia relative to the femur occurred because these are the forces this ligament antagonizes (9). Proximal displacement of the tibia relative to the femur (compression) is due to collapse of the joint, because as the tibia moves cranially it also moves proximally (27). The reason for the increase in medial displacement of the tibia relative to the femur is poorly understood as is the increase in abduction (valgus) (60). The increase in flexion was likely a result of the animal decreasing weight-bearing on the limb (27). These assessments are useful for learning more about the progression of the disease and directing treatment (61).

C. Pathophysiology of Cranial Cruciate Ligament Disease

1. General

The pathophysiology behind cranial cruciate ligament rupture is not well understood and is the topic of intense investigation (2). It is not believed to result from a single abnormality, but is thought to be the result of several potential factors (3, 4, 6). Some of these proposed factors include trauma, genetics, conformation, blood supply, and degenerative changes (2, 3, 6, 67).

a. Trauma

Traumatic injury to the cranial cruciate ligament does occur, but is thought to be an uncommon cause of rupture (22, 44, 56, 68). The mechanism behind traumatic injury is thought to be excessive internal rotation of the tibia relative to the femur when the stifle is in flexion (56). During the period of excessive internal rotation the cranial cruciate ligament rotates tightly around its own axis and is subjected to compression by the lateral condyle of the femur, both potentially predisposing it to injury during trauma (9, 56, 68). Extreme hyperextension of the stifle can also cause injury to the cranial cruciate ligament (56). When traumatic injuries do occur they are usually associated with other ligamentous injuries, tears in the joint capsule, and damage to the menisci, resulting in subluxation or even luxation of the stifle (22, 44, 68). Less commonly single ligament injuries occur, but are usually avulsion injuries in young animals occurring at the level of the tibial attachment and is more likely to result from a hyperextension force (22, 44, 56). Avulsion injuries occur because the bone in these young dogs is not as strong as the attachment of the ligament to the bone (22). Most cranial cruciate ligament ruptures are not associated with trauma, however, which has led to numerous proposed causes for rupture (6, 68).

b. Genetics

A genetic basis for cranial cruciate ligament rupture is suspected, because this disease tends to occur more commonly in specific breeds of dogs (6). An increased frequency of larger breed dogs was noted in several studies (69-71). In one study Whitehair found that cranial cruciate ligament rupture was more prevalent in Rottweilers (7.85%), Newfoundlands (6.58%), and Staffordshire Terriers (5.39%) and less prevalent in Dachshunds (0.14%), Basset Hounds (0.18%), and Old English Sheepdogs (0.23%) (69). In another study Duval found an increased odds ratio for the Neapolitan Mastiff (15.33), Akita (11.69), Saint Bernard (9.84), Rottweiler (6.92), Mastiff (6.72), Newfoundland (6.56), Chesapeake Bay Retriever (5.11), Labrador Retriever (5.05), and American Staffordshire Terrier (3.46) and decreased odds ratio for the German Shepherd (0.11) and mixed breed dog (0.25) (70). Evaluation of one of the predisposed breeds the Newfoundlands, was subsequently performed to determine if a genetic basis exists (72, 73). In Newfoundlands, the prevalence of cranial cruciate ligament rupture was found to be 22%, the heritability was moderate (0.27), and a recessive mode of inheritance with a 51% penetrance was predicted (72). In addition, three microsatellite markers on three canine chromosomes (3, 5, and 13) identified by genotyping were found to be significantly associated with cranial cruciate ligament rupture in Newfoundlands (73). It is uncertain, however based on the current body of literature regarding genetics and cranial cruciate ligament rupture, whether genetics influence the actual composition of the cranial cruciate ligament or if they influence an animal's conformation, which subsequently predisposes the animal to cranial cruciate rupture (6).

c. Conformation

Conformational abnormalities are a suggested cause of cranial cruciate rupture, because they may lead to abnormal stress on the cranial cruciate ligament (68, 70, 74-86). The stance of

an animal is one conformational abnormality that is suggested to be associated with cranial cruciate rupture (68, 70, 74). An animal that stands with its hindlimbs straight or hyperextended is thought to place more stress on the ligament (68, 74). In addition, in hyperextension the midportion of the cranial cruciate ligament, which is the most common site for rupture, contacts the narrowest portion of the intercondylar notch, which is the cranial aspect, potentially causing impingement (31, 68, 87). Hyperextension of the hindlimbs is not consistently present in dogs with cranial cruciate rupture, however (6).

Deviations in alignment of the femur are another potential conformational abnormality associated with cranial cruciate rupture (6, 75). It was noted that in dogs with cranial cruciate ligament rupture and those predisposed to cranial cruciate ligament rupture, distal internal torsion of the femur was present (75). Internal torsion of the femur could result in increased torsional stress on the cranial cruciate ligament and could increase the contact between the cranial cruciate ligament and femur leading to impingement of the cranial cruciate ligament. (6, 75). The true relationship between internal torsion of the femur and cranial cruciate rupture and the true prevalence of internal torsion of the femur is unknown (75).

A decreased size of the femoral intercondylar notch is another conformational abnormality suggested to cause impingement of the cranial cruciate ligament, resulting in remodeling and potentially weakening of the ligament (76). In dogs with no evidence of orthopedic disease of the stifle, the cranial cruciate ligament contacts the intercondylar notch starting at 115° and the contact increases with increasing extension (31). Studies have verified the presence of a narrowed femoral intercondylar notch in both dogs with cranial cruciate ligament rupture and dogs predisposed to cranial cruciate ligament rupture (76, 77). Remodeling of the collagen of the cranial cruciate ligament in the narrowed area of the femoral intercondylar notch was also demonstrated (76). However, the area of the cranial cruciate ligament remodeling is also the area predisposed to rupture and therefore it is unknown if the narrowing of the femoral intercondylar notch is a secondary change caused by degenerative joint disease (75-77).

The angle of the articular surface of the tibia is yet another suggested conformational abnormality speculated to be associated with cranial cruciate ligament rupture (74, 75, 78, 82, 83). The angle of the articular surface can be influenced by angulation of the proximal aspect of the tibial shaft (75, 78) or by the angulation of the articular surface itself, the tibial plateau (32). A compressive force is generated between the femur and the tibia during weight bearing and sloping of the articular surface causes this force to be converted to a shear force, allowing the tibia to move cranially relative to the femur (32, 36). Increased angulation of the proximal tibia was seen in a study by Osmond and a study by Mostafa in dogs with cranial cruciate rupture when compared to dogs with no evidence of orthopedic disease of the stifle (75, 78). The reason for this abnormality is thought to be due to failure of normal growth of the caudal portion of the tibia due to premature closure of that portion of the tibial physis (75). Increased angulation of the tibial plateau was also demonstrated in two previous studies as well as in a study by Morris in dogs with cranial cruciate ligament rupture when compared to dogs with no evidence of orthopedic disease of the stifle (75, 78, 82). Wilke found, however that the tibial plateau angle was higher in animals predisposed to cranial cruciate ligament rupture, than those where a rupture was present (84). Also, in another study Buote found no association between tibial

plateau angle and cranial cruciate ligament rupture and a study by Inauen had similar findings (86, 88).

The orientation of the patellar ligament has also been implicated as a potential conformational abnormality associated with the development of cranial cruciate disease (79, 85, 86). The patellar ligament pulls the tibia cranially or caudally depending on what its angle is relative to the joint surface (89, 90). A patellar ligament that is greater than 90° to the joint surface will cause a cranial pull on the tibia and a shear force on the cranial cruciate ligament, which may allow damage to and eventually rupture of the cranial cruciate ligament (85, 90). It was demonstrated by Schwandt in one study and by Inauen in another study that dogs with cranial cruciate ligament rupture had a larger angle between the patellar ligament and joint surface than dogs with no evidence of orthopedic disease of the stifle (85, 86). The increase in this angle was thought to be the result of a significant decrease in tibial tuberosity width in the dogs with cranial cruciate ligament rupture in Inauen's study (86). In another study, Guerrero found significantly decreased development of the tibial tuberosity in dogs with cranial cruciate ligament rupture when compared to dogs with no evidence of orthopedic disease of the stifle (79). In another study by Mostafa, however did not find a significant difference in patellar ligament angles between dogs with cranial cruciate ligament rupture and dogs with no evidence of orthopedic disease of the stifle (75).

Cranial cruciate ligament rupture is also seen in dogs with patella luxation (80, 81). In the study by Gibbons of large breed dogs with patella luxation 20% of the dogs had a cranial cruciate ligament rupture (80). In another study by Campbell of small breed dogs 41% had a cranial cruciate ligament rupture and dogs with the most severe grade of patella luxation had a significantly greater chance of having a cranial cruciate ligament rupture (81). It was theorized in the last study that absence of the patella in the femoral trochlear groove may decrease the caudal force generated by the patellar ligament on the tibia, which may place additional strain on the cranial cruciate ligament and predispose it to rupture (81).

d. Blood Supply

Ischemia of the cranial cruciate ligament is another proposed mechanism for cranial cruciate ligament rupture (67, 68, 91). The midportion of the cruciate ligament is the most common site for rupture (68, 91). The cranial cruciate ligament has a decreased vascular supply when compared to the caudal cruciate ligament and the midportion of the cranial cruciate ligament is the least vascular portion of the ligament (53). It is also suggested that compression of the vessels present in the mid portion could occur as well, due to the cranial cruciate ligament twisting around the caudal cruciate ligament (92) Primary ischemia with secondary damage to the ligament was suggested in ligaments with cranial cruciate ligament rupture, because ligamentocytes (ligament cells) are replaced with chondrocytes (cartilage cells), which can survive in a hypoxic environment (91, 93). Alternatively, chronic overload of the cranial cruciate ligament was also suggested to result in microtrauma that cannot be adequately repaired, because of inadequate blood supply (67, 68). It is undetermined whether ischemia is the primary cause for rupture or is secondary to damage of the ligament (92).

e. Degeneration

Many different mechanisms of degeneration have been proposed as causes of cranial cruciate ligament rupture (3, 6, 87). Chronic overload of the cranial cruciate ligament is one proposed mechanism (3, 67, 71, 91). Histologic changes seen in ruptured cranial cruciate ligaments, such as loss of the crimped microstructure of collagen are suggestive of chronic mechanical overload resulting in microinjury to the ligament (67). Disuse of the limb in older, obese, and sedentary dogs or exercise restriction in puppies is proposed to decrease the strength of surrounding muscles of the stifle (3, 71). This may decrease support and place more strain on the cranial cruciate ligament leading to rupture (3). Weight of the animal is also implicated in increasing strain on the cranial cruciate ligament, potentially leading to its rupture (91). This is supported by a decrease in severity of degenerative changes in the cranial cruciate ligament as well as a later age of onset in dogs less than 15 kg when compared to dogs weighing greater than 15 kg in a study by Vasseur (91).

Degeneration of the cranial cruciate ligament with disruption of its structure is also proposed to be a result of inflammation (94). The ligament appears to lose its tightly organized arrangement of collagen, ligamentocytes are replaced with chondrocytes, dissolution of cell nuclei occurs, and cell death are seen in ruptured cranial cruciate ligaments (68). These changes, however are often noted before cranial cruciate ligament rupture, suggesting a progressive degeneration (91). Lymphoplasmacytic inflammation was present in 67 % of synovial membranes from dogs with cranial cruciate ligament rupture in one study (95). Increased numbers of macrophages as well as the proinflammatory cytokines tumor necrosis factor α , interleukin 1 β , and interleukin 6 are found in synovial membranes and joint capsules of dogs with cranial cruciate ligament rupture (96, 97). Inflammation may induce programmed cell death, or apoptosis in ligamentocytes and chondrocytes (98). Apoptosis is increased in dogs with partial and complete tears of the cranial cruciate ligament and may lead to loss of structural integrity of the cranial cruciate ligament and contribute to rupture (98). In addition to increased numbers of proinflammatory cytokines, degradative enzymes such as matrix metalloproteases, cathepsin K, and cathepsin S are increased in canine stifles with cranial cruciate ligament rupture (94, 97, 99-101). These increases are thought to be the result of production by macrophages that express tartrate-resistant acid phosphate, which are also increased in stifles of dogs with cranial cruciate ligament rupture (99-101). Increases in destructive enzymes are thought to occur early in the course of cranial cruciate ligament disease and precede rupture (100). These enzymes may destroy collagen in the cranial cruciate ligament and ultimately lead to rupture (99, 101). However it is still uncertain whether inflammation is the true initiating force that leads to damage of the cranial cruciate ligament or if it is a consequence of some other etiology, such as chronic mechanical overload or an immune mediated process (67, 94, 97).

An immune mediated process is another proposed mechanism thought to lead to cranial cruciate ligament rupture in dogs (94, 95, 102). Lymphocytes and plasma cells have been noted to aggregate and form nodules in the cranial cruciate ligaments of dogs with rupture (95). The nodules are representative of an immune response and the presence of plasma cells indicate production of antibodies (95). Cathepsin S, a proinflammatory mediator associated with antigen presentation in the immune response, is increased in dogs with cranial cruciate ligament rupture compared to dogs with other causes of arthritis, which is suggestive of an immune mediated arthropathy (103, 104). Increased levels of antibodies, such as immunoglobulin G and M in

synovial membranes of canine stifles with cranial cruciate ligament rupture compared to unaffected canine stifles is also suggestive of an immune mediated process (102). It is still unknown, however, if this immune response is primary or a consequence of mechanical damage to the ligament, which may expose portions of the ligament that may act as antigens and initiate an immune response, or another immunologic trigger (102, 105).

One proposed immunologic trigger is the presence of bacteria in canine stifles (103, 106). There is a significant association between the presence of bacterial DNA in canine stifle synovium and cranial cruciate ligament rupture (106). The most common bacteria present are *Borrelia burgdorferi* and *Stenotrophomonas maltophilia*, with environmental pathogens seen only in canine cranial cruciate deficient stifles (106). In experimentally induced canine cranial cruciate ligament rupture, the same patterns of bacterial DNA detection are not present, indicating that the presence of bacteria is unlikely a result of instability of the stifle (106). These bacteria may act as antigens which trigger an immune response in the canine stifle and ultimately lead to cranial cruciate ligament rupture (103, 106).

2. *Meniscus*

Meniscal injury is thought to occur frequently in canine stifles with cranial cruciate ligament rupture and is thought to be a consequence of the instability created in the joint (107). The most significant injury occurs to the caudal pole of the medial meniscus, although minor tears of the lateral meniscus can occur as well (107, 108). The prevalence of medial meniscal tears is reported in one study by Ralphs in 2002 to be 58% and the prevalence of lateral meniscal tears are reported to be 77% in canine stifles with cranial cruciate ligament rupture (107). The mechanism of injury of the medial meniscus is thought to be due to the cranial displacement of the tibia that also causes cranial displacement of the firmly attached medial meniscus, which results in crushing of the caudal pole between the medial femoral condyle and the tibial plateau (74). For this reason medial meniscal tears are more commonly identified with complete cranial cruciate ligament ruptures (107). The most common type of tear of the medial meniscus is a longitudinal tear, also known as a bucket handle tear, which in some cases can be multiple or displaced (68). Less commonly tears of the medial meniscus can occur transversely, also known as a radial tear (68, 109). When tears of the lateral meniscus occur, they are most commonly radial and on the cranial aspect (107). The significance and exact mechanism behind lateral meniscal tears is unknown, although compression of the meniscus between the intercondylar eminence of the tibia and the lateral femoral condyle is suggested (107, 110).

3. *Osteoarthritis*

Osteoarthritis, whether the result of inflammation, mechanical damage or a combination of the two mechanisms, is recognized in canine stifles with cranial cruciate ligament rupture (10, 68, 94, 111). The key features of osteoarthritis are damage to articular cartilage and osteophyte (bony outgrowth) production (25, 112). Articular cartilage damage may be a result of degradative products of inflammation or abnormal wear due to instability of the stifle (68, 94, 100, 111). Increased vascularity in the synovium due to primary inflammation or inflammation secondary to mechanical damage, leads to proliferative changes such as osteophyte formation (3, 68, 100, 111). Osteophytes are detected on the abaxial portion of both femoral and tibial condyles, trochlear ridges of the femur, distal aspect of the patella, and both fabellar sesmoids

(68). The increase in vascularity of the synovium also leads to other changes in the joint, such as generalized bone remodeling and increased production of synovial fluid (111).

D. Diagnosis

1. Signalment

Cranial cruciate ligament rupture is typically diagnosed at 7-10 years of age, although dogs can present with this injury at any age (69, 71). Dogs can even present before skeletal maturity is reached (71). Prevalence of cranial cruciate ligament rupture was increased in females in a study by Whitehair, but was not in another study by Duval (69, 70). Neutered females as well as neutered males had an increased prevalence in both studies (69, 70). Also, increased body weight is consistently associated with an increased prevalence of cranial cruciate ligament rupture (69-71). Rottweilers, Newfoundlands, Staffordshire Terriers, Mastiffs, Akitas, Saint Bernard, Chesapeake Bay Retriever, and Labrador Retriever are some breeds reported to have a higher prevalence of cranial cruciate ligament rupture (69, 70, 72, 73).

2. History

Most cases of cranial cruciate ligament rupture in dogs present several weeks after onset of lameness (3, 10, 68). The history of dogs with cranial cruciate ligament rupture reported by owners seldom includes a traumatic event other than normal exercise (68, 71). When a history of trauma is noted, it is usually associated with other ligamentous injuries of the stifle (68). Activities that are sometimes reported by the owners to be associated with the injury are running, playing, jumping, twisting of the limb, or short falls (36, 68). Lameness may have an acute or gradual onset (71). Owners may also report the lameness got better then worsened or that it is worse after rest or exercise (3, 68, 71).

3. Physical Exam

a. Lameness

Lameness associated with cranial cruciate ligament rupture can be variable (68, 71). In acute injuries the dog may be completely nonweight bearing on the limb due to pain associated with traumatic synovitis and hemarthrosis (3, 68). Lameness may improve to a low grade lameness with resolution of traumatic synovitis and hemarthrosis, but may acutely become worse if a partial tear progresses to a complete tear or a meniscal tear occurs (3, 68, 71). A stiff gait in the affected limb and lameness after rest or exercise are consistent with progression of osteoarthritis in the cranial cruciate deficient stifle (71).

b. General Palpation

Muscle atrophy of the affected hindlimb especially of the quadriceps muscle group may be noted (3, 68). If traumatic synovitis and hemarthrosis are present, most often noted in acute injuries, the stifle may be significantly painful (68). Palpation on either side of the patellar ligament while the dog is standing may reveal distention of the joint with depression of the joint

on deep palpation, which is consistent with joint effusion (3). An appreciable thickening of the joint capsule may be palpated, especially on the medial aspect of the joint (3, 68, 71). Joint effusion is usually more prominent with acute injuries and joint capsule thickening is usually more prominent with chronic injuries (3, 68). A clicking sound may be heard when the joint is put through a range of motion and represents sliding of the medial femoral condyle over the caudal pole of the medial meniscus (68). Crepitation may also be heard during range of motion of the stifle in chronic cases due to the presence of osteoarthritis (3, 68).

c. Cranial Drawer

To perform the cranial drawer test the dog is placed in lateral recumbency with the affected limb up (36). One hand is positioned with the index finger on the patella and the thumb on the lateral fabella while the other hand is positioned with the index finger on the tibial tuberosity and the thumb on the head of the fibula (3, 36). The hand positioned distally is advanced cranially while the hand positioned proximally is held stationary (36, 68). Cranial movement of the tibia relative to the femur is consistent with a positive cranial drawer sign (36). In cases of partial cranial cruciate ligament ruptures or ruptures of the craniomedial band, cranial drawer should be elicited in flexion due to the intact caudolateral band that remains taut in extension (3, 9). Pain and subsequent muscle contractions of the dog may inhibit detection of cranial drawer and in these cases sedation or general anesthesia are necessary (3, 36, 68, 71). Thickening of the joint capsule in chronic cases may also make eliciting a positive cranial drawer difficult (3, 68). Detecting subtle cranial drawer in these cases may necessitate sedation or general anesthesia as well (68).

d. Tibial Compression Test

The tibial compression test is performed with the dog in lateral recumbency with the affected leg up using one hand to grasp the femoral condyles with the index finger extended to rest along the tibial tuberosity and the other hand placed on the metatarsus (36). This test is performed by flexing the hock and feeling for cranial displacement of the tibial tuberosity, which indicates a positive tibial compression test (3, 36). This test simulates compression of the stifle between the femur and the tarsus that occurs with weight bearing and contraction of the gastrocnemius muscle that applies caudal distal force on the femur, both allowing cranial displacement of the tibia relative to the femur in absence of the cranial cruciate ligament (36). The advantage of this test is that it is not affected by muscular contractions of the dog, so does not require sedation or general anesthesia to accurately perform (3, 36).

4. Arthrocentesis

Arthrocentesis is performed by sterilely collecting a sample of synovial fluid from the stifle and can be used to rule out other disease processes such as septic arthritis and immune mediated arthritis (3). Most commonly synovial fluid in stifles with cranial cruciate ligament rupture is consistent with osteoarthritis (71). Synovial fluid is generally increased in volume, has a clear yellow color, normal viscosity, good mucin clot, absent fibrin clot, and increased white blood cells consisting mainly of mononuclear cells (3, 71).

5. Imaging

a. Radiographs

Radiographs are often used in cases of cranial cruciate ligament rupture to rule out other abnormalities that may be present in the bone or soft tissue of the stifle and to support the diagnosis of cranial cruciate ligament rupture (3). Cranial-caudal and medial-lateral radiographic projections are used most commonly (3, 68). The cruciate ligaments are not directly visible with plain radiographs, therefore the chief benefit with cranial cruciate ligament rupture is to document soft tissue changes consistent with joint effusion and the degree of osteoarthritis present (29, 68). The presence of joint effusion is noted by cranial displacement of the infrapatellar fat pad and a rounded soft tissue opacity at the caudal aspect of the stifle on the medial-lateral view as well as a rounded soft tissue opacity at the medial and lateral aspect of the stifle in the cranial-caudal view (29, 113). The presence of osteophytes surrounding the stifle are a common and reliable parameter for assessing osteoarthritis (29, 114). Osteophytes are most often present on the medial and lateral trochlear ridges of the femur, distal aspect of the patella, and abaxial aspects of the femoral and tibial condyles (29, 68). Alignment is usually not a reliable radiographic parameter for diagnosis of cranial cruciate ligament rupture when traditional radiographic views are utilized, however the presence of cranial malalignment of the tibia may be supportive in diagnosis (29). The use of medial-lateral stress radiographs, which are positioned as for the tibial compression test, can however, be useful in detecting cranial malalignment when compared to neutral medial-lateral radiographs (115). Also, evaluating the popliteal sesamoid for distal displacement, which is indicative of cranial displacement of the tibia relative to the femur, has an accuracy and specificity that approaches 100% for identifying cranial cruciate ligament rupture (34).

b. Computed Tomography

Computed tomography can be used to visualize cranial and caudal cruciate ligaments and medial and lateral menisci (116). Addition of positive contrast arthrography, which involves injection of contrast medium into the joint, is however, necessary for improved visualization of the continuity of these structures (116-118). General anesthesia is generally required for this type of imaging and its utility for diagnosis of meniscal tears is uncertain (117).

c. Ultrasound

Ultrasound can be used to visualize the cranial cruciate ligament and certain areas of the medial and lateral menisci in dogs weighing over 20 kg (119-121). The cranial cruciate ligament can be seen ultrasonographically in normal stifles and in cranial cruciate ligament deficient stifles, its absence is noted (120, 121). In chronic cases the proximal and distal ends of the torn cranial cruciate ligament can be identified with ultrasound (120). All areas of the menisci, especially the caudal aspects can be difficult to visualize with ultrasound (121). However, identification of bucket handle tears of the caudal pole of the medial meniscus with ultrasound is over 90% sensitive and specific when verified by arthroscopy (119).

d. Magnetic Resonance Imaging

Magnetic resonance imaging can be useful for identifying cranial cruciate and meniscal tears noninvasively (122-124). In dogs over 25 kg, the incidence of detection of clinically significant meniscal tears is 88 % (122). General anesthesia is required for magnetic resonance imaging, and it can be expensive and time consuming (3, 122-124).

6. Arthrotomy/Arthroscopy

Direct inspection of the inside of the joint to view the cranial cruciate ligament and the mensici can be accomplished by opening the joint surgically (arthrotomy) or viewing it through a small hole in the joint with the aid of an arthroscope (arthroscopy) (3, 125). Arthroscopic evaluation along with mechanical probing is the most accurate method for diagnosing meniscal tears, due to magnification and better lighting provided by the arthroscope (125). Arthroscopy is more technically demanding and requires special equipment, but is less minimally invasive than arthrotomy (3).

E. Treatment

Many treatment options exist for management of cranial cruciate ligament rupture (10, 68, 74, 126). These treatment options include conservative management (10), intracapsular techniques (68, 127, 128), extracapsular techniques (126, 129, 130), and osteotomy procedures (74, 131). These techniques are used in an effort to negate the effects of and/or correct the abnormal joint biomechanics that occur secondary to cranial cruciate ligament rupture (7, 60, 132-134).

1. Conservative Management

Conservative management consists of reducing pressure on the unstable stifle through weight management and controlled exercise and minimizing pain through anti-inflammatory medications (10, 25, 135). Conservative management is usually reserved for dogs under 15 kg, is not recommended for dogs with high activity levels, requires an extended recovery period, and in many cases the joint remains largely unstable (10). For this reason, some form of surgical stabilization is usually recommend over conservative management (135).

2. Surgical Options

a. Intracapsular Techniques

Intracapsular techniques involve utilizing a graft inside the joint in an attempt to reconstruct the cranial cruciate ligament (136, 137). Intracapsular techniques may be technically demanding, can be associated with residual cranial displacement of the tibia and decreased limb function (14, 127, 137). Also, grafts are exposed to similar physical and biological hazards present in the intracapsular environment as the cranial cruciate ligament (14).

i. Paatsama

In 1952 Saki Paatsama described one of the first intracapsular techniques for cranial cruciate ligament reconstruction in dogs (68, 135). The procedure involved harvesting a strip of fascia lata approximately 1 cm wide that extends from the tibial tuberosity to the patella and an equal distance proximal to the patella (68). The fascia lata is left attached distally and threaded through a tibial tunnel (from the medial aspect of the tibial tuberosity to the distal insertion of the cranial cruciate ligament), through the joint, then through a femoral tunnel (from the proximal origin of the cranial cruciate ligament to the lateral femoral condyle just above the lateral collateral ligament), and then secured with suture to the patellar ligament at the tibial tuberosity insertion (68, 135). The results in 5 clinical cases showed resolution of lameness in 80% with an approximately 3 to 5 month follow up time (68).

ii. Over the Top

The over the top procedure is an intracapsular technique developed by Arnoczky in the 1970s (128, 135). The procedure is performed by harvesting the medial third of the patellar ligament, patella, and fascia lata proximal to the patella for a distance twice that from the tibial tuberosity to the patella (128). The distal patellar ligament is left intact and the graft is passed through the joint, caudally around the lateral femoral condyle and sutured to the fascial tissues (128). Performing this procedure can result in significant patellar fractures and so can be technically difficult (135). In 28 clinical cases the results were excellent in 61 %, good in 37%, and fair in 7% with a follow up time of 3 to 19 months (128).

iii. Under and Over

In the 1980s Shires described the under and over intracapsular technique for cranial cruciate ligament reconstruction (127). The procedure involves harvesting a 1 to 2 cm strip of fascia lata extending similar to the Paatsama technique, except the lateral one third of the patellar ligament is included (68, 127, 135). This graft is passed underneath the meniscal ligament, through the joint, over the top of the lateral femoral condyle and attached with a screw and a spiked washer (127, 135). This procedure was evaluated clinically in 27 dogs with 93% having resolution of lameness at follow up which ranged from 3 to 27 months (127).

b. Extracapsular Techniques

Extracapsular techniques rely on positioning structures or materials extraarticularly to decrease cranial tibial displacement and internal rotation of the tibia relative to the femur (126, 129, 130). Of the extracapsular suture techniques, the lateral suture technique is the most commonly utilized for treatment of cranial cruciate ligament rupture (138). Extracapsular techniques can result in external rotation of the tibia relative to the femur, decreased range of motion of the stifle, abduction of the tibia, and increased pressure in the lateral compartment of the stifle (61, 139).

i. Imbrication

One of the first extracapsular techniques described for cranial cruciate ligament rupture was by Childers in 1966 (140). This technique involved placing Lembert sutures in the lateral

retinaculum of the stifle to tighten it and subsequently reduce instability of the stifle (21, 135, 140). This technique can, however, result in recurrence of instability due to stretching of the repair (135).

ii. Lateral Retinacular Imbrication

DeAngelis and Lau described an extracapsular technique, called the lateral retinacular imbrication technique in 1970 that is the basis for the lateral suture technique, which is now the most commonly utilized extracapsular procedure (126, 138). The technique originally involved a mattress suture originating behind the lateral fabella and inserting on the lateral and distal aspect of the patellar tendon (126). This technique mimics the orientation of the cranial cruciate ligament externally or outside of the joint to counteract cranial tibial displacement relative to the femur (126, 135). This procedure was tested clinically in 37 dogs and the success rate of the procedure was 85.7% with a follow up time of 2 to 13 months (126).

iii. Modified Retinacular Imbrication

A modification of the lateral retinacular imbrication technique was proposed by Flo in 1975 (130). The modified retinacular imbrication technique consists of three mattress sutures: one suture from the lateral fabella to the tibial tuberosity, one suture from the medial fabella to the tibial tuberosity, and one suture from the lateral fabella to the lateral aspect of the patellar tendon (130). In dogs greater than 20 kg the suture from the lateral fabella to the lateral aspect of the patellar tendon is omitted and replaced by a second suture from the lateral fabella to the tibial tuberosity (135). This technique was evaluated in 27 clinical cases with a 92% satisfactory outcome 6 to 10 weeks postoperatively (130).

iv. Three-in-one

The three-in-one technique is a modification of the modified retinacular imbrication technique (21, 130, 135). In addition to the sutures placed in the modified retinacular imbrication technique, the caudal belly of the sartorius muscle and the biceps femoris are advanced on the medial and lateral aspect of the stifle respectively and sutured to either side of the patellar ligament (130, 135). The objective of advancing these of muscles in the three-in-one technique is to add support to the sutures in the postoperative period (135).

v. Four-in-one Over the Top

The four-in-one over the top technique was describes by Piermattei in 1981 and is a combination of intracapsular and extracapsular techniques (135, 141). The procedure combines the three-in-one procedure and the over the top procedure (128, 135, 141). This procedure was tested in 20 clinical cases and had good or excellent outcome at a 12 months postoperatively (141).

vi. Lateral Suture

The lateral suture procedure is currently the most commonly used extracapsular procedure for cranial cruciate ligament rupture (138). The procedure evolved from the lateral retinacular imbrication and modified retinacular imbrication technique (126, 130). This technique utilizes only the mattress suture from the lateral fabella to the tibial tuberosity (130).

vii. Fibular Head Transposition

The fibular head transposition is an extracapsular technique developed by Smith in 1985 (129). The procedure involves freeing the fibular head along with the distal aspect of the lateral collateral, advancing it cranially and securing it to the tibial tuberosity with a Steinmann pin through the fibular head and tibial crest and orthopedic wire passed through the tibia crest and secured around the Steinmann pin (129, 135, 142). The procedure was performed in 71 clinical cases with function being excellent in 61%, good in 21%, fair in 7%, and poor in 3% with a follow up time of 2 to 36 months (129). Potential complications of this procedure are infection, implant migration, damage to the lateral collateral ligament, damage to the peroneal nerve, hemorrhage from the caudal geniculate artery, and fracture of the fibula (142).

c. Extracapsular Osteotomy Techniques

Osteotomy procedures involve changing the biomechanics of the joint to eliminate cranial tibial displacement relative to the femur (74, 131). Osteotomy procedures require training and specialized surgical instrumentation, do not eliminate internal rotation associated with CCL rupture (143, 144), and may be associated with meniscal injuries postoperatively (145, 146).

i. Cranial Tibial Wedge Osteotomy (CTWO)

The cranial tibial wedge osteotomy was developed by Slocum in 1984 to reduce cranial tibial displacement relative to the femur that occurs with cranial cruciate ligament rupture (147-149). A compressive force is generated between the femur and the tibia during weight bearing and sloping of the articular surface or tibial plateau causes this force to be converted to a shear force, allowing the tibia to move cranially relative to the femur (32, 36). The cranial tibial wedge osteotomy is a procedure that removes a cranial wedge or triangle of bone with the point of the triangle caudally oriented using a bone saw and compresses the two tibial fragments with a bone plate to eliminate this angulation (147). The goal of this procedure is therefore to eliminate the shear force with cranial cruciate ligament rupture (147, 148). Evaluation of the procedure in 14 clinical cases 6 months postoperatively revealed that 78% had complete return to function (147). In one study by Apelt the ideal tibial plateau angle for neutralizing cranial tibial displacement relative to the femur was between 5° and 7° (148). Some reported complications with this procedure are implant failure, varus angulation of the tibia, and inadequate reduction of the tibial plateau angle (83, 149, 150).

ii. Tibial Plateau Leveling Osteotomy (TPLO)

In 1993 Slocum introduced the tibial plateau leveling osteotomy to correct cranial displacement of the tibia relative to the femur that is seen in cranial cruciate ligament rupture, similar to the cranial tibial wedge osteotomy (36, 74, 147). The procedure involves making a circular cut with a bone saw in the proximal aspect of the tibia, rotating the tibial plateau to 5° and 7°, and securing it with a customized bone plate (74). The angle of the tibial plateau before surgery as well as the radius of the cut in the bone are used to calculate the amount of caudal rotation required to achieve the appropriate tibial plateau angle (74, 149). This is one of the most common procedures currently utilized for cranial cruciate ligament rupture (138). The procedure has been demonstrated to effectively eliminate cranial tibial displacement relative to the femur, but does not allow for normal contact mechanics between the tibia and femur (132, 144). The most common complications associated with the procedure are infection, implant failure, and tibial or fibular fracture (151, 152).

iii. Combined CTWO and TPLO

Talaat described a combination of the cranial tibial wedge osteotomy and tibial plateau leveling osteotomy in 2006 to correct larger tibial plateau angles (74, 147, 153). This procedure is designed to reduce the risk of tibial tuberosity fracture that could occur due to reduced buttressing of the tibial tuberosity with large rotations of the tibial plateau (153). Performing these combined procedures is technically difficult and the complication rate is high at 77.8% and 33% of cases required an additional surgical procedure (149, 153).

iv. Tibial Tuberosity Advancement (TTA)

Patellofemoral osteoarthritis is a problem in humans and in order to address this problem Maquet introduced a surgical technique that involves advancing the tibial tuberosity (154, 155). The procedure was performed by osteotomizing the tibial tuberosity, with its distal portion left attached to the tibia and proximal portion left attached to the patellar ligament, and advancing the tibial tuberosity by placing an iliac graft between the tibial tuberosity and the shaft of the tibia (154). The idea behind this procedure is that by increasing the lever arm of the patellar ligament, the force of the quadriceps transmitted through the patella tendon would be decreased and thus would decrease the force at the patellofemoral joint (154, 156). In human biomechanical studies it has been demonstrated that the patellar ligament pulls the tibia anteriorly when the knee is extended greater than 100 degrees and it pulls the tibia posteriorly when the knee is flexed to less than 100 degree (89). It has been noted that with the Maquet procedure the anterior cruciate ligament had decreased force acting on it in full extension and with less flexion the posterior cruciate ligament had greater force acting on it (157). An overall decrease in tension of the anterior cruciate ligament was also noted and this concept is the initiating factor behind a procedure performed in dogs for cranial cruciate ligament repair (131, 157). Montavon described a modification of the advancement of the tibial tuberosity procedure used in humans described by Maquet (131). This procedure is referred to as the tibial tuberosity advancement procedure (158). This procedure is very similar to the procedure describe by Maquet, except that implants are used to secure and advance the fragment (12, 159) The procedure involves making a complete osteotomy of the tibial tuberosity and advancing until the patellar tendon is perpendicular to the tibial plateau slope (158). The space between the tibial tuberosity and the shaft of the tibia is maintained by inserting a spacing device and the tibial tuberosity is secured

distally with a tension band or custom tension band plate (12, 131, 158-160). The proposed benefits of the tibial tuberosity advancement procedure are to eliminate cranial tibial displacement relative to the femur (160-162) and decrease retropatellar pressures (161), as described above. These claims have also been substantiated in dogs (163-165). However, tibial tuberosity advancement does not appear to eliminate internal rotation of the tibia (143, 164).

v. Proximal Tibial Intraarticular Osteotomy (PTIO)

The proximal tibial intraarticular osteotomy was described by Damur in 2003 to decrease the tibial plateau angle (166). The procedure is performed by removing a wedge or triangle of bone between the patellar ligament bursa cranially and the cranial aspect of the meniscus caudally with the point of the triangle directed distally (166). An osteotomy is made caudal from the point of the wedge to create a caudal fragment, the caudal fracture fragment is advanced cranially and the two fracture fragments are secured with two bone screws (87, 166). The complication rate in initial testing of this procedure was high with 12% valgus malalignment, 2% intraarticular screw placement, 1% popliteal artery injury, 1% cranial tibial artery injury, 1% peroneal artery injury, 2% long digital extensor injury, and 2% proximal tibial fracture (166). The procedure was modified by Jerram in 2005 to include an osteotomy of the fibula and was instead secured with a cranial to caudally directed screw and medially applied bone plate and screws (87). The complication rate with the modified procedure was still 20% and the procedure requires a considerable arthrotomy, which is why this procedure is not currently advocated (87, 149).

vi. Triple Tibial Osteotomy (TTO)

The triple tibial osteotomy is a technique described by Bruce in 2007 that involves both advancing the tibial tuberosity and reducing the tibial plateau angle (149, 167, 168). The procedure involves a partial osteotomy of the tibial tuberosity with the distal aspect left intact and a transverse wedge osteotomy caudal to the first in the proximal tibia (167). The size of the wedge osteotomy is approximately two-thirds of the angle between the patellar tendon and the tibial plateau or 0.6 times this angle plus 7 degrees (167, 168). The wedge is reduced and secured with a bone plate and this reduction reduces the tibial plateau angle and allows a cranial shift of the tibial tuberosity (149, 167). The combined procedures with this technique are proposed to result in less drastic angular alterations of the tibia than singular osteotomies (167, 168). Initial testing in 64 dogs revealed resolution of lameness in most dogs and a complication rate of 36%, with the most common complications being tibial tuberosity fractures and meniscal injuries (167). Subsequent studies of the triple tibial osteotomy had complication rates similar to other osteotomy procedures for cranial cruciate ligament rupture and suggested that the procedure is an effective treatment for cranial cruciate ligament rupture (168, 169).

vii. Chevron Wedge Osteotomy (CVWO)

The chevron wedge osteotomy for treatment of cranial cruciate ligament rupture was proposed by Hildreth in 2006 (150). This procedure is similar to the cranial tibial wedge osteotomy, except both the proximal and distal osteotomies have a “V” shape and fit together when the fragments are reduced (149, 150). The concept for this osteotomy was derived from

human osteotomy procedures and this type of osteotomy is thought to have increased stability due to resistance of cranial to caudally directed shear forces (150). There are no reports of clinical cases using this procedure (149). A study using bone models revealed that it is successful in reducing the tibial plateau angle, but does induce varus angulation (150).

F. Lateral Suture

1. Surgical Technique

As previously discussed the lateral suture procedure utilizes only the mattress suture from the lateral fabella to the tibial tuberosity described in the modified retinacular imbrication technique by Flo (130, 170). The technique is performed by first incising the biceps fascia and identifying the lateral fabella (130). A curved needle is used to pass strong nonabsorbable suture material around the lateral fabella from proximal to distal (130, 171). A hole is drilled horizontally in the proximal aspect of the tibial tuberosity and the suture is passed from lateral to medial through the hole, the back laterally over the patellar ligament, and tied to the tag of suture at the proximal aspect of the lateral fabella (130).

2. Modifications

a. Suture Configurations

The configuration of the loop of suture used for the lateral suture procedure has been modified from a single strand single loop to include other configurations (130, 172). Utilizing two strands of suture instead of one strand may allow less displacement of the tibia relative to the femur due to increased stiffness of the two strand suture construct (173). These configurations include single strand double loop, single strand locking loop, single strand interlocking loop, double strand double loop with or without one strand in a figure of eight pattern and a double strand double loop with uneven strands (172). The configuration of the loop of suture may affect the biomechanical performance of the suture (170, 172). In a study by Wallace in 2008 the single strand double loop configurations performed better than the double strand double loop configurations, the single strand interlocking loop configuration had the best performance and double strand double loop configuration with uneven strands had the poorest performance (172).

b. Suture Types

One of the most commonly utilized suture materials for the lateral suture procedures is nylon monofilament material (174). Multifilament polyethylene based sutures are however, other materials that can be used for the procedure (175, 176). When the two categories of suture material are compared the multifilament polyethylene sutures appear to have less elongation and are stronger and stiffer than monofilament nylon sutures (175). Suture reactions and increased infection rates are associated with multifilament sutures when compared to monofilament suture (135, 177).

c. Suture Securing Methods

Another modification involves utilizing different techniques for securing suture (173). Securing suture in lateral suture constructs is accomplished by means of knots or crimp clamping methods (173, 178, 179). Several types of knots can be used to secure the suture and include square knots, clamped square knots, surgeons knots, sliding half hitch knots, and self-locking knots (180, 181). The preferred method used to knot suture used for the lateral suture technique can vary depending on the suture material and can affect the structural properties of some suture materials (181, 182). In a study by Nwadike in 1998 it was determined that using a slip knot was preferred over a square knot to secure 27 kg nylon leader line and a square knot was preferred over a slip knot to secure 27 kg nylon fishing line (182). A study by Huber in 1999 demonstrated that knotting method did not affect # 2 nylon or #2 polybaster, but a surgeons knot decreased the mechanical properties of #2 polypropylene and 27 kg nylon fishing/leader line and a sliding half hitch knot decreased the mechanical properties of 27 kg nylon leader line (181). Elongation of the suture loop can occur due to tightening at the knot as a result of tension on the suture after loading (173). The areas of the suture in the knot where bends occur can lead to deformation and stress concentration in these area can lead to breaking of the suture at these points (179). The crimp clamping method of securing suture involves the use of stainless steel tubing through which suture ends are placed and the tubing is flattened over the suture to fasten it (179). The crimp clamped suture appears to have fewer areas deformation and stress concentration to have superior mechanical strength when compared to knotted suture when used with nylon leader line material (173, 178, 179). Some multifilament sutures however, are stronger when secured with a knot than with a crimp clamp (175). The mode of failure with knots is breaking near the knot and with crimp clamps it is breaking near the clamp or slipping of the suture material through the clamp (179).

d. Suture Anchors

The use of bone anchors to attach the proximal aspect of the suture to the femur is another modification (183). Suture anchors are metal devices that are secured in the bone and allow attachment of suture material (30, 183). Advantages of this type of fixation include the ability to alter the attachment site of the suture and avoidance of complications with securing the suture around the lateral fabella, such as suture slippage, damage to the lateral femorofabellar ligament, avulsion of the lateral fabella, and entrapment of tissues surrounding the fabella (170, 183). In a study by Guenego in 2007 suture anchors were used for the femoral attachment point of the lateral suture and all dogs had acceptable function of the operated limb despite pull out of the suture anchor in 21% (183). Another complication with suture anchors other than pull out of the suture anchor is weakening of suture, which occurs due to increased stress placed on the suture where it contacts the eyelet of the suture anchor (30, 175, 184).

e. Isometry

In order to obtain normal joint function, consequences of cranial cruciate ligament rupture such as cranial displacement of the tibia relative to the femur, internal rotation of the tibia relative to the femur (9), and altered joint biomechanics (132) would need to be corrected. Utilizing isometric points for lateral suture techniques is advocated as a means to achieve this (18). Isometric points are points that remain the same distance apart throughout stifle motion (17). The points of attachment of the cranial cruciate ligament are not truly isometric and the

tension on the individual components the ligament changes throughout a range of motion (9). Evaluation of potential isometric points revealed that only near isometry is achievable (17-19). In a study by Hulse in 2010, the most isometric points were from the caudal aspect of the lateral femoral condyle 3mm distal to the femorofabellar articulation to the bony protuberance located at the caudal aspect of the long digital extensor sulcus on the tibia (17). This was similar to the findings of Roe in 2008, which found that the same femoral point along with the same tibial point as well as tibial points at the bony protuberance cranial to the long digital extensor sulcus of the tibia and at the cranioproximal aspect of the tibial crest to have the least change in length between points through a range of motion of the stifle (18). However, Fischer in 2010 found that suture attachment points around the lateral fabella of the femur and through two holes in the cranioproximal aspect of the tibial crest, resulted in the least change in tension of the suture (19). Because only near isometry is achieved, tension on the suture during a normal range of motion is not consistent and increases with flexion of the stifle (19). If the suture is tensioned to prevent the cranial tibial displacement seen with cranial cruciate ligament rupture at the stifle angles representing extension, the normal range of motion of the joint may be impeded and normal joint biomechanics may not be obtained (61, 139).

f. Tightrope

Recently, a new extracapsular technique TightRope CCL® (Arthrex Vet Systems, Naples, FL) was introduced. This procedure utilizes suture anchors (buttons) and optimal suture placement (185). The goals of this new procedure were to correct all abnormalities seen in cranial cruciate ligament deficient stifles and introduce a procedure with lower rate of complications and better postoperative outcome than currently available procedures (185). Unfortunately, with TightRope CCL® no kinematic data has been obtained to confirm sufficient correction of abnormalities seen in cranial cruciate ligament deficient stifles and when comparing this procedure to a commonly used osteotomy procedure, tibial plateau leveling osteotomy this procedure did not result in significantly less complications, significantly lower postoperative radiographic osteoarthritis or a significant difference in function (185). In addition the potential increase in lateral compartmental pressure with increasing suture tension, potentially the result of abduction and external rotation of the tibia, was also seen with the TightRope CCL® as seen with lateral suture technique (139).

CHAPTER II. The effects of a novel extracapsular suture technique (lateral extracapsular suture system or LESS^a) on the kinematics of the cranial cruciate deficient stifle.

A. Objectives

The objective of this study was to evaluate cranial-caudal (x), proximal-distal (y), medial-lateral (z), extension-flexion (azimuth), internal-external rotation (elevation), and varus-valgus (role) displacement of the tibia relative to the femur between 3 stifle conditions (CCL intact, CCL deficient, and CCL deficient treated with LESS^a (LESS^a treated)) at a load of 30 % of body weight and stifle angles of 125°, 135°, and 145° using electromagnetic tracking sensors. Hypotheses were that cranial displacement and internal rotation of the tibia relative to the femur would occur in CCL deficient stifles and the LESS^a procedure would inhibit cranial displacement and internal rotation. Also, the LESS^a procedure would additionally cause external rotation of the tibia relative to the femur. No significant differences between treatment groups were expected for proximal-distal (y), medial-lateral (z), extension-flexion (azimuth), and varus-valgus (role) displacement of the tibia relative to the femur.

B. Materials and Methods

1. Specimen Preparation

Twenty cadaveric pelvic limbs were harvested from 11 skeletally mature dogs (euthanatized for reasons unrelated to this study) via disarticulation of the coxofemoral joint. Body weights were obtained for each dog before harvesting limbs. Various breeds of dogs were utilized for this study. The limbs were wrapped in towels soaked in 0.9% saline solution to provide moisture and were stored at -20° Celsius until testing. Prior to testing, the limbs were thawed to room temperature and stripped of their skin and soft tissues to the level of the metatarsus. The patella, patellar ligament, medial and lateral collateral ligaments, the joint capsule, cranial and caudal cruciate ligaments, and medial and lateral menisci were preserved. The specimens were kept moist during testing with 0.9% saline solution.

2. Radiographic Analysis

Lateral radiographs were taken of all limbs to ensure that the specimens reflected adequate skeletal maturity and were free from radiographic evidence of orthopedic disease of the stifle.

3. Cranial Cruciate Ligament Rupture Simulation and Lateral Extracapsular Suture System Procedure^a

In order to simulate rupture of the CCL a craniomedial arthrotomy was created to allow access to the CCL. This ligament was transected at its insertion on the craniomedial intercondylar area of tibia. Tibial thrust and cranial drawer were tested to confirm CCL transection. After transection the joint capsule was closed in a simple interrupted pattern using 2-0 polydioxanone (PDS)^d.

For the LESS^a procedure a right (threads oriented counterclockwise) or left (threads oriented clockwise) femoral screw was utilized (Figure 1). This was based upon which limb the procedure was being performed. The femoral screw was a 4.5 mm cortical bone screw (inner diameter = 3.8 mm, outer diameter = 4.5 mm; thread pitch = 1 mm, length = 17 mm; head height = 3 mm), produced from titanium-aluminum-niobium alloy (TiAl6Nb7). Two strands of suture, each 0.5 mm diameter and composed of 6 strands of medical grade highly-oriented-ultra-high-molecular-weight-polyethylene (Dyneema^b) and 1 strand of Gortex^c leader line, were attached to the screw head (hole for the suture = 1.2 mm, accommodating a suture bundle of 1 mm). The femoral screw was placed in the caudal aspect of the lateral femoral condyle 3 mm distal to the femoral-fabellar ligament and just cranial to the line of the caudal articular cartilage (Figure 2, 3-6) (17). The hole was predrilled with a 3.8 mm drill bit. The suture was wrapped around the caudal aspect of the screw head once (counterclockwise in right legs and clockwise in left legs) to provide 0.5 mm of additional suture length for 20° of flexion. A 4.5 mm cannulated cortical bone screw (internal diameter = 3.8 mm, outer diameter = 4.5 mm, thread pitch = 1.0 mm, length = 22 mm, hole for suture = 1.2 mm) produced from TiAl6Nb7 with a ruby eyelet (Figure 7) was placed in the tibia starting proximal and medial to the cranial aspect of the bony protuberance located cranial to the long digital extensor sulcus and directed 60 degrees to the long axis of the tibia from lateral to medial (Figure 2, 3-6). The hole was predrilled with a 3.8 mm drill bit. The suture from the femoral screw was threaded through the tibial screw from lateral to medial (Figure 2). The ends of the suture were pulled apart as they exited the tibial screw (Figure 8). A 2.5 mm in diameter conical pin made of Polyetheretherketone (PEEK) with two grooves on its outer surface to accommodate the suture (Figure 9) was placed in the distal lumen of the tibial screw (Figure 10). Once the conical pin was in place the stifle was positioned at 135° and 5 square knots were used to secure the suture into the distal groove of the conical pin under manual tension until cranial tibial displacement relative to the femur was no longer detected by palpation (Figure 11).

4. Testing Protocol

The proximal 5 cm of the femur, measured from the center of the femoral head, was osteotomized. The osteotomized portion of the femur was potted within a 3.8 cm polyvinyl chloride (PVC) pipe using polymethylmethacrylate (PMMA)^c. A previously designed custom-built mounting bracket was used for biomechanical testing (143). The bracket secured the limb to the loading frame and allowed adjustment of joint angles during testing (Figure 12).

Once the limb was loaded in the mounting bracket the total length of the altered limb, PCV pipe and PMMA, and the mounting bracket approximated the length of the limb prior to performing the femoral osteotomy. A strand of 45.5 kg monofilament nylon leader line was passed into a 2.0 mm diameter hole that was drilled in the center of the patella and the two free strands of nylon were tied together in order to form a loop with its distal portion containing the patella. The proximal portion of the nylon loop was attached to a turnbuckle link that was connected to an eyelet that attaches on the mounting bracket at its most cranial and proximal aspect to simulate the quadriceps mechanism. A strand of 45.5 kg monofilament nylon leader line was placed through a 2.0 mm diameter hole drilled through the proximal one third of the calcaneus and the two free strands were tied together in order to form a loop with its distal portion containing the calcaneus. The proximal portion of the nylon loop was attached a

turnbuckle link. At the approximate level of the origin of the gastrocnemius muscle one 8 mm eyelet was placed in the caudal femur. This eyelet was attached to the end of the turnbuckle link that was attached to the loop of nylon placed through the calcaneus. Together the loop of nylon through the calcaneus, the turnbuckle link, and the eyelet attached at the origin of the gastrocnemius muscle simulated the Achilles mechanism.

5. *Biomechanical Testing Protocol*

During a testing cycle the limb being tested was mounted in the loading frame as previously described (Figure 12). Unconstrained axial rotation of the femur was permitted by the use of custom hinges, which allowed adjustment of the coxofemoral joint's angle of abduction or adduction (132). The stifle angles were adjusted to 125°, 135°, and 145° using a goniometer with arms placed along the long axis of the femur and tibia. The angle of the coxofemoral joint and the tibiotarsal joint were manipulated during testing to correspond with the desired stifle angle (58). At 125°, 135°, and 145° the hip angles used were 133°, 115°, and 103° respectively, while the tarsus angles were 155°, 145°, and 140° as previously described (58). The phalanges of the paw contacted the base of the loading frame, but were not directly attached to the loading frame. For this reason the base of the loading frame was equipped with a textured surface (220 grit sandpaper) to keep the paw in place during testing.

A 4.5 mm in length 2.78 mm smooth Steinman pin was used to attach one electromagnetic tracking sensor^f to the lateral aspect of the distal femur and a 4.0 mm in length 3.18 mm threaded Steinman pin was used to attach the other sensor to the lateral aspect of the proximal tibia. A threaded Steinman pin was used in the tibia due to loosening seen with the smooth Steinman pin. Nylon spacers were placed between the sensors from the Steinman pins.

A load of 30% of the body weight, calculated from each animal's recorded body weight, was applied to the limb to simulate normal weight bearing. The weight of the top portion of the loading frame suspending the limb was subtracted from 30% of the body weight to obtain the load applied. Joint angles were adjusted prior to loading the limb. Joint angles were readjusted after the load was applied to ensure appropriate hip, stifle and tarsal angles. The load was removed between each stifle angle tested to allow adjustment of joint angles, then reapplied. Stifle angles of 125°, 135°, and 145° were used during testing to simulate angles formed during weight bearing through a complete range of motion. Testing groups were assigned as follows 1. CCL intact stifle, 2. CCL deficient stifle, and 3. LESS treated stifle. Groups were tested sequentially.

6. *Data Analysis*

The electromagnetic tracking system^f is designed to detect position and orientation of the sensors relative to the electromagnetic source transmitter (Figure 13) (186). It measures six degrees of freedom: x, y, z, azimuth, elevation, and roll (Figure 14, 15) (186). Cranial-caudal (x), proximal-distal (y), medial-lateral (z), extension-flexion (azimuth), internal-external rotation (elevation), and varus-valgus (roll displacement (Figure 14, 15) of the tibia relative to the femur between the 3 stifle conditions (CCL intact, CCL deficient, and LESS^a treated) at each stifle angle (125°, 135°, and 145°) were obtained using electromagnetic sensors^f.

7. *Statistical Analysis*

Differences in x, y, z, azimuth, elevation, and roll between the 3 stifle conditions (CCL intact, CCL deficient, and LESS^a treated) at each stifle angle were evaluated. Normal probability plots showed that all measurements (x, y, z, azimuth, elevation, and roll) followed an approximately normal distribution. Subsequently, data were analyzed using mixed-model repeated-measures analysis of covariance. The linear model included treatment (3 stifle conditions that included CCL intact, CCL deficient, and LESS^a treated), stifle angle (125°, 135°, and 145°), treatment and stifle angle interaction, and dog weight (the covariate) as fixed effects with Kenward-Roger as the denominator degrees of freedom. Dog number, and leg number (dog number) were specified as random effects. The AR(1) correlation structure was specified for measurements within each leg. To explicitly compare treatment least squares means at each of the stifle angles for each of the outcomes, the slice option of the glimmix procedure was applied to the treatment and stifle interaction followed by Tukey's procedure for multiple comparisons. Statistical analyses were considered significant at $p < 0.05$. All analyses were performed using SAS version 9.2 (Cary, NC, USA).

C. Results

1. General

The mean body weight of the dogs was 23.4 ± 4.6 kg (mean \pm standard deviation). All dogs were skeletally mature and free from radiographic evidence of orthopedic disease of the stifle according to lateral radiographs. Two limbs were not acceptable for testing (one limb from 2 dogs) resulting in 20 limbs from 11 dogs being used for testing rather than 22 limbs. This was due to iatrogenic patellar fracture and overdrilling of the hole in the tibial crest (required for tibial screw placement) during specimen preparation prior to biomechanical testing. Complications experienced with the procedure included breakage of the suture in one leg during knot tying, which was subsequently replaced and penetration of the femoral screw into the joint at the level of the intercondylar notch in two limbs. The means \pm standard deviations and least squares means \pm standard errors for cranial-caudal tibial displacement relative to the femur (x), proximal-distal tibial displacement relative to the femur (y), medial-lateral tibial displacement relative to the femur (z), extension-flexion of the stifle (azimuth), internal-external rotation of the tibia relative to the femur (elevation), and varus-valgus of the stifle (roll) for the 3 testing groups and the 3 testing stifle angles are presented in table 1, 2, 3, and 4 respectively. Simple effect comparisons of treatment on least squares mean difference by stifle angle and stifle angle on least squares mean difference by treatment between cranial-caudal position of the tibia relative to the femur (x), proximal-distal position of the tibia relative to the femur (y), medial-lateral position of the tibia relative to the femur (z), extension-flexion of the stifle (azimuth), internal-external rotation of the tibia relative to the femur (elevation), and varus-valgus of the stifle (roll) are presented in table 5, 6, 7, and 8 respectively.

2. Cranial-Caudal Tibial Displacement

The mean and least squares mean for cranial-caudal tibial displacement relative to the femur (x) decreased (was more caudally positioned) in order from CCL deficient, to the LESS^a treated, to the CCL intact stifle at each stifle angle and increased (was more cranially positioned) in order from stifle angles 125°, 135°, and 145° for each treatment. Cranial cruciate ligament

deficient stifles had significantly greater ($p < 0.0001$) cranial tibial displacement relative to the femur than CCL intact stifle or LESS^a treated stifles at all stifle angles. Cranial tibial displacement relative to the femur for cranial cruciate ligament intact and LESS^a treated stifles was not significantly different from one another at stifle angles of 125°, but was significantly greater for LESS^a treated stifles at stifle angles of 135° ($p = 0.0182$) and 145° ($p = 0.0012$). Cranial displacement of the tibia relative to the femur was significantly greater ($p < 0.0001$) at increasing stifle angles for each testing group.

3. Proximal-Distal Tibial Displacement

The mean and least squares mean for proximal-distal tibial displacement relative to the femur (y) increased (was more distally positioned) in order from CCL deficient, to LESS^a treated, to CCL intact stifle at stifle angles of 125° and 135°, decreased (was more proximally positioned) from CCL deficient to LESS^a treated at 145°, and increased (was more distally positioned) from LESS^a treated to CCL intact at 145°. The mean and least squares mean for proximal-distal tibial displacement relative to the femur (y) decreased (was more proximally positioned) from 125° to 135° for all testing groups as well as for 135° to 145° for CCL intact stifles and was increased (more distally positioned) from 135° to 145° for CCL deficient and LESS^a treated stifles. Cranial cruciate deficient stifles had significantly greater ($p = 0.0177$) proximal displacement than CCL intact stifles at a stifle angle of 125°. Proximal-distal displacement was not significantly different between any stifle angles for each testing group.

4. Medial-Lateral Tibial Displacement

The mean and least squares mean for medial-lateral tibial displacement relative to the femur (z) decreased (was more laterally positioned) in order from CCL deficient, to LESS^a treated, to CCL intact stifle at each stifle angle. The mean and least squares mean for medial-lateral tibial displacement relative to the femur (z) decreased (was more laterally positioned) from 125° to 135° in CCL deficient and CCL intact stifles and from 135° to 145° in CCL intact stifles. The mean and least squares mean for medial-lateral tibial displacement relative to the femur (z) increased (was more medially positioned) from 125° to 135° in LESS^a treated stifles and from 135° to 145° in CCL deficient and LESS^a treated stifles. Cranial cruciate deficient stifles had significantly greater ($p = 0.0031, 0.0022$) medial tibial displacement relative to the femur than LESS^a treated or CCL intact stifles at 125°. There was not a significant difference for medial-lateral displacement between LESS^a treated or CCL intact stifles at 125° and there were not any significant differences between testing groups at 135° or 145°. Medial-lateral displacement was not significantly different between any stifle angles for each testing group.

5. Azimuth

The mean and least squares mean for extension-flexion of the stifle (azimuth) decreased (was more flexed) in order from CCL intact stifle, to LESS^a treated, to CCL deficient at a stifle angles of 135° and 145° and in order from CCL deficient, to CCL intact, to LESS^a treated stifles at stifle angles of 125°. The mean and least squares mean for extension-flexion of the stifle (azimuth) increased (was more extended) in order from stifle angles 125°, 135°, and 145° for each testing group. Extension-flexion of the stifle was not significantly different between each

testing group for any stifle angles. Cranial cruciate intact stifles had significantly greater ($p = 0.0111$) extension at 145° than 125° .

6. Elevation

The mean and least squares mean for internal-external rotation of the tibia relative to the femur (elevation) decreased (was more externally rotated) from CCL deficient to LESS^a treated, increased (was more internally rotated) from LESS^a treated to CCL intact stifle and from CCL intact to CCL deficient stifles at all stifle angles. The mean and least squares mean for internal-external rotation of the tibia relative to the femur (elevation) decreased (was more externally rotated) from 125° to 135° in CCL deficient and LESS^a treated stifles and from angles 135° to 145° in CCL deficient stifles and increased (was more internally rotated) from angles 135° to 145° in LESS^a treated and CCL intact stifles and from 125° to 135° in CCL intact stifles. Cranial cruciate ligament deficient stifles had significantly greater ($p < 0.0001$) internal rotation than CCL intact or LESS^a treated stifles at all stifle angles. Cranial cruciate ligament intact and LESS^a treated stifle were not significantly different from one another at any of the stifle angles. Internal-external rotation was not significantly different between any stifle angles for each testing group.

7. Roll

The mean and least squares mean for varus-valgus of the stifle (roll) decreased (was more valgus) in order from CCL deficient, to LESS^a treated, to CCL intact stifle at 125° , decreased (was more valgus) from CCL deficient to LESS^a treated stifles at 135° , and increase (was more varus) from LESS^a treated to CCL intact stifles at 135° , and increased (was more varus) in order from CCL deficient, to LESS^a treated, to CCL intact stifle at 145° . The mean and least squares mean for varus-valgus of the stifle (roll) decreased (was more valgus) from 125° to 145° in CCL deficient and LESS^a treated stifles and from angles 125° to 135° in CCL intact stifles CCL and increased (was more varus) from angles 135° to 145° in CCL intact stifles. Varus-valgus of the stifle was not significantly different between each testing group for any stifle angles. Cranial cruciate deficient stifles had significantly greater ($p < 0.0192$) valgus at from at o 145° compared to at 135° .

D. Discussion

1. Hypotheses

Cranial displacement and internal rotation of the tibia relative to the femur were significant in CCL deficient stifles at all stifle angles and the LESS^a procedure effectively inhibited cranial displacement at stifle angles of 125° and internal rotation at all stifle angles, in agreement with the first hypothesis. The LESS^a procedure effectively decreased, but did not inhibit cranial displacement at stifle angles of 135° , and 145° , which is contrary to the first hypothesis. However, the LESS^a procedure did not result in significant external rotation of the tibia relative to the femur at any stifle angle, rejecting the second hypothesis. Cranial cruciate deficient stifles had significantly greater proximal displacement than CCL intact stifles at a stifle angle of 125° and cranial cruciate deficient stifles had significantly greater medial tibial

displacement relative to the femur than LESS^a treated or CCL intact stifles at 125°, rejecting the third hypothesis.

2. Design

LESS^a was designed to provide several potential advantages over currently available treatment options available for the CCL deficient stifle. It is an extracapsular technique designed to achieve axial and rotational alignment similar to what is seen in the CCL intact stifle. The suture material attachment points are located in points of the stifle that are demonstrated to be approaching isometry (17-19) and the suture material wraps around the head of the femoral screw, providing additional length during flexion, both which may help ensure that the suture material maintains enough tension to correct axial and rotational displacement seen in the CCL deficient stifle without limiting normal range of motion. The ability to restore normal axial and rotational alignment and joint range of motion may help restore normal joint biomechanics and slow the progression of osteoarthritis that occurs with CCL disease (2, 4, 6).

3. Materials

The materials used for LESS^a were chosen for strength and longevity. Bone screws are used for fixation of the suture material as opposed to incorporating soft tissues (126, 130) or suture anchors/buttons (183, 185). This may have an advantage in regards to pull out strength, although no studies have compared this. The femoral screws are also oriented differently for right and left limbs: right (threads oriented counterclockwise); left (threads oriented clockwise). The purpose of this difference in thread orientation is to decrease the risk of screw loosening with motion of the stifle. The suture would have a tendency to pull (unscrew the screw) if the threads were oriented in the same direction as the motion of the tibia (clockwise in the right leg; counterclockwise in the left leg). The suture used is composed of 6 strands of Dyneema^b and one of Gortex^c leader line making it a multifilament suture with a theoretical strength of 900 N (Data on file with KYON AG), which has a greater strength than most traditionally used orthopedic suture material (176, 178). Dyneema^b is an ultra-high-molecular-weight-polyethylene fiber that based on weight is 15 times stronger than steel and based on volume is 4 times stronger than polyester, is soft and highly pliable, resistant to fatigue and abrasion (compared to nylon, polyester, and amids) and based on histopathology induces only a mild inflammatory reaction similar to polyester (Data on file with DSM). Additionally the suture material wraps around the femoral screw and the lumen of the tibial screw is lined with ruby, both which may potentially protect the suture from abrasion due to rubbing against the eyelet, which is an advantage over traditional bone anchor techniques as the mode of failure most common with suture anchors is breakage of the suture at the eyelet (30, 184). A system that is composed of strong and durable materials may decrease the risk of complications due to implant failure.

4. Complications

The LESS^a procedure was technically easy to perform, required minimal time to implant, and was associated with few technical complications. Technical complications that occurred during testing included suture breakage during knot tying and femoral screw penetration of the joint in the area of the intercondylar notch. In the limb that suture breakage was noted, the suture

broke away from the knot likely a result of manual tension combined with strain around a bend and possibly abrasion from rubbing as the suture was tensioned. The femoral screw with attached suture was replaced and no other problems with suture breakage were noted. The complications seen with screw penetration into the joint should be avoided with increased experience with the technique.

5. Cranial-Caudal Tibial Displacement

This study evaluated cranial-caudal (x), proximal-distal (y), medial-lateral (z), extension-flexion (azimuth), internal-external rotation (elevation), and varus-valgus (role) displacement of the tibia relative to the femur between 3 stifle conditions (CCL intact, CCL deficient, and LESS^a treated) at a load of 30 % of body weight and stifle joint angles of 125°, 135°, and 145° using electromagnetic tracking sensors. These stifle angles simulate the angles formed during weight bearing through a complete range of motion (58). Similar tracking systems have been reported to have a positional resolution of 0.25 mm and a rotational resolution of 0.1° (187). Positional and rotational errors have been reported to be 1.8% and 1.6 % respectively (187). The results of the present study are in agreement with the findings of previous studies (61, 136, 188) of cranial tibial displacement relative to the femur with extracapsular techniques. LESS^a effectively decreased cranial displacement of the tibia relative to the femur induced in CCL deficient stifles at each tested stifle angle. Significant cranial displacement of the tibia relative to the femur at 135° and 145° in LESS^a treated compared to CCL intact stifles, not seen at stifle angles of 125°, may be a result of suture loosening. Loosening could be a result of elongation of the suture material (175) or elongation of the suture loop due to tightening at the knot as a result of tension on the suture after loading (173). Since square knots were tied under manual pressure, a feature that is shown to negatively affect a suture's mechanical properties, this is a likely explanation (174, 181). Cyclic loading can cause tied suture knots to elongate, due to tightening at the knot, which may be the reason for the increase in cranial tibial displacement relative to the femur as the stifle angles were increased from 125° to 145° (173). It is unlikely that the elongation is due to excessive tension, such as from less isometric positioning or failure of the unwrapping of the suture to relieve tension in flexion, because other features of excessive tension in extracapsular procedures such as valgus deformation or external rotation were not seen at any of the stifle angles treated with LESS^a (17, 61, 139). Regardless, preservation of normal range of motion, by eliminating excessive suture tension in stifle angles that represent flexion, may be more clinically important than complete elimination of cranial drawer motion (139) as demonstrated by satisfactory function in dogs with increased cranial drawer, but increase stifle range of motion (189). The concerns associated with the security of a manually tied knot, necessitate methods to secure the suture without the need for a knot and will need to be evaluated in the future

6. Proximal-Distal Tibial Displacement

Proximal displacement of the tibia occurred in CCL deficient stifles compared to LESS^a treated stifles and CCL intact stifles. This was only significant between CCL deficient and CCL intact stifles at 125° stifle angles. The reason for the proximal displacement of the tibia was likely due to a decrease in the joint space that occurred as a result of combined cranial displacement of the tibia relative to the femur and compression of the stifle. In a previous study looking at the kinematics of the intact and CCL deficient stifles in dogs, compression of the stifle

joint occurred during the start of the stance phase of gait (27). This was attributed to the cranial displacement of the tibia causing the femur to be displaced both caudally and distally and thus the tibia became proximally oriented relative to the femur (27).

7. Medial-Lateral Tibial Displacement

Medial displacement of the tibia occurred in CCL deficient stifles compared to LESS^a treated stifles and CCL intact stifles. This was only significant between CCL deficient and LESS^a treated stifles and CCL deficient and CCL intact stifles at 125° stifle angles. Medial displacement of the tibia was previously documented in one study during weight bearing in CCL deficient stifles (27). The CCL ligament may have a small influence on preventing medial translation of the tibia and this effect may be greater at stifle angles representing flexion.

8. Azimuth

Extension of the stifle was demonstrated by measuring extension-flexion of the stifle (azimuth) as the stifle angles increased from 125° to 135° to 145° for each testing group. This result was expected due to the stifle angles being manually manipulated from 125° to 135° to 145° for each testing group. Extension-flexion of the stifle was not significantly different between each testing group for any stifle angles. Significant differences seen between azimuth in CCL intact stifles between 125° and 145°, not seen in CCL deficient or treated LESS^a stifles is likely due to minor variations in angles that can be seen using goniometry (62).

9. Elevation

Internal rotation of the tibia relative to the femur was seen when CCL deficient stifles were compared to both LESS^a treated stifles and CCL intact stifles. External rotation was seen when comparing LESS^a treated stifles to CCL intact stifles. Internal rotation demonstrated in the CCL deficient stifles was significantly greater than CCL intact or LESS^a treated stifles at all stifle angles. However, the external rotation demonstrated in LESS^a treated stifles was not significantly different from CCL intact stifles. Internal rotation of the tibia relative to the femur is expected to occur in CCL deficient stifles, because the CCL plays a role in limiting internal rotation (9). Internal rotation of the tibia in CCL deficient stifles was previously demonstrated (132, 143). Significant external rotation of the tibia can be demonstrated after extracapsular procedures (61). The LESS^a procedure does not appear to induce significant external rotation as seen with other extracapsular techniques, (61, 139), which may indicate that use of the procedure may help restore more normal stifle alignment and perhaps more normal stifle biomechanics. With other extracapsular techniques tension on the suture during a normal range of motion is not consistent and increases with flexion of the stifle (19). If the suture is tensioned to prevent the cranial tibial displacement seen with CCL rupture at the stifle angles representing extension, the normal range of motion of the joint may be impeded and normal joint biomechanics may not be obtained (61, 139). Attachment points that are approaching isometry may help ensure that the suture material maintains enough tension to correct axial and rotational displacement seen in the CCL deficient stifle without limiting normal range of motion (18). Also, in the LESS^a the suture material wraps around the head of the femoral screw, which provides additional length during flexion and may decrease tension. The percentage of lengthening and strain reduction cannot be

calculated because the cadaver legs were different sizes and the suture was cut to different lengths for each leg. Also, the length of the suture in each cadaver was not measured. The ideal amount of suture length increase as well as its direct benefit will require further investigation in future studies.

10. Roll

Varus-valgus deformation was not significant between any treatment groups. This is important, because extracapsular procedures may be associated with resultant abduction or valgus of the stifle (61, 139). The valgus deformation created in the stifle may lead to increased pressure in the lateral compartment of the stifle (139). Abnormalities in contact mechanics in the joint created by this increased pressure could play a role in the progression of osteoarthritis in the stifle. Significantly greater valgus in CCL deficient stifles at 135° compared to 145° is likely due to the loss of the CCL's contribution in opposing valgus, which is greater with internal rotation of the tibia relative to the femur and with increasing stifle flexion (50).

11. Limitations

This is an in vitro/cadaveric study. In an evidence-based hierarchy scheme in vitro studies are the least clinically relevant (190). The model is limited for several reasons. The individual components of the quadriceps and Achilles mechanisms were not loaded, rather each was loaded as one mechanism. Other muscle groups were not included in the model. The motion of the stifle was not produced through active forces, but instead by manual manipulation (191). The study was performed on normal canine stifles and the parameters obtained from normal dogs may not be the same as those obtained from dogs with cranial cruciate disease (191).

E. Conclusion

The LESS^a procedure appears to effectively decrease cranial displacement and eliminates internal rotation of the tibia relative to the femur induced in CCL deficient stifles. This information indicates that it may be useful in the treatment of CCL disease. Further testing including prospective in vivo studies are necessary to validate this procedure as well as identify potential associated complications and assess clinical outcome and progression of osteoarthritis. This procedure may not result in altered alignment of the stifle as has been demonstrated with other extracapsular procedures (61, 139) and may establish more normal joint biomechanics. Studies evaluating the contact mechanics of the stifle with the LESS^a procedure as well as biomechanical and clinical studies comparing the LESS^a procedure to other currently used extracapsular procedures are necessary. The materials used in this procedure were designed for superior strength, durability, and low incidence of failure. Because some of the loosening identified may be due to tightening of the knot, further evaluation of this system using a non-slipping method of securing the suture may be warranted. Studies testing the strength of the suture material, pull out strength of the screws, and mode to failure of the system are necessary to determine if these materials offer an advantage over other available materials.

- a. Kyon Veterinary Surgical Products, Zurich, Switzerland
- b. Dyneema Purity, DSM Holland
- c. W. L. Gore & Associates, Inc; Newark, DE, USA
- d. Ethicon, Inc., a Johnson & Johnson company, Somerville, NJ, USA
- e. Technovit, Jorgensen Laboratories Inc; Loveland, CO, USA
- f. FASTRAK: Polhemus, Colchester, VT, USA

REFERENCES

1. Wilke VL, Robinson DA, Evans RB, Rothschild MF, Conzemius MG. Estimate of the annual economic impact of treatment of cranial cruciate ligament injury in dogs in the United States. *J Am Vet Med Assoc.* 2005 Nov 15;227(10):1604-7.
2. Hayashi K, Manley PA, Muir P. Cranial cruciate ligament pathophysiology in dogs with cruciate disease: a review. *J Am Anim Hosp Assoc.* 2004 Sep-Oct;40(5):385-90.
3. Johnson JM, Johnson AL. Cranial cruciate ligament rupture - pathogenesis, diagnosis, and postoperative rehabilitation. *Vet Clin N Am-Small.* 1993 Jul;23(4):717-33.
4. de Rooster H, de Bruin T, van Bree H. Morphologic and functional features of the canine cruciate ligaments. *Vet Surg.* 2006 Dec;35(8):769-80.
5. Lampman TJ, Lund EM, Lipowitz AJ. Cranial cruciate disease: current status of diagnosis, surgery, and risk for disease. *Vet Comp Orthop Traumatol.* 2003;16(3):122-6.
6. Griffon DJ. A Review of the Pathogenesis of Canine Cranial Cruciate Ligament Disease as a Basis for Future Preventive Strategies. *Vet Surg.* 2010;39(4):399-409.
7. Sanchez-Bustinduy M, De Medeiros MA, Radke H, Langley-Hobbs S, McKinley T, Jeffery N. Comparison of Kinematic Variables in Defining Lameness Caused by Naturally Occurring Rupture of the Cranial Cruciate Ligament in Dogs. *Vet Surg.* 2010;39(4):523-30.
8. Geels JJ, Roush JK, Hoskinson JJ, McLaughlin RM. Evaluation of an intracapsular technique for the treatment of cranial cruciate ligament rupture - Clinical, radiographic, scintigraphic and force plate analysis findings in 20 dogs. *Vet Comp Orthop Traumatol.* 2000;13(4):197-203.
9. Arnoczky SP, Marshall JL. The cruciate ligaments of the canine stifle: an anatomical and functional analysis. *Am J Vet Res.* 1977;38(11):1807-14.
10. Vasseur PB. Clinical-results following nonoperative management for rupture of the cranial cruciate ligament in dogs. *Vet Surg.* 1984;13(4):243-6.
11. Elkins AD, Pechman R, Kearney MT, Herron M. A retrospective study evaluating the degree of degenerative joint disease in the stifle joint of dogs following surgical repair of anterior cruciate ligament rupture. *J Am Anim Hosp Assoc.* 1991;27(5):533-40.
12. Hoffmann DE, Miller JM, Ober CP, Lanz OI, Martin RA, Shires PK. Tibial tuberosity advancement in 65 canine stifles. *Vet Comp Orthop Traumatol.* 2006;19(4):219-27.
13. Morgan JP, Voss K, Damur DM, Guerrero T, Haessig M, Montavon PM. Correlation of radiographic changes after tibial tuberosity advancement in dogs with cranial cruciate-deficient stifles with functional outcome. *Vet Surg.* 2010;39(4):425-32.
14. Vasseur PB, Berry CR. Progression of stifle osteoarthritis following reconstruction of the cranial cruciate ligament in 21 dogs. *J Am Anim Hosp Assoc.* 1992 Mar-Apr;28(2):129-36.
15. Hurley CR, Hammer DL, Shott S. Progression of radiographic evidence of osteoarthritis following tibial plateau leveling osteotomy in dogs with cranial cruciate ligament rupture: 295 cases (2001-2005). *J Am Vet Med Assoc.* 2007;230(11):1674-9.
16. Rayward RM, Thomson DG, Davies JV, Innes JF, Whitelock RG. Progression of osteoarthritis following TPLO surgery: a prospective radiographic study of 40 dogs. *J Small Anim Pract.* 2004 Feb;45(2):92-7.
17. Hulse D, Hyman W, Beale B, Saunders B, Peycke L, Hosgood G. Determination of isometric points for placement of a lateral suture in treatment of the cranial cruciate ligament deficient stifle. *Vet Comp Orthop Traumatol.* 2010;23(3):163-7.

18. Roe SC, Kue J, Gemma J. Isometry of potential suture attachment sites for the cranial cruciate ligament deficient canine stifle. *Vet Comp Orthop Traumatol.* 2008;21(3):215-20.
19. Fischer C, Cherres M, Grevel V, Oechtering G, Bottcher P. Effects of attachment sites and joint angle at the time of lateral suture fixation on tension in the suture for stabilization of the cranial cruciate ligament deficient stifle in dogs. *Vet Surg.* 2010;39(3):334-42.
20. Evans HE. Arthrology. In: Evans HE, editor. *Miller's anatomy of the dog.* 3rd ed. Philadelphia: W. B. Saunders; 1993. p. 219-57.
21. Vasseur PB. Stifle Joint. In: Slatter D, editor. *Textbook of Small Animal Surgery.* 3rd ed. Philadelphia: Elsevier; 2003. p. 2090-133.
22. Kowaleski MP, Boudrieau RJ, Pozzi A. Stifle Joint. In: Tobias KM, Johnson SA, editors. *Veterinary Surgery Small Animal.* St. Louis: Elsevier; 2012. p. 906-98.
23. *Saunders's Comprehensive Veterinary Dictionary.* 2nd ed. Philadelphia: Elsevier; 1999. Condylloid Joint; p. 632.
24. *Saunders's Comprehensive Veterinary Dictionary.* 2nd ed. Philadelphia: Elsevier; 1999. Synovial Joint; p. 633.
25. Piermattei DL, Flo GL, DeCamp CE. Arthrology. In: Piermattei DL, Flo GL, DeCamp CE, editors. *Brinker, Piermattei, and Flo's handbook of small animal orthopedics and fracture repair.* 4th ed. St Louis: Elsevier; 2006. p. 185-215.
26. Carpenter DH, Jr., Cooper RC. Mini review of canine stifle joint anatomy. *Anat Histol Embryol.* 2000 Dec;29(6):321-9.
27. Korvick DL, Pijanowski GJ, Schaeffer DJ. Three-dimensional kinematics of the intact and cranial cruciate ligament-deficient stifle of dogs. *J Biomech.* 1994;27(1):77-87.
28. Evans HE. The skeleton. In: Evans HE, editor. *Miller's anatomy of the dog.* 3rd ed. Philadelphia: W. B Saunders; 1993. p. 123-218.
29. Park RD. Radiographic evaluation of the stifle joint. *Compend Contin Educ.* 1979;1(11):833-41.
30. Aktay SA, Kowaleski MP. Analysis of suture anchor eyelet position on suture failure load. *Vet Surg.* 2011 Jun;40(4):418-22.
31. Fitch RB, Montgomery RD, Milton JL, Garrett PD, Kincaid SA, Wright JC, et al. The intercondylar fossa of the normal canine stifle an anatomic and radiographic study. *Vet Surg.* 1995 Mar-Apr;24(2):148-55.
32. Slocum B, Devine T. Cranial tibial thrust: a primary force in the canine stifle. *J Am Vet Med Assoc.* 1983 Aug 15;183(4):456-9.
33. Hayashi K, Landsdowne, J. L., Dejardin, L. M. Patellar Luxation in Dogs. In: Bojrab MJ, editor. *Mechanisms of Disease in Small Animal Surgery.* 3rd ed. Jackson: Teton NewMedia; 2010. p. 655-61.
34. de Rooster H, van Bree H. Popliteal sesamoid displacement associated with cruciate rupture in the dog. *J Small Anim Pract.* 1999 Jul;40(7):316-8.
35. Hermanson JW, Evans, H. E. The muscular system. In: Evans HE, editor. *Miller's anatomy of the dog.* 3rd ed. Philadelphia: W. B. Saunders; 1993. p. 258-384.
36. Henderson RA, Milton, J. L. The tibial compression mechanism: a diagnostic aid in stifle injuries. *J Am Anim Hosp Assoc.* 1978;14:474-9.
37. Kincaid SA, Rumph PF, Garrett PD, Baird DK, Kammermann JR, Visco DM. Morphology of the musculus articularis genus in dog with description of ectopic muscle spindles. *Anat Histol Embryol.* 1996 Jun;25(2):113-6.

38. Evans HE. The heart and arteries. In: Evans HE, editor. Miller's anatomy of the dog. 3rd ed. Philadelphia: W. B. Saunders; 1993. p. 586-681.
39. Dyce KM, Sack, W. O., Wensing, C. J. G. The cardiovascular system. In: Dyce KM, Sack, W. O., Wensing, C. J. G., editor. Textbook of veterinary anatomy. 3rd ed. Philadelphia: Elsevier; 2002. p. 217-58.
40. Evans HE. Veins. In: Evans HE, editor. Miller's anatomy of the dog. 3rd ed. Philadelphia: W. B. Saunders; 1993. p. 682-716.
41. Bezuidenhout AJ. The lymphatic system. In: Evans HE, editor. Miller's anatomy of the dog. Philadelphia: W. B. Saunders; 1993. p. 717-57.
42. Dyce KM, Sack, W. O., Wensing, C. J. G. The nervous system. In: Dyce KM, Sack, W. O., Wensing, C. J. G., editor. Textbook of veterinary anatomy. 3rd ed. Philadelphia: Elsevier; 2002. p. 259-322.
43. Kitchell RL, Evans, H. E. . The spinal nerves. In: Evans HE, editor. Miller's anatomy of the dog. 3rd ed. Philadelphia: W. B. Saunders; 1993. p. 829-93.
44. Hayashi K, Landsdowne, J. L., Dejardin, L. M. Cranial Cruciate Ligament and Meniscal Injuries in Dogs. In: Bojrab MJ, editor. Mechanisms of Disease in Small Animal Surgery. 3rd ed. Jackson: Teton NewMedia; 2010. p. 646-54.
45. Adams ME, Muir H. The glycosaminoglycans of canine menisci. *Biochem J.* 1981 Aug 1;197(2):385-9.
46. Stephan JS, McLaughlin RM, Jr., Griffith G. Water content and glycosaminoglycan disaccharide concentration of the canine meniscus. *Am J Vet Res.* 1998 Feb;59(2):213-6.
47. Kambic HE, McDevitt CA. Spatial organization of types I and II collagen in the canine meniscus. *J Orthop Res.* 2005 Jan;23(1):142-9.
48. Arnoczky SP, Warren RF. The microvasculature of the meniscus and its response to injury. An experimental study in the dog. *Am J Sports Med.* 1983 May-Jun;11(3):131-41.
49. Vasseur PB, Arnoczky SP. Collateral ligaments of the canine stifle joint: anatomic and functional analysis. *Am J Vet Res.* 1981 Jul;42(7):1133-7.
50. Monahan JJ, Grigg P, Pappas AM, Leclair WJ, Marks T, Fowler DP, et al. In vivo strain patterns in the four major canine knee ligaments. *J Orthop Res.* 1984;2(4):408-18.
51. Heffron LE, Campbell JR. Morphology, histology and functional anatomy of the canine cranial cruciate ligament. *Vet Rec.* 1978 Apr 1;102(13):280-3.
52. Arnoczky SP. Anatomy of the anterior cruciate ligament. *Clin Orthop Relat Res.* 1983 Jan-Feb(172):19-25.
53. Arnoczky SP, Rubin RM, Marshall JL. Microvasculature of the cruciate ligaments and its response to injury. An experimental study in dogs. *J Bone Joint Surg Am.* 1979 Dec;61(8):1221-9.
54. Yahia LH, Newman NM, St-Georges M. Innervation of the canine cruciate ligaments. A neurohistological study. *Anat Histol Embryol.* 1992 Mar;21(1):1-8.
55. Arcand MA, Rhalmi S, Rivard CH. Quantification of mechanoreceptors in the canine anterior cruciate ligament. *Int Orthop.* 2000;24(5):272-5.
56. Arnoczky SP. The canine cruciate ligaments: The enigma of the canine stifle. *J Small Anim Pract.* 1988;29:71-90.
57. DeCamp CE, Soutas-Little RW, Hauptman J, Olivier B, Braden T, Walton A. Kinematic gait analysis of the trot in healthy greyhounds. *Am J Vet Res.* 1993 Apr;54(4):627-34.
58. Hottinger HA, DeCamp CE, Olivier NB, Hauptman JG, Soutas-Little RW. Noninvasive kinematic analysis of the walk in healthy large-breed dogs. *Am J Vet Res.* 1996;57(3):381-8.

59. Grood ES, Suntay WJ. A joint coordinate system for the clinical description of three-dimensional motions: application to the knee. *J Biomech Eng.* 1983 May;105(2):136-44.
60. Tashman S, Anderst W, Kolowich P, Havstad S, Arnoczky S. Kinematics of the ACL-deficient canine knee during gait: serial changes over two years. *J Orthop Res.* 2004;22(5):931-41.
61. Chailleux N, Lussier B, De Guise J, Chevalier Y, Hagemester N. In vitro 3-dimensional kinematic evaluation of 2 corrective operations for cranial cruciate ligament-deficient stifle. *Can J Vet Res.* 2007;71(3):175-80.
62. Jaegger G, Marcellin-Little DJ, Levine D. Reliability of goniometry in Labrador Retrievers. *Am J Vet Res.* 2002;63(7):979-86.
63. Kanno N, Amimoto H, Hara Y, Harada Y, Nezu Y, Yogo T, et al. In vitro evaluation of the relationship between the semitendinosus muscle and cranial cruciate ligament in canine cadavers. *Am J Vet Res.* 2012 May;73(5):672-80.
64. DeCamp CE, Riggs CM, Olivier NB, Hauptman JG, Hottinger HA, Soutas-Little RW. Kinematic evaluation of gait in dogs with cranial cruciate ligament rupture. *Am J Vet Res.* 1996 Jan;57(1):120-6.
65. Budsberg SC, Verstraete MC, Soutas-Little RW, Flo GL, Probst CW. Force plate analyses before and after stabilization of canine stifles for cruciate injury. *Am J Vet Res.* 1988 Sep;49(9):1522-4.
66. Gordon-Evans WJ. Gait analysis. In: Tobias KM, Johnson SA, editors. *Veterinary Surgery Small Animal St. Louis: Elsevier; 2012. p. 1190-6.*
67. Hayashi K, Frank JD, Dubinsky C, Zhengling H, Markel MD, Manley PA, et al. Histologic changes in ruptured canine cranial cruciate ligament. *Vet Surg.* 2003 May-Jun;32(3):269-77.
68. Paatsama S. Ligament injuries in the canine stifle joint: a clinical and experimental study. Royal Veterinary College, Stockholm; 1952.
69. Whitehair JG, Vasseur PB, Willits NH. Epidemiology of cranial cruciate ligament rupture in dogs. *J Am Vet Med Assoc.* 1993 Oct 1;203(7):1016-9.
70. Duval JM, Budsberg SC, Flo GL, Sammarco JL. Breed, sex, and body weight as risk factors for rupture of the cranial cruciate ligament in young dogs. *J Am Vet Med Assoc.* 1999 Sep 15;215(6):811-4.
71. Bennett D, Tennant B, Lewis DG, Baughan J, May C, Carter S. A reappraisal of anterior cruciate ligament disease in the dog. *J Small Anim Pract.* 1988;29:275-97.
72. Wilke VL, Conzemius MG, Kinghorn BP, Macrossan PE, Cai W, Rothschild MF. Inheritance of rupture of the cranial cruciate ligament in Newfoundlands. *J Am Vet Med Assoc.* 2006 Jan 1;228(1):61-4.
73. Wilke VL, Zhang S, Evans RB, Conzemius MG, Rothschild MF. Identification of chromosomal regions associated with cranial cruciate ligament rupture in a population of Newfoundlands. *Am J Vet Res.* 2009 Aug;70(8):1013-7.
74. Slocum B, Slocum TD. Tibial plateau leveling osteotomy for repair of cranial cruciate ligament rupture in the canine. *Vet Clin N Am-Small.* 1993;23(4):777-95.
75. Mostafa AA, Griffon DJ, Thomas MW, Constable PD. Morphometric characteristics of the pelvic limbs of Labrador Retrievers with and without cranial cruciate ligament deficiency. *Am J Vet Res.* 2009 Apr;70(4):498-507.

76. Comerford EJ, Tarlton JF, Avery NC, Bailey AJ, Innes JF. Distal femoral intercondylar notch dimensions and their relationship to composition and metabolism of the canine anterior cruciate ligament. *Osteoarthritis Cartilage*. 2006 Mar;14(3):273-8.
77. Lewis BA, Allen DA, Henrikson TD, Lehenbauer TW. Computed tomographic evaluation of the canine intercondylar notch in normal and cruciate deficient stifles. *Vet Comp Orthop Traumatol*. 2008;21(2):119-24.
78. Osmond CS, Marcellin-Little DJ, Harrysson OL, Kidd LB. Morphometric assessment of the proximal portion of the tibia in dogs with and without cranial cruciate ligament rupture. *Vet Radiol Ultrasound*. 2006 Mar-Apr;47(2):136-41.
79. Guerrero TG, Geyer H, Hassig M, Montavon PM. Effect of conformation of the distal portion of the femur and proximal portion of the tibia on the pathogenesis of cranial cruciate ligament disease in dogs. *Am J Vet Res*. 2007 Dec;68(12):1332-7.
80. Gibbons SE, Macias C, Tonzing MA, Pinchbeck GL, McKee WM. Patellar luxation in 70 large breed dogs. *J Small Anim Pract*. 2006 Jan;47(1):3-9.
81. Campbell CA, Horstman CL, Mason DR, Evans RB. Severity of patellar luxation and frequency of concomitant cranial cruciate ligament rupture in dogs: 162 cases (2004-2007). *J Am Vet Med Assoc*. 2010 Apr 15;236(8):887-91.
82. Morris E, Lipowitz AJ. Comparison of tibial plateau angles in dogs with and without cranial cruciate ligament injuries. *J Am Vet Med Assoc*. 2001 Feb 1;218(3):363-6.
83. Selmi AL, Padilha Filho JG. Rupture of the cranial cruciate ligament associated with deformity of the proximal tibia in five dogs. *J Small Anim Pract*. 2001 Aug;42(8):390-3.
84. Wilke VL, Conzemius MG, Besancon MF, Evans RB, Ritter M. Comparison of tibial plateau angle between clinically normal Greyhounds and Labrador Retrievers with and without rupture of the cranial cruciate ligament. *J Am Vet Med Assoc*. 2002 Nov 15;221(10):1426-9.
85. Schwandt CS, Bohorquez-Vanelli A, Tepic S, Hassig M, Dennler R, Vezzoni A, et al. Angle between the patellar ligament and tibial plateau in dogs with partial rupture of the cranial cruciate ligament. *Am J Vet Res*. 2006 Nov;67(11):1855-60.
86. Inauen R, Koch D, Bass M, Haessig M. Tibial tuberosity conformation as a risk factor for cranial cruciate ligament rupture in the dog. *Vet Comp Orthop Traumatol*. 2009;22(1):16-20.
87. Jerram RM, Walker AM. Cranial cruciate ligament injury in the dog: pathophysiology, diagnosis and treatment. *N Z Vet J*. 2003 Aug;51(4):149-58.
88. Buote N, Fusco J, Radasch R. Age, tibial plateau angle, sex, and weight as risk factors for contralateral rupture of the cranial cruciate ligament in Labradors. *Vet Surg*. 2009 Jun;38(4):481-9.
89. Nisell R, Nemeth G, Ohlsen H. Joint forces in extension of the knee. Analysis of a mechanical model. *Acta Orthop Scand*. 1986 Feb;57(1):41-6.
90. Dennler R, Kipfer NM, Tepic S, Hassig M, Montavon PM. Inclination of the patellar ligament in relation to flexion angle in stifle joints of dogs without degenerative joint disease. *Am J Vet Res*. 2006 Nov;67(11):1849-54.
91. Vasseur PB, Pool RR, Arnoczky SP, Lau RE. Correlative biomechanical and histologic study of the cranial cruciate ligament in dogs. *Am J Vet Res*. 1985 Sep;46(9):1842-54.
92. Hayashi K, Bhandal J, Rodriguez CO, Jr., Kim SY, Entwistle R, Naydan D, et al. Vascular distribution in ruptured canine cranial cruciate ligament. *Vet Surg*. 2011 Feb;40(2):198-203.

93. Schipani E, Ryan HE, Didrickson S, Kobayashi T, Knight M, Johnson RS. Hypoxia in cartilage: HIF-1alpha is essential for chondrocyte growth arrest and survival. *Genes Dev.* 2001 Nov 1;15(21):2865-76.
94. Barrett JG, Hao Z, Graf BK, Kaplan LD, Heiner JP, Muir P. Inflammatory changes in ruptured canine cranial and human anterior cruciate ligaments. *Am J Vet Res.* 2005 Dec;66(12):2073-80.
95. Galloway RH, Lester SJ. Histopathological evaluation of canine stifle joint synovial membrane collected at the time of repair of cranial cruciate ligament rupture. *J Am Anim Hosp Assoc.* 1995 Jul-Aug;31(4):289-94.
96. Klocke NW, Snyder PW, Widmer WR, Zhong W, McCabe GP, Breur GJ. Detection of synovial macrophages in the joint capsule of dogs with naturally occurring rupture of the cranial cruciate ligament. *Am J Vet Res.* 2005 Mar;66(3):493-9.
97. Fujita Y, Hara Y, Nezu Y, Schulz KS, Tagawa M. Proinflammatory cytokine activities, matrix metalloproteinase-3 activity, and sulfated glycosaminoglycan content in synovial fluid of dogs with naturally acquired cranial cruciate ligament rupture. *Vet Surg.* 2006 Jun;35(4):369-76.
98. Kraymer M, Rytz U, Oevermann A, Doherr MG, Forterre F, Zurbriggen A, et al. Apoptosis of ligamentous cells of the cranial cruciate ligament from stable stifle joints of dogs with partial cranial cruciate ligament rupture. *Am J Vet Res.* 2008 May;69(5):625-30.
99. Muir P, Danova NA, Argyle DJ, Manley PA, Hao Z. Collagenolytic protease expression in cranial cruciate ligament and stifle synovial fluid in dogs with cranial cruciate ligament rupture. *Vet Surg.* 2005 Sep-Oct;34(5):482-90.
100. Muir P, Schamberger GM, Manley PA, Hao Z. Localization of cathepsin K and tartrate-resistant acid phosphatase in synovium and cranial cruciate ligament in dogs with cruciate disease. *Vet Surg.* 2005 May-Jun;34(3):239-46.
101. Muir P, Hayashi K, Manley PA, Colopy SA, Hao Z. Evaluation of tartrate-resistant acid phosphatase and cathepsin K in ruptured cranial cruciate ligaments in dogs. *Am J Vet Res.* 2002 Sep;63(9):1279-84.
102. Lawrence D, Bao S, Canfield PJ, Allanson M, Husband AJ. Elevation of immunoglobulin deposition in the synovial membrane of dogs with cranial cruciate ligament rupture. *Vet Immunol Immunopathol.* 1998 Sep 16;65(1):89-96.
103. Muir P, Schaefer SL, Manley PA, Svaren JP, Oldenhoff WE, Hao Z. Expression of immune response genes in the stifle joint of dogs with oligoarthritis and degenerative cranial cruciate ligament rupture. *Vet Immunol Immunopathol.* 2007 Oct 15;119(3-4):214-21.
104. Hou WS, Li W, Keyszer G, Weber E, Levy R, Klein MJ, et al. Comparison of cathepsins K and S expression within the rheumatoid and osteoarthritic synovium. *Arthritis Rheum.* 2002 Mar;46(3):663-74.
105. de Rooster H, Cox E, van Bree H. Prevalence and relevance of antibodies to type-I and -II collagen in synovial fluid of dogs with cranial cruciate ligament damage. *Am J Vet Res.* 2000 Nov;61(11):1456-61.
106. Muir P, Oldenhoff WE, Hudson AP, Manley PA, Schaefer SL, Markel MD, et al. Detection of DNA from a range of bacterial species in the knee joints of dogs with inflammatory knee arthritis and associated degenerative anterior cruciate ligament rupture. *Microb Pathog.* 2007 Feb-Mar;42(2-3):47-55.
107. Ralphs SC, Whitney WO. Arthroscopic evaluation of menisci in dogs with cranial cruciate ligament injuries: 100 cases (1999-2000). *J Am Vet Med Assoc.* 2002 Dec 1;221(11):1601-4.

108. Smith GN, Mickler EA, Albrecht ME, Myers SL, Brandt KD. Severity of medial meniscus damage in the canine knee after anterior cruciate ligament transection. *Osteoarthritis Cartilage*. 2002 Apr;10(4):321-6.
109. Whitney WO. Arthroscopic assisted surgery of the stifle joint. In: Beale BS, Hulse DA, Schulz KS, Whitney WO, editors. *Small Animal Arthroscopy*. Philadelphia: Saunders; 2003. p. 117-57.
110. Franklin S, Gilley R, Palmer R. Meniscal injury in dogs with cranial cruciate ligament rupture. *Compend Contin Educ Vet*. 2010;32(10):E1-E11.
111. Gilbertson EM. Development of periarticular osteophytes in experimentally induced osteoarthritis in the dog. A study using microradiographic, microangiographic, and fluorescent bone-labelling techniques. *Ann Rheum Dis*. 1975 Feb;34(1):12-25.
112. *Saunders' Comprehensive Veterinary Dictionary*. 2nd ed. Philadelphia: Elsevier; 1999. Osteophyte; p. 818.
113. de Bruin T, de Rooster H, Bosmans T, Duchateau L, van Bree H, Gielen I. Radiographic assessment of the progression of osteoarthrosis in the contralateral stifle joint of dogs with a ruptured cranial cruciate ligament. *Vet Rec*. 2007 Dec 1;161(22):745-50.
114. Innes JF, Costello M, Barr FJ, Rudolf H, Barr ARS. Radiographic Progression of Osteoarthritis of the Canine Stifle Joint: A Prospective Study. *Vet Radiol Ultrasound*. 2004;45(2):143-8.
115. Kim SE, Lewis DD, Pozzi A, Seibert RL, Winter MD. Radiographic quantitative assessment of cranial tibial subluxation before and after tibial plateau leveling osteotomy in dogs. *Am J Vet Res*. 2011 Mar;72(3):410-6.
116. Samii VF, Dyce J. Computed tomographic arthrography of the normal canine stifle. *Vet Radiol Ultrasound*. 2004 Sep-Oct;45(5):402-6.
117. Samii VF, Dyce J, Pozzi A, Drost WT, Mattoon JS, Green EM, et al. Computed tomographic arthrography of the stifle for detection of cranial and caudal cruciate ligament and meniscal tears in dogs. *Vet Radiol Ultrasound*. 2009 Mar-Apr;50(2):144-50.
118. Tivers MS, Mahoney P, Corr SA. Canine stifle positive contrast computed tomography arthrography for assessment of caudal horn meniscal injury: a cadaver study. *Vet Surg*. 2008 Apr;37(3):269-77.
119. Mahn MM, Cook JL, Cook CR, Balke MT. Arthroscopic verification of ultrasonographic diagnosis of meniscal pathology in dogs. *Vet Surg*. 2005 Jul-Aug;34(4):318-23.
120. Kramer M, Stengel H, Gerwing M, Schimke E, Sheppard C. Sonography of the canine stifle. *Vet Radiol Ultrasound*. 1999 May-Jun;40(3):282-93.
121. Reed AL, Payne JT, Constantinescu GM. Ultrasonographic anatomy of the normal canine stifle. *Vet Radiol Ultrasound*. 1995;36(4):315-21.
122. McCartney WT, McGovern F. Use of low-field MRA to presurgically screen for medial meniscus lesions in 30 dogs with cranial cruciate deficient stifles. *Vet Rec*. 2012 Jul 14;171(2):47.
123. Martig S, Konar M, Schmokel HG, Rytz U, Spreng D, Scheidegger J, et al. Low-field Mri and arthroscopy of meniscal lesions in ten dogs with experimentally induced cranial cruciate ligament insufficiency. *Vet Radiol Ultrasound*. 2006 Oct-Nov;47(6):515-22.
124. Barrett E, Barr F, Owen M, Bradley K. A retrospective study of the MRI findings in 18 dogs with stifle injuries. *J Small Anim Pract*. 2009 Sep;50(9):448-55.
125. Pozzi A, Hildreth BE, 3rd, Rajala-Schultz PJ. Comparison of arthroscopy and arthrotomy for diagnosis of medial meniscal pathology: an ex vivo study. *Vet Surg*. 2008 Dec;37(8):749-55.

126. DeAngelis M, Lau RE. A lateral retinacular imbrication technique for the surgical correction of anterior cruciate ligament rupture in the dog. *J Am Vet Med Assoc.* 1970;157(1):79-84.
127. Shires PK, Hulse DA, Liu W. The under-and-over fascial replacement technique for anterior cruciate ligament rupture in dogs - a retrospective study. *J Am Anim Hosp Assoc.* 1984;20(1):69-77.
128. Arnoczky SP, Tarvin GB, Marshall JL, Saltzman B. Over-the-top procedure - technique for anterior cruciate ligament substitution in the dog. *J Am Vet Med Assoc.* 1979;15(3):283-90.
129. Smith GK, Torg JS. Fibular head transposition for repair of cruciate-deficient stifle in the dog. *J Am Vet Med Assoc.* 1985;187(4):375-83.
130. Flo GL. Modification of the lateral retinacular imbrication technique for stabilizing cruciate ligament injuries. *J Am Anim Hosp Assoc.* 1975;11:570-6.
131. Montavon PM, Damur DM, Tepic S. Advancement of the tibial tuberosity for the treatment of cranial cruciate deficient canine stifle. *Proceedings of the 1st World Orthopedic Veterinary Congress, Munich, Germany. [Proceedings].* 2002:152.
132. Kim SE, Pozzi A, Banks SA, Conrad BP, Lewis DD. Effect of Tibial Plateau Leveling Osteotomy on Femorotibial Contact Mechanics and Stifle Kinematics. *Vet Surg.* 2009;38(1):23-32.
133. Kim SE, Pozzi A, Banks SA, Conrad BP, Lewis DD. Effect of Tibial Tuberosity Advancement on Femorotibial Contact Mechanics and Stifle Kinematics. *Vet Surg.* 2009;38(1):33-9.
134. Apelt D, Kowaleski MP, Boudrieau RJ. Effect of Tibial Tuberosity Advancement on Cranial Tibial Subluxation in Canine Cranial Cruciate-Deficient Stifle Joints: An In Vitro Experimental Study. *Vet Surg.* 2007;36(2):170-7.
135. Piermattei DL, Flo GL, DeCamp CE. The Stifle Joint. In: Piermattei DL, Flo GL, DeCamp CE, editors. *Brinker, Piermattei, and Flo's handbook of small animal orthopedics and fracture repair.* St Louis: Elsevier; 2006. p. 562-632.
136. Snow LA, White R, Gustafson S, Xie LIN, Hosgood G, Monroe WT, et al. Ex Vivo Comparison of Three Surgical Techniques to Stabilize Canine Cranial Cruciate Ligament Deficient Stifles. *Vet Surg.* 2010;39(2):195-207.
137. Conzemius MG, Evans RB, Besancon MF, Gordon WJ, Horstman CL, Hoefle WD, et al. Effect of surgical technique on limb function after surgery for rupture of the cranial cruciate ligament in dogs. *J Am Vet Med Assoc.* 2005 Jan 15;226(2):232-6.
138. Leighton RL. Preferred method of repair of cranial cruciate ligament rupture in dogs: a survey of ACVS diplomates specializing in canine orthopedics. *American College of Veterinary Surgery. Vet Surg.* 1999;28(3):194.
139. Tonks CA, Pozzi A, Ling H-Y, Lewis DD. The Effects of Extra-Articular Suture Tension on Contact Mechanics of the Lateral Compartment of Cadaveric Stifles Treated with the TightRope CCL® or Lateral Suture Technique. *Vet Surg.* 2010;39(3):343-9.
140. Childers HE. New method for cruciate repair. *Mod Vet Pract* 1966;47:59-60.
141. Piermattei DL, Moore RW, editors. A preliminary evaluation of a modified over-the-top procedure for ruptured cranial cruciate ligament in the dog. 8th Annual Conference of Veterinary Orthopedic Society; 1981; Snowbird, Utah.
142. Matthiesen DT. Fibular head transposition. *Vet Clin N Am-Small.* 1993 Jul;23(4):755-60.

143. Butler JR, Syrcle JA, McLaughlin RM, Elder SH. The effect of tibial tuberosity advancement and meniscal release on kinematics of the cranial cruciate ligament-deficient stifle during early, middle, and late stance. *Vet Comp Orthop Traumatol*. 2011;24(5):342-9.
144. Warzee CC, Dejardin LM, Arnoczky SP, Perry RL. Effect of tibial plateau leveling on cranial and caudal tibial thrusts in canine cranial cruciate-deficient stifles: an in vitro experimental study. *Vet Surg*. 2001;30(3):278-86.
145. Fitzpatrick N, Solano MA. Predictive variables for complications after TPLO with stifle inspection by arthrotomy in 1000 consecutive dogs. *Vet Surg*. 2010 Jun;39(4):460-74.
146. Steinberg EJ, Prata RG, Palazzini K, Brown DC. Tibial tuberosity advancement for treatment of CrCL injury: complications and owner satisfaction. *J Am Anim Hosp Assoc*. 2011 Jul-Aug;47(4):250-7.
147. Slocum B, Devine T. Cranial tibial wedge osteotomy: a technique for eliminating cranial tibial thrust in cranial cruciate ligament repair. *J Am Vet Med Assoc*. 1984 Mar 1;184(5):564-9.
148. Apelt D, Pozzi A, Marcellin-Little DJ, Kowaleski MP. Effect of cranial tibial closing wedge angle on tibial subluxation: an ex vivo study. *Vet Surg*. 2010 Jun;39(4):454-9.
149. Kim SE, Pozzi A, Kowaleski MP, Lewis DD. Tibial Osteotomies for Cranial Cruciate Ligament Insufficiency in Dogs. *Vet Surg*. 2008;37(2):111-25.
150. Hildreth BE, Marcellin-Little DJ, Roe SC, Harrysson OL. In vitro evaluation of five canine tibial plateau leveling methods. *Am J Vet Res*. 2006 Apr;67(4):693-700.
151. Priddy NH, 2nd, Tomlinson JL, Dodam JR, Hornbostel JE. Complications with and owner assessment of the outcome of tibial plateau leveling osteotomy for treatment of cranial cruciate ligament rupture in dogs: 193 cases (1997-2001). *J Am Vet Med Assoc*. 2003 Jun 15;222(12):1726-32.
152. Pacchiana PD, Morris E, Gillings SL, Jessen CR, Lipowitz AJ. Surgical and postoperative complications associated with tibial plateau leveling osteotomy in dogs with cranial cruciate ligament rupture: 397 cases (1998-2001). *J Am Vet Med Assoc*. 2003 Jan 15;222(2):184-93.
153. Talaat MB, Kowaleski MP, Boudrieau RJ. Combination tibial plateau leveling osteotomy and cranial closing wedge osteotomy of the tibia for the treatment of cranial cruciate ligament-deficient stifles with excessive tibial plateau angle. *Vet Surg*. 2006 Dec;35(8):729-39.
154. Maquet P. Advancement of the tibial tuberosity. *Clin Orthop Relat Res*. 1976 Mar-Apr(115):225-30.
155. Spector TD, Hart DJ, Byrne J, Harris PA, Dacre JE, Doyle DV. Definition of osteoarthritis of the knee for epidemiological studies. *Ann Rheum Dis*. 1993 Nov;52(11):790-4.
156. Nakamura N, Ellis M, Seedhom BB. Advancement of the tibial tuberosity. A biomechanical study. *J Bone Joint Surg Br*. 1985 Mar;67(2):255-60.
157. Shirazi-Adl A, Mesfar W. Effect of tibial tubercle elevation on biomechanics of the entire knee joint under muscle loads. *Clin Biomech (Bristol, Avon)*. 2007 Mar;22(3):344-51.
158. Montavon PM, Damur DM, Tepic S. Tibial tuberosity advancement (TTA) for the treatment of cranial cruciate disease in dogs: evidences, technique and initial clinical results. . 12th ESVOT Congress. 2004:254-5.
159. Lafaver S, Miller NA, Stubbs WP, Taylor RA, Boudrieau RJ. Tibial tuberosity advancement for stabilization of the canine cranial cruciate ligament-deficient stifle joint: surgical technique, early results, and complications in 101 dogs. *Vet Surg*. 2007;36(6):573-86.
160. Tepic S, Montavon PM, editors. Is cranial tibial advancement relevant in the cruciate deficient stifle. 12th ESVOT Congress 2004 September 10-12; Munich, Germany.

161. Montavon PM, editor. Tibial tuberosity advancement biomechanics and surgical procedure. ACVS veterinary symposium; 2005 October 27-29; San Diego, California.
162. Boudrieau RJ, editor. Tibial tuberosity advancement (TTA) clinical results. ACVS veterinary symposium; 2005 October 27-29; San Diego, California.
163. Kim SE, Pozzi A, Banks SA, Conrad BP, Lewis DD. Effect of tibial tuberosity advancement on femorotibial contact mechanics and stifle kinematics. *Vet Surg.* 2009 Jan;38(1):33-9.
164. Miller JM, Shires PK, Lanz OI, Martin RA, Grant JW. Effect of 9mm tibial tuberosity advancement on cranial tibial translation in the canine cranial cruciate ligament-deficient stifle. *Vet Surg.* 2007;36(4):335-40.
165. Guerrero TG, Pozzi A, Dunbar N, Kipfer N, Haessig M, Beth Horodyski M, et al. Effect of tibial tuberosity advancement on the contact mechanics and the alignment of the patellofemoral and femorotibial joints. *Vet Surg.* 2011 Oct;40(7):839-48.
166. Damur DM, Tepic S, Montavon PM. Proximal tibial osteotomy for the repair of cranial cruciate-deficient stifle joints in dogs. *Vet Comp Orthop Traumatol.* 2003;16:211-6.
167. Bruce WJ, Rose A, Tuke J, Robins GM. Evaluation of the triple tibial osteotomy. A new technique for the management of the canine cruciate-deficient stifle. *Vet Comp Orthop Traumatol.* 2007;20(3):159-68.
168. Moles AD, Hill TP, Glyde M. Triple tibial osteotomy for treatment of the canine cranial cruciate ligament-deficient stifle joint. Surgical findings and postoperative complications in 97 stifles. *Vet Comp Orthop Traumatol.* 2009;22(6):473-8.
169. Renwick AI, McKee WM, Emmerson TD, House AK. Preliminary experiences of the triple tibial osteotomy procedure: tibial morphology and complications. *J Small Anim Pract.* 2009 May;50(5):212-21.
170. Tonks CA, Lewis DD, Pozzi A. A review of extra-articular prosthetic stabilization of the cranial cruciate ligament-deficient stifle. *Vet Comp Orthop Traumatol.* 2011;24(3):167-77.
171. Casale SA, McCarthy RJ. Complications associated with lateral fabellotibial suture surgery for cranial cruciate ligament injury in dogs: 363 cases (1997-2005). *J Am Vet Med Assoc.* 2009 Jan 15;234(2):229-35.
172. Wallace A, Cutting T, Sutcliffe M, Langley-Hobbs S. A biomechanical comparison of six double loop configurations for use in the lateral fabella suture technique. *Vet Comp Orthop Traumatol* 2008;21(5):391-9.
173. Vianna ML, Roe SC. Mechanical Comparison of Two Knots and Two Crimp Systems for Securing Nylon Line Used for Extra-Articular Stabilization of the Canine Stifle. *Vet Surg.* 2006;35(6):567-72.
174. Caporn TM, Roe SC. Biomechanical evaluation of the suitability of monofilament nylon fishing line and leader line for extra-articular stabilization of the cranial cruciate deficient stifle. *Vet Comp Orthop Traumatol.* 1996;9:126-33.
175. Burgess R, Elder S, McLaughlin RON, Constable P. In Vitro Biomechanical Evaluation and Comparison of FiberWire, FiberTape, OrthoFiber, and Nylon Leader Line for Potential Use During Extraarticular Stabilization Of Canine Cruciate Deficient Stifles. *Vet Surg.* 2010;39(2):208-15.
176. Rose ND, Goerke D, Evans RB, Conzemius MG. Mechanical Testing of Orthopedic Suture Material Used for Extra-Articular Stabilization of Canine Cruciate Ligament-Deficient Stifles. *Vet Surg.* 2012;41(2):266-72.

177. Dulisch M. Suture reaction following extra-articular stifle stabilization in the dog. Part I. A retrospective study of 161 stifles. *J Am Anim Hosp Assoc.* 1981;17:569.
178. Sicard GK, Hayashi K, Manley PA. Evaluation of 5 types of fishing material, 2 sterilization methods, and a crimp-clamp system for extra-articular stabilization of the canine stifle joint. *Vet Surg.* 2002;31(1):78-84.
179. Anderson CC, 3rd, Tomlinson JL, Daly WR, Carson WL, Payne JT, Wagner-Mann CC. Biomechanical evaluation of a crimp clamp system for loop fixation of monofilament nylon leader material used for stabilization of the canine stifle joint. *Vet Surg.* 1998 Nov-Dec;27(6):533-9.
180. McKee WM, Miller A. A self-locking knot for lateral fabellotibial suture stabilization of the cranial cruciate ligament deficient stifle in the dog. *Vet Comp Orthop Traumatol.* 1999;12:78-80.
181. Huber DJ, Egger EL, James SP. The effect of knotting method on the structural properties of large diameter nonabsorbable monofilament sutures. *Vet Surg.* 1999;28(4):260-7.
182. Nwadike BS, Roe SC. Mechanical comparison of suture material and knot type used for fabello-tibial suture. *Vet Comp Orthop Traumatol.* 1998;11:47-52.
183. Guenego L, Zahra A, Madelenat A, Gautier R, Marcellin-Little DJ, Hulse D. Cranial cruciate ligament rupture in large and giant dogs. A retrospective evaluation of a modified lateral extracapsular stabilization. *Vet Comp Orthop Traumatol.* 2007;20(1):43-50.
184. Meyer DC, Nyffeler RW, Fucentese SF, Gerber C. Failure of suture material at suture anchor eyelets. *Arthroscopy.* 2002;18(9):1013-9.
185. Cook JL, Luther JK, Beetem J, Karnes J, Cook CR. Clinical Comparison of a Novel Extracapsular Stabilization Procedure and Tibial Plateau Leveling Osteotomy for Treatment of Cranial Cruciate Ligament Deficiency in Dogs. *Vet Surg.* 2010;39(3):315-23.
186. Jordan K, Dziedzic K, Jones PW, Ong BN, Dawes PT. The reliability of the three-dimensional FASTRAK measurement system in measuring cervical spine and shoulder range of motion in healthy subjects. *Rheumatology (Oxford).* 2000 Apr;39(4):382-8.
187. Milne AD, Chess DG, Johnson JA, King GJ. Accuracy of an electromagnetic tracking device: a study of the optimal range and metal interference. *J Biomech.* 1996 Jun;29(6):791-3.
188. Harper TAM, Martin RA, Ward DL, Grant JW. An In Vitro Study to Determine the Effectiveness of a Patellar Ligament/Fascia Lata Graft and New Tibial Suture Anchor Points for Extracapsular Stabilization of the Cranial Cruciate Ligament-Deficient Stifle in the Dog. *Vet Surg.* 2004;33(5):531-41.
189. Hill CM, Conzemius MG, Smith GK. Bacterial culture of the canine stifle joint following surgical repair of ruptured cranial cruciate ligament. *Vet Comp Orthop Traumatol.* 1999;12:1-5.
190. Aragon CL, Budsberg SC. Applications of Evidence-Based Medicine: Cranial Cruciate Ligament Injury Repair in the Dog. *Vet Surg.* 2005;34(2):93-8.
191. Beck PR. Trochlear contact pressures after anteromedialization of the tibial tubercle. *Am J Sports Med.* 2005;33(11):1710-5.

APPENDIX: Figures



Figure 1: Femoral screws. Left and right femoral screws (left and right respectively) and custom screw driver (center) for the LESS^a procedure.

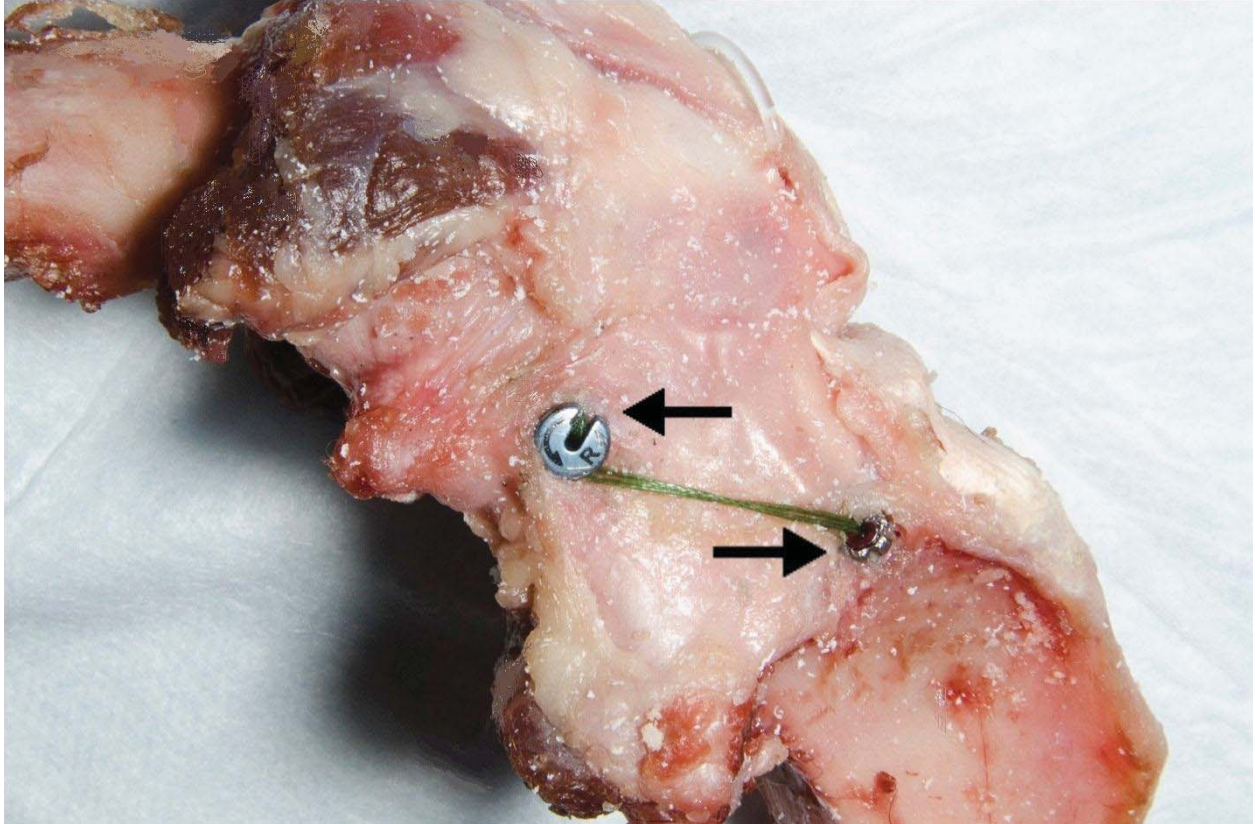


Figure 2: Lateral view of LESS^a. Lateral view of a stifle with LESS^a femoral screw (upper arrow), cannulated tibial screw (lower arrow), and suture strands in place.

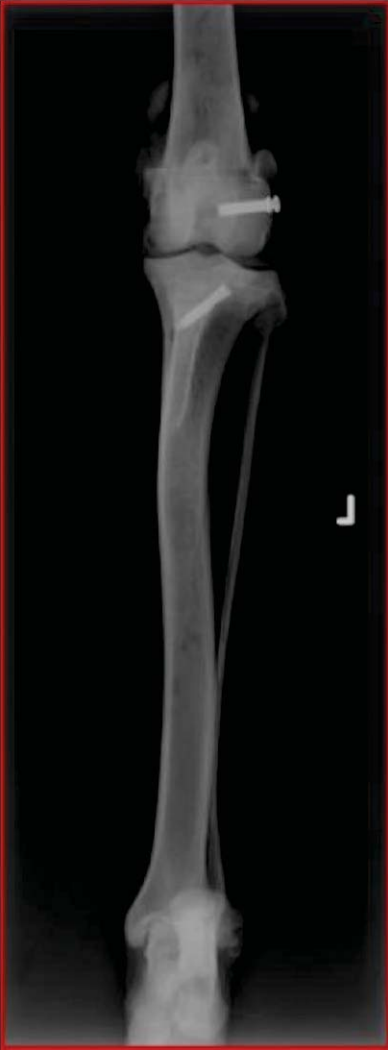

Figure 3: Left cranial-caudal radiograph. Stifle with LESS^a in place.

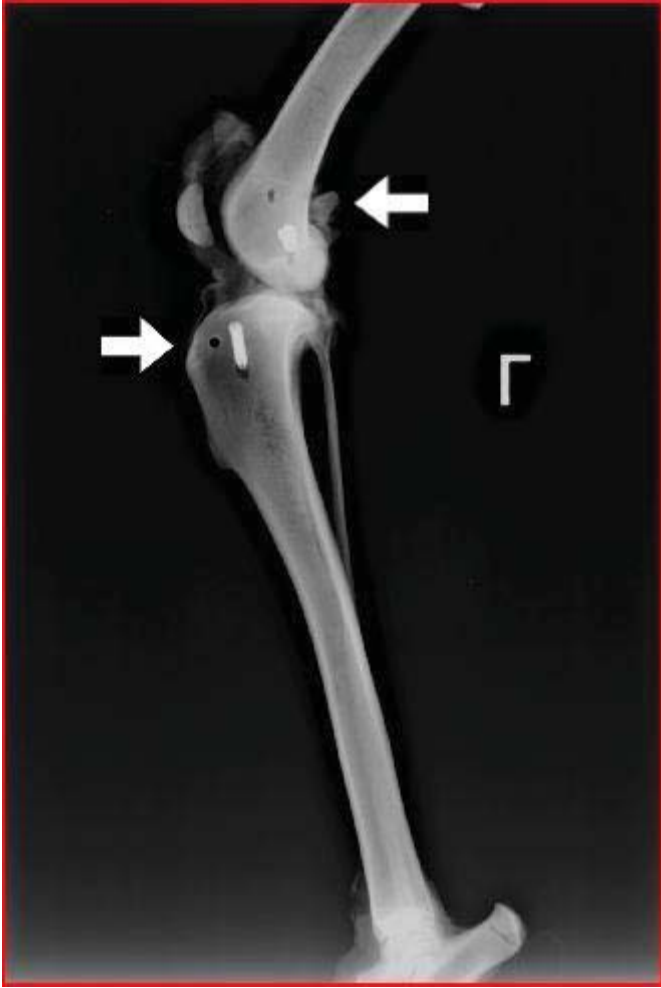

Figure 4: Left lateral radiograph. Stifle with LESS^a in place (white arrow illustrate radiolucent holes made by femoral and tibial sensor pins).

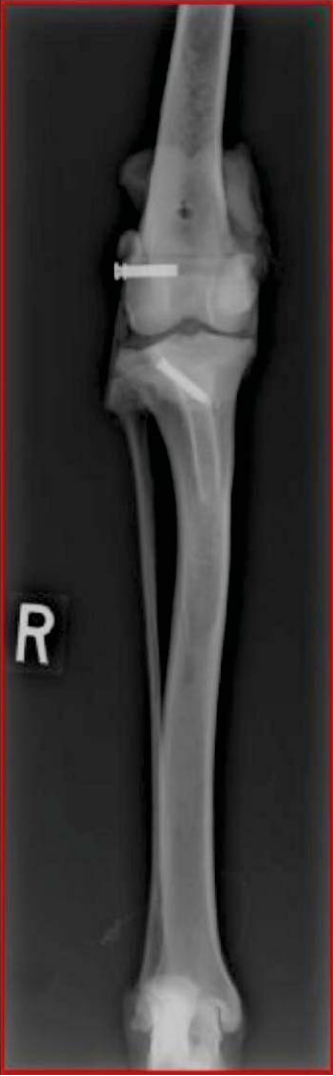

Figure 5: Right cranial-caudal radiograph. Stifle with LESS^a in place.

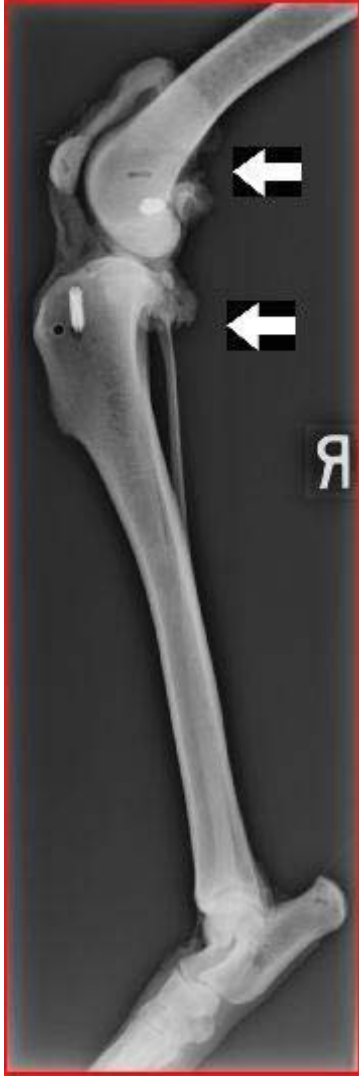

Figure 6: Right lateral radiograph. Stifle with LESS^a in place (white arrow illustrates radiolucent holes made by femoral and tibial sensor pins).



Figure 7: Cannulated tibial screw. Cannulated tibial screw (right) and custom screw driver (left) for the LESS^a procedure.

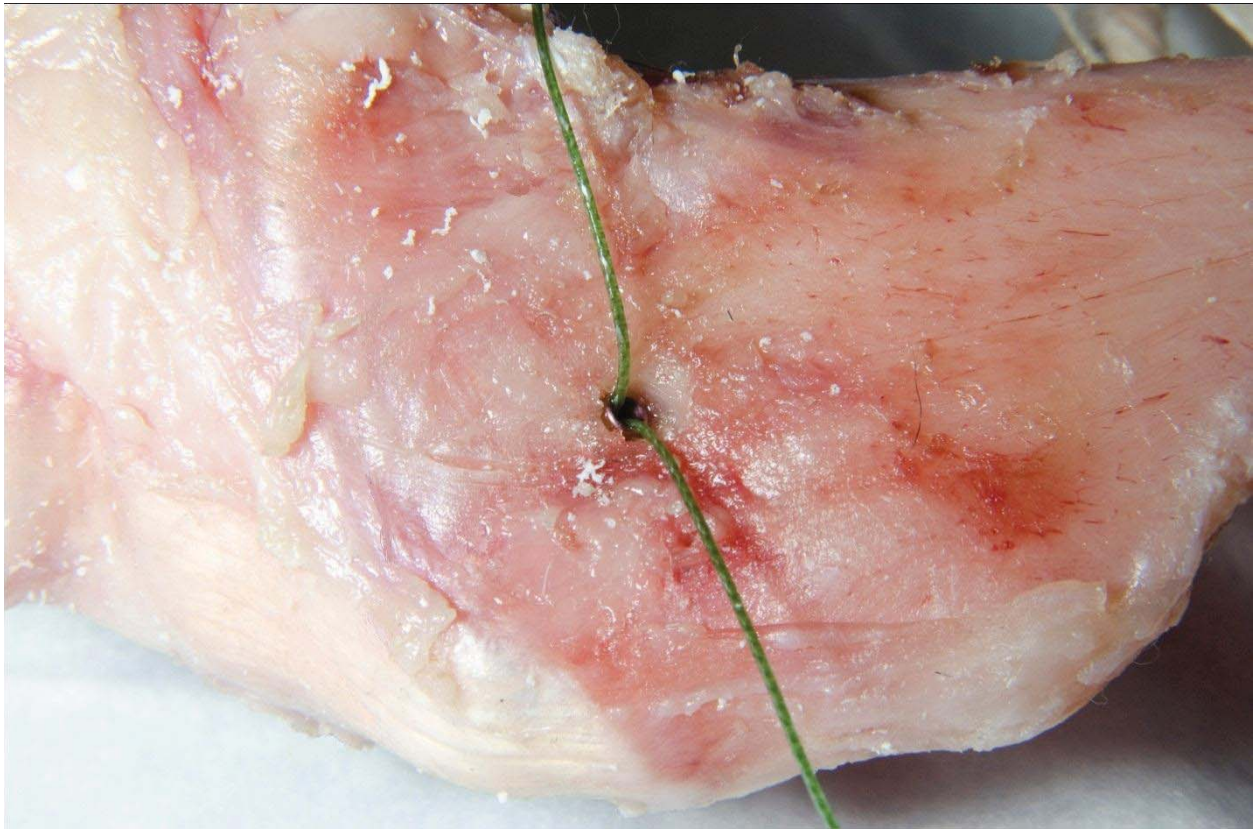

Figure 8: Medial view of LESS^a. A stifle with LESS^a in place demonstrating suture strands exiting from the cannulated tibial screw.



Figure 9: Plastic stopper. Plastic stopper used to secure suture strands distally in the cannulated tibial screw for the LESS^a procedure.

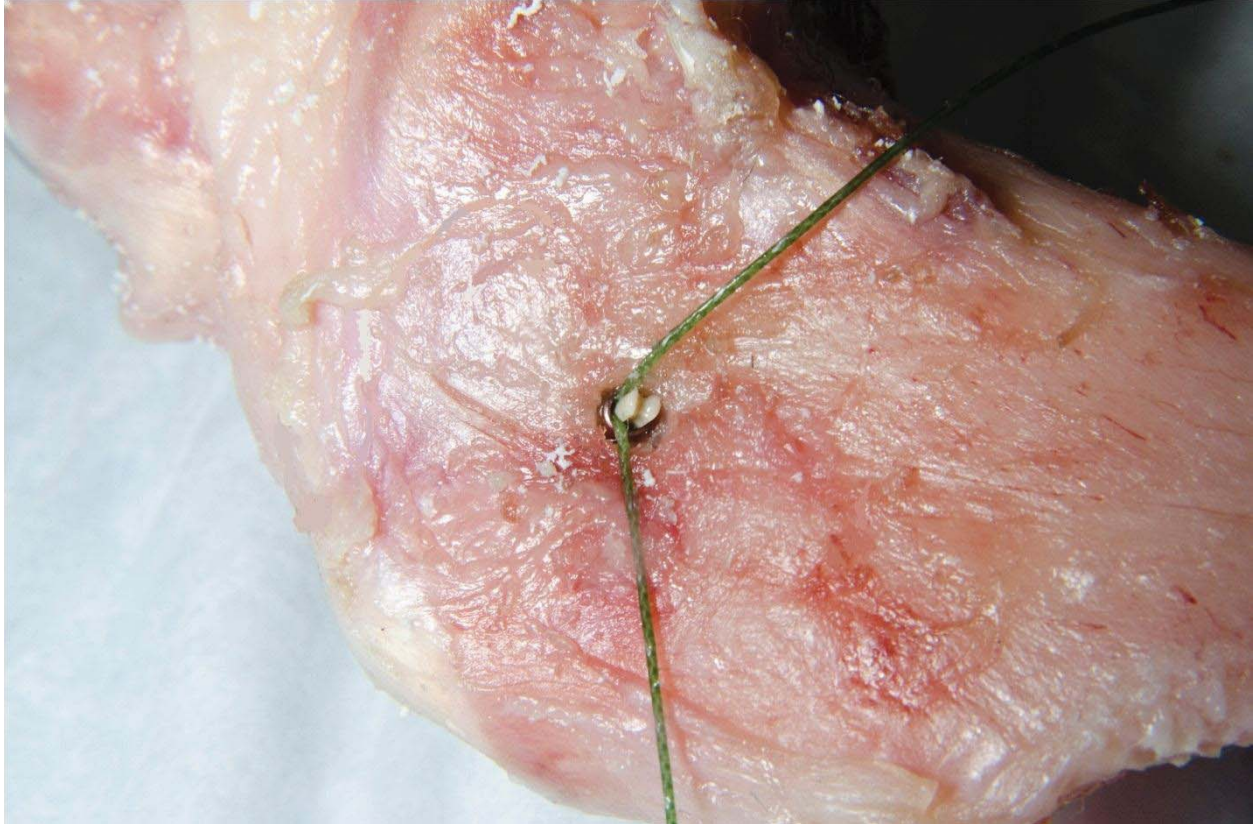

Figure 10: Placement of the plastic stopper. Medial view of a stifle with LESS^a in place demonstrating placement of the plastic stopper in the distal aspect of cannulated tibial screw.

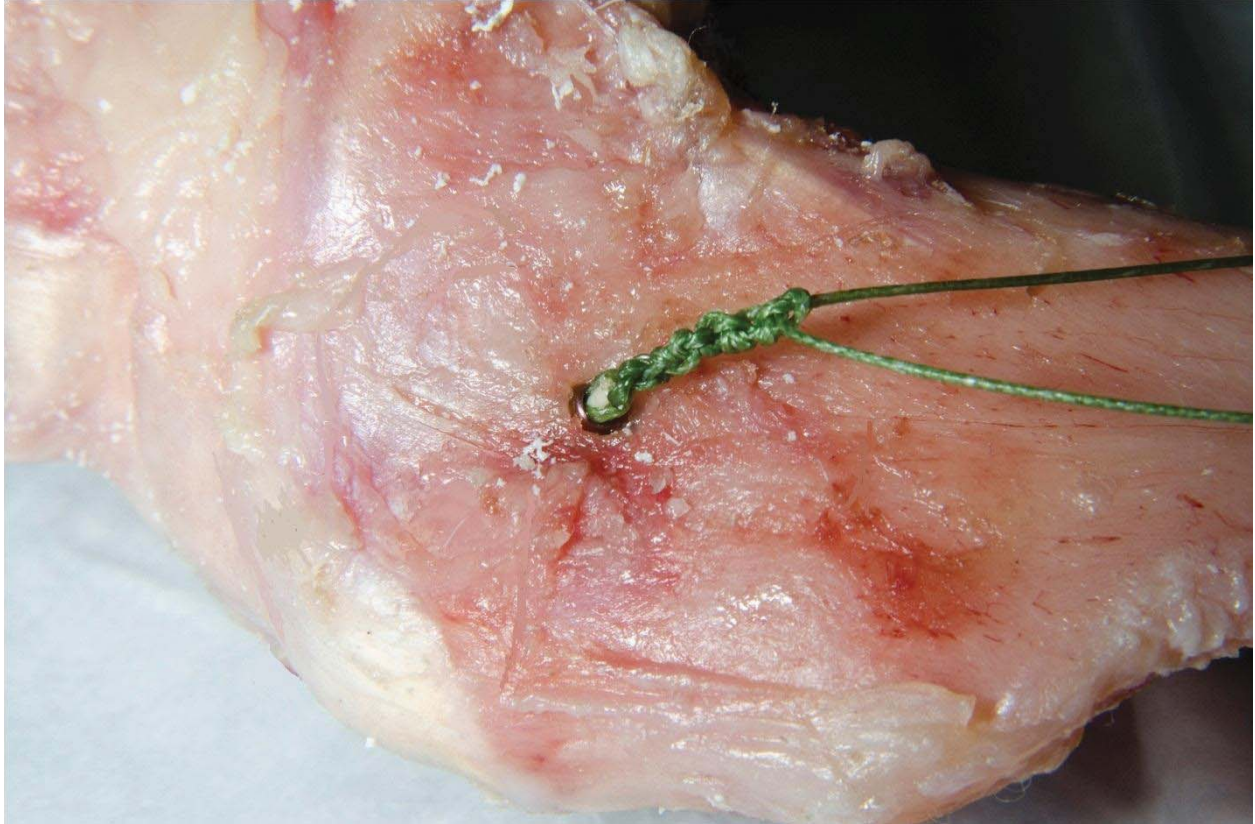


Figure 11: Placement of suture knots. Medial view of a stifle with LESS^a in place demonstrating placement of suture knots over the plastic stopper in the distal aspect of cannulated tibial screw.



Figure 12: Loading frame. Biomechanical testing setup with the limb secured into the loading frame and femoral and tibial sensors in place.




Figure 13: Biomechanical testing setup. Loading frame with limb positioned at 135° and electromagnetic tracking system^f connected to the femoral and tibial sensors.

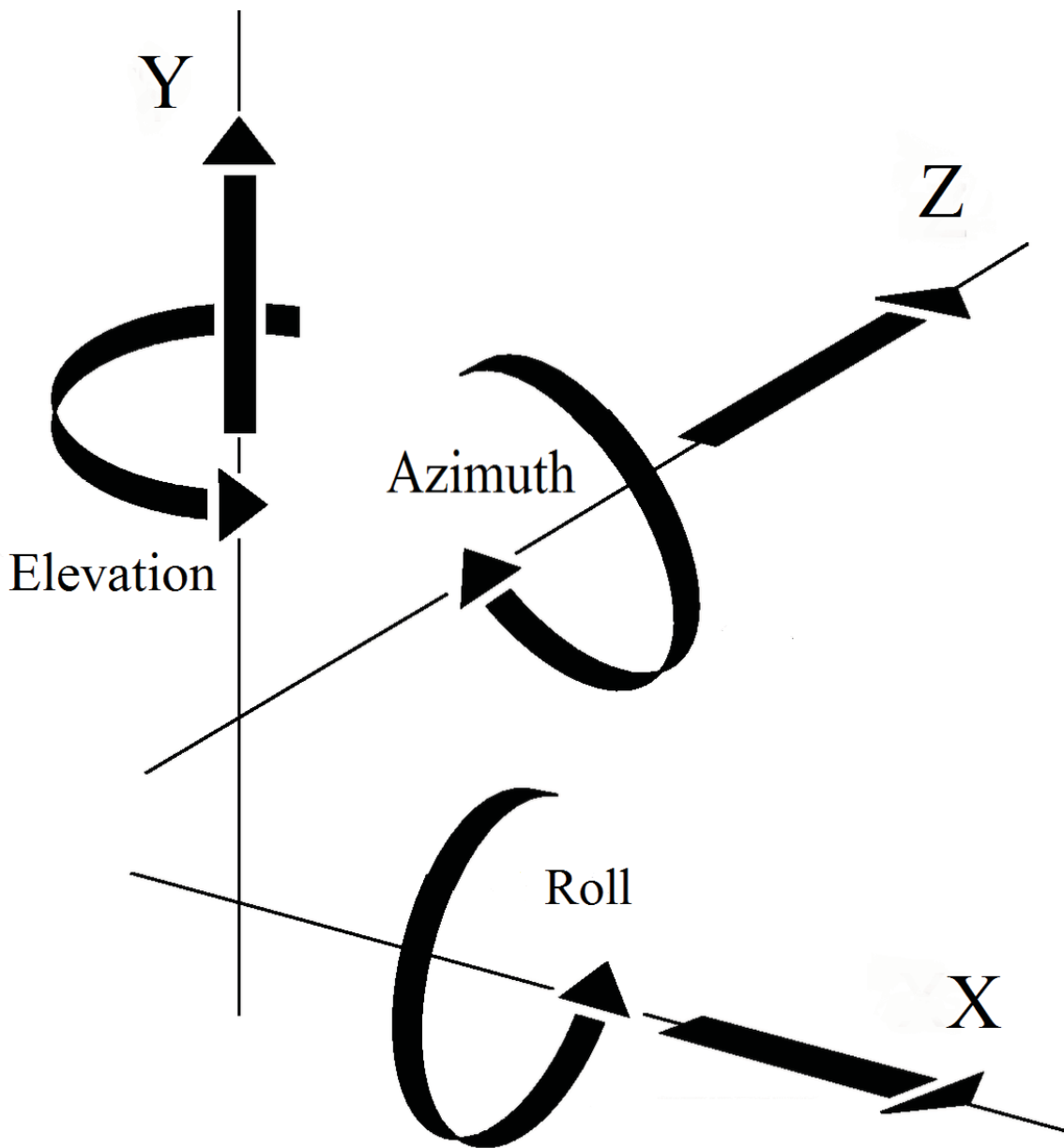


Figure 14: Six degrees of freedom. Six degrees of freedom measured by the electromagnetic tracking system: (A) y = proximal distal displacement, z = medial-lateral displacement; (B) x = cranial-caudal displacement; (C) roll = varus-valgus displacement; (D) azimuth = extension-flexion, elevation = internal-external rotation. Higher values represent cranial displacement, lower values represent caudal displacement; higher values represent distal displacement, lower values represent proximal displacement; higher values represent medial displacement, lower values represent lateral displacement; higher values represent extension, lower values represent flexion; higher values represent internal rotation, lower values represent external rotation; higher values represent varus, lower values represent valgus.

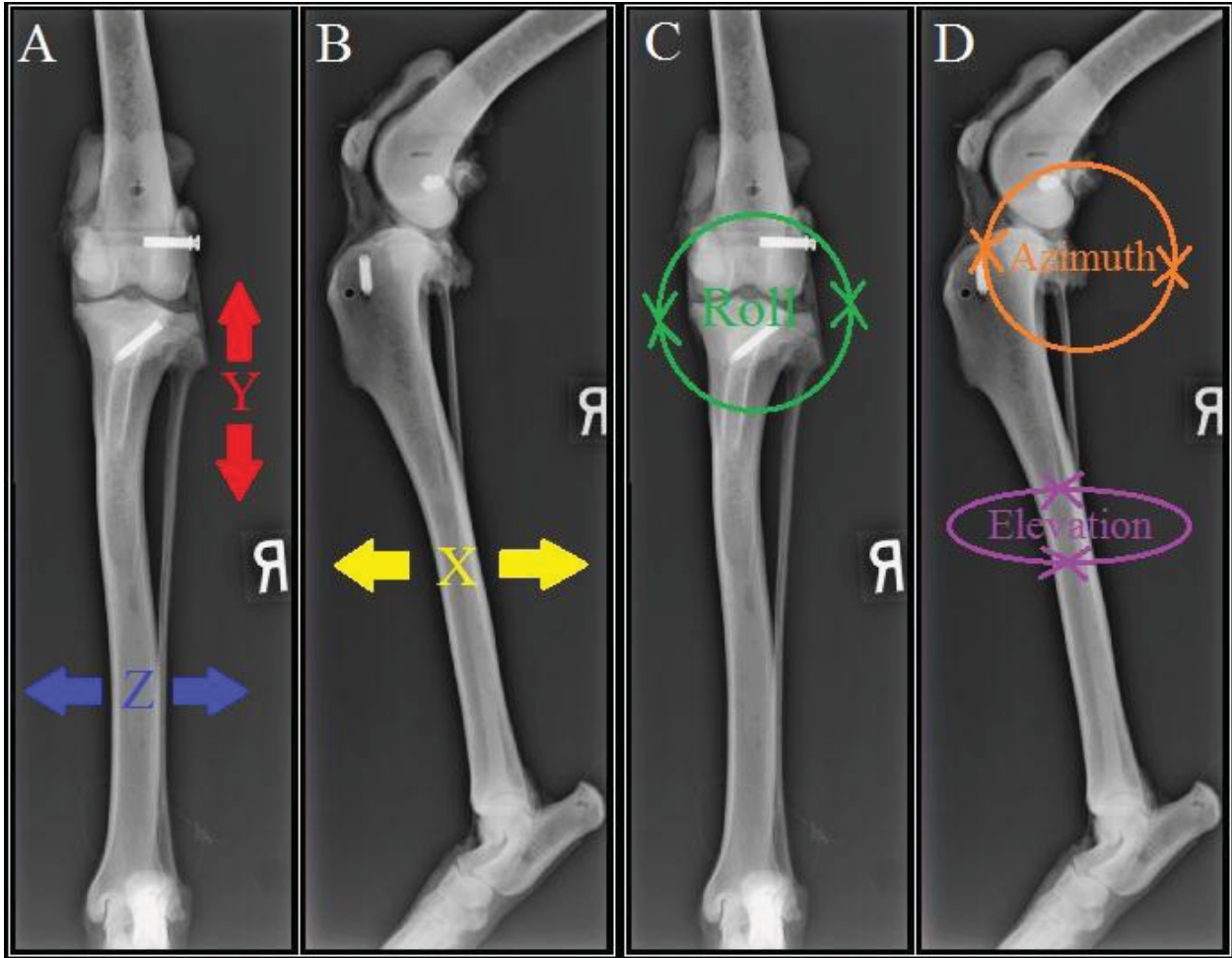


Figure 15: Six degrees of freedom. Six degrees of freedom measured by the electromagnetic tracking system: (A) y = proximal distal displacement, z = medial-lateral displacement; (B) x = cranial-caudal displacement; (C) roll = varus-valgus displacement; (D) azimuth = extension-flexion, elevation = internal-external rotation.

APPENDIX: Tables

Stifle Angle	Treatment	Mean +/- Standard Deviation		
		x	y	z
125	CCL deficient	-2.5030 +/- 1.10411	-4.7765 +/- 3.65545	2.1830 +/- 3.90444
125	LESS treated	-3.5175 +/- 1.02815	-4.2975 +/- 0.89817	0.7685 +/- 0.50477
125	CCL intact	-3.8290 +/- 0.88337	-3.6595 +/- 0.85215	0.7250 +/- 0.43954
135	CCL deficient	0.1815 +/- 1.19897	-5.1200 +/- 0.71472	1.4555 +/- 0.45395
135	LESS treated	-1.2630 +/- 1.04543	-4.8855 +/- 0.71751	0.9265 +/- 0.45770
135	CCL intact	-1.7880 +/- 0.89414	-4.4350 +/- 0.73882	0.7100 +/- 0.43023
145	CCL deficient	1.3930 +/- 1.19445	-4.5650 +/- 0.87410	1.5545 +/- 0.51571
145	LESS treated	0.3025 +/- 1.05305	-4.8165 +/- 0.80290	1.0700 +/- 0.49229
145	CCL intact	-0.3885 +/- 0.88911	-4.5720 +/- 0.80613	0.6990 +/- 0.42370

Table 1: Mean +/- standard deviation (x, y, z). Mean +/- standard deviation (mm) between cranial-caudal (x), proximal-distal (y), and medial-lateral (z) tibial displacement relative to the femur for 3 testing groups and 3 testing stifle angles (higher values represent cranial displacement, lower values represent caudal displacement; higher values represent distal displacement, lower values represent proximal displacement; higher values represent medial displacement, lower values represent lateral displacement).

Stifle Angle	Treatment	Mean +/- Standard Deviation		
		azimuth	elevation	roll
125	CCL deficient	-5.1385 +/- 37.3507	-2.2145 +/- 12.4513	1.0300 +/- 12.5144
125	LESS treated	-15.3885 +/- 30.3513	-14.8550 +/- 12.8951	0.8610 +/- 11.5227
125	CCL intact	-18.8830 +/- 22.2835	-13.9045 +/- 12.7444	0.5485 +/- 10.1014
135	CCL deficient	-9.5300 +/- 29.4051	-2.2225 +/- 9.6553	0.9480 +/- 11.4395
135	LESS treated	-10.5005 +/- 30.2888	-14.9935 +/- 10.4766	-1.6965 +/- 13.3262
135	CCL intact	-6.6345 +/- 30.2830	-13.8650 +/- 11.0808	0.1320 +/- 10.2401
145	CCL deficient	0.3865 +/- 33.5768	-2.6680 +/- 9.7687	-4.3575 +/- 13.1535
145	LESS treated	-1.2685 +/- 34.6392	-13.6140 +/- 10.4730	-4.0575 +/- 13.2319
145	CCL intact	5.6435 +/- 33.4857	-12.6415 +/- 10.6412	0.6780 +/- 10.2106

Table 2: Mean +/- standard deviation (azimuth, elevation, roll). Mean +/- standard deviation (degrees) between extension-flexion of the stifle (azimuth), internal-external rotation of the stifle (elevation), and varus-valgus of the stifle (roll) for 3 testing groups and 3 testing stifle angles (higher values represent extension, lower values represent flexion; higher values represent internal rotation, lower values represent external rotation; higher values represent varus, lower values represent valgus).

Stifle Angle	Treatment	Least squares mean +/- Standard Error		
		x	y	z
125	CCL deficient	-2.5150 +/- 0.2551	-4.7539 +/- 0.3435	2.1709 +/- 0.3205
125	LESS treated	-3.5295 +/- 0.2551	-4.2749 +/- 0.3435	0.7564 +/- 0.3205
125	CCL intact	-3.8410 +/- 0.2551	-3.6369 +/- 0.3435	0.7129 +/- 0.3205
135	CCL deficient	0.1695 +/- 0.2551	-5.0974 +/- 0.3435	1.4434 +/- 0.3205
135	LESS treated	-1.2750 +/- 0.2551	-4.8629 +/- 0.3435	0.9144 +/- 0.3205
135	CCL intact	-1.8000 +/- 0.2551	-4.4124 +/- 0.3435	0.6979 +/- 0.3205
145	CCL deficient	1.3810 +/- 0.2551	-4.5424 +/- 0.3435	1.5424 +/- 0.3205
145	LESS treated	0.2905 +/- 0.2551	-4.7939 +/- 0.3435	1.0579 +/- 0.3205
145	CCL intact	-0.4005 +/- 0.2551	-4.5494 +/- 0.3435	0.6869 +/- 0.3205

Table 3: Least square mean difference (x, y, z). Least squares mean difference +/- standard deviation (mm) between cranial-caudal (x), proximal-distal (y), and medial-lateral (z) tibial displacement relative to the femur for 3 testing groups and 3 testing stifle angles (higher values represent cranial displacement, lower values represent caudal displacement; higher values represent distal displacement, lower values represent proximal displacement; higher values represent medial displacement, lower values represent lateral displacement).

Stifle Angle	Treatment	Least squares mean +/- Standard Error		
		azimuth	elevation	roll
125	CCL deficient	-18.0665 +/- 6.2385	-2.2145 +/- 2.5769	1.0300 +/- 2.6787
125	LESS treated	-24.0725 +/- 6.2385	-14.8550 +/- 2.5769	0.8610 +/- 2.6787
125	CCL intact	-20.5630 +/- 6.2385	-13.9045 +/- 2.5769	0.5485 +/- 2.6787
135	CCL deficient	-17.5490 +/- 6.2385	-2.2225 +/- 2.5769	0.9480 +/- 2.6787
135	LESS treated	-21.4055 +/- 6.2385	-14.9935 +/- 2.5769	-1.6965 +/- 2.6787
135	CCL intact	-14.9515 +/- 6.2385	-13.8650 +/- 2.5769	0.1320 +/- 2.6787
145	CCL deficient	-8.1305 +/- 6.2385	-2.6680 +/- 2.5769	-4.3575 +/- 2.6787
145	LESS treated	-10.1435 +/- 6.2385	-13.6140 +/- 2.5769	-4.0575 +/- 2.6787
145	CCL intact	-3.2765 +/- 6.2385	-12.6415 +/- 2.5769	0.6780 +/- 2.6787

Table 4: Least square mean difference (azimuth, elevation, roll). Least squares mean difference +/- standard deviation (degrees) between extension-flexion of the stifle (azimuth), internal-external rotation of the stifle (elevation), and varus-valgus of the stifle (roll) for 3 testing groups and 3 testing stifle angles (higher values represent extension, lower values represent flexion; higher values represent internal rotation, lower values represent external rotation; higher values represent varus, lower values represent valgus).

Stifle Angle	Treatment	Least squares mean difference +/- Standard Error (p)		
		x	y	z
125	CCL deficient	1.0145 +/- 0.1900 (<0.0001)	-0.4790 +/- 0.4012 (0.4598)	1.4145 +/- 0.4197 (0.0031)
125	CCL intact	1.3260 +/- 0.1900 (<0.0001)	-1.1170 +/- 0.4012 (0.0177)	1.4580 +/- 0.4197 (0.0022)
125	LESS treated	0.3115 +/- 0.1900 (0.2335)	-0.6380 +/- 0.4012 (0.2549)	0.04350 +/- 0.4197 (0.9941)
135	CCL deficient	1.4445 +/- 0.1900 (<0.0001)	-0.2345 +/- 0.4012 (0.8287)	0.5290 +/- 0.4197 (0.4212)
135	CCL intact	1.9695 +/- 0.1900 (<0.0001)	-0.6850 +/- 0.4012 (0.2078)	0.7455 +/- 0.4197 (0.1833)
135	LESS treated	0.5250 +/- 0.1900 (0.0182)	-0.4505 +/- 0.4012 (0.5025)	0.2165 +/- 0.4197 (0.8638)
145	CCL deficient	1.0905 +/- 0.1900 (<0.0001)	0.2515 +/- 0.4012 (0.8058)	0.4845 +/- 0.4197 (0.4834)
145	CCL intact	1.7815 +/- 0.1900 (<0.0001)	0.007000 +/- 0.4012 (0.9998)	0.8555 +/- 0.4197 (0.1089)
145	LESS treated	0.6910 +/- 0.1900 (0.0012)	-0.2445 +/- 0.4012 (0.8153)	0.3710 +/- 0.4197 (0.6518)

Table 5: Comparisons of treatment (x, y, z). Simple effect comparisons of treatment on least squares mean difference (mm) between cranial-caudal (x), proximal-distal (y), and medial-lateral position of the tibia relative to the femur (z) by stifle angle.

Stifle Angle	Treatment	Least squares mean difference +/- Standard Error (p)		
		azimuth	elevation	roll
125	CCL deficient	6.0060 +/- 5.9200 (0.5693)	12.6405 +/- 1.5355 (<.00001)	0.1690 +/- 2.7528 (0.9979)
125	CCL intact	2.4965 +/- 5.9200 (0.9067)	11.6900 +/- 1.5355 (<.00001)	0.4815 +/- 2.7528 (0.9833)
125	LESS treated	-3.5095 +/- 5.9200 (0.8243)	-0.9505 +/- 1.5355 (0.8100)	0.3125 +/- 2.7528 (0.9929)
135	CCL deficient	3.8565 +/- 5.9200 (0.7920)	12.7710 +/- 1.5355 (<.00001)	2.6445 +/- 2.7528 (0.6032)
135	CCL intact	-2.5975 +/- 5.9200 (0.8994)	11.6425 +/- 1.5355 (<.00001)	0.8160 +/- 2.7528 (0.9527)
135	LESS treated	-6.4540 +/- 5.9200 (0.5222)	-1.1285 +/- 1.5355 (0.7433)	-1.8285 +/- 2.7528 (0.7847)
145	CCL deficient	2.0130 +/- 5.9200 (0.9383)	10.9460 +/- 1.5355 (<.00001)	-0.3000 +/- 2.7528 (0.9935)
145	CCL intact	-4.8540 +/- 5.9200 (0.6915)	9.9735 +/- 1.5355 (<.00001)	-5.0355 +/- 2.7528 (0.1648)
145	LESS treated	-6.8670 +/- 5.9200 (0.4796)	-0.9725 +/- 1.5355 (0.8021)	-4.7355 +/- 2.7528 (0.2021)

Table 6: Comparisons of treatment (azimuth, elevation, roll). Simple effect comparisons of treatment on least squares mean difference (degrees) between extension-flexion (azimuth), internal-external rotation (elevation), and varus-valgus (roll) of the stifle by stifle angle.

Treatment	Stifle Angle	Least square mean difference +/- Standard Error (p)		
		x	y	z
CCL deficient	125	-2.6845 +/- 0.1244 (<.0001)	0.3435 +/- 0.3742 (0.6303)	0.7275 +/- 0.3918 (0.1573)
CCL deficient	125	-3.8960 +/- 0.1567 (<.0001)	-0.2115 +/- 0.4016 (0.8585)	0.6285 +/- 0.4201 (0.2975)
CCL deficient	135	-1.2115 +/- 0.1244 (<.0001)	-0.5550 +/- 0.3742 (0.3036)	-0.0990 +/- 0.3918 (0.9654)
LESS treated	125	-2.2545 +/- 0.1244 (<.0001)	0.5880 +/- 0.3742 (0.2631)	-0.1580 +/- 0.3918 (0.9144)
LESS treated	125	-3.8200 +/- 0.1567 (<.0001)	0.5190 +/- 0.4016 (0.4031)	-0.3015 +/- 0.4201 (0.7537)
LESS treated	135	-1.5655 +/- 0.1244 (<.0001)	-0.0690 +/- 0.3742 (0.9814)	-0.1435 +/- 0.3918 (0.9288)
CCL intact	125	-2.0410 +/- 0.1244 (<.0001)	0.7755 +/- 0.3742 (0.1011)	0.01500 +/- 0.3918 (0.9992)
CCL intact	125	-3.4405 +/- 0.1567 (<.0001)	0.9125 +/- 0.4016 (0.0648)	0.02600 +/- 0.4201 (0.9979)
CCL intact	135	-1.3995 +/- 0.1244 (<.0001)	0.1370 +/- 0.3742 (0.9288)	0.01100 +/- 0.3918 (0.9996)

Table 7: Comparisons of stifle angle (x, y, z). Simple effect comparisons of stifle angle on least square mean difference (mm) between cranial-caudal (x), proximal-distal (y), and medial-lateral position of the tibia relative to the femur (z) by treatment.

Treatment	Stifle Angle	Least square mean difference +/- Standard Error (p)		
		azimuth	elevation	roll
CCL deficient	125	-0.5175 +/- 5.4263 (0.9950)	0.008000 +/- 0.8077 (0.9999)	0.08200 +/- 1.9332 (0.9990)
CCL deficient	125	-9.9360 +/- 5.4263 (0.2139)	0.4535 +/- 1.0638 (0.9048)	5.3875 +/- 2.3843 (0.0658)
CCL deficient	135	-9.4185 +/- 5.4263 (0.1967)	0.4455 +/- 0.8077 (0.8459)	5.3055 +/- 1.9332 (0.0192)
LESS treated	125	-2.6670 +/- 5.4263 (0.8755)	0.1385 +/- 0.8077 (0.9839)	2.5575 +/- 1.9332 (0.3855)
LESS treated	125	-13.9290 +/- 5.4263 (0.0510)	-1.2410 +/- 1.0638 (0.4756)	4.9185 +/- 2.3843 (0.1023)
LESS treated	135	-11.2620 +/- 5.4263 (0.0998)	-1.3795 +/- 0.8077 (0.2067)	2.3610 +/- 1.9332 (0.4432)
CCL intact	125	-5.6115 +/- 5.4263 (0.5570)	-0.03950 +/- 0.8077 (0.9987)	0.4165 +/- 1.9332 (0.9747)
CCL intact	125	-17.2865 +/- 5.4263 (0.0111)	-1.2630 +/- 1.0638 (0.4632)	-0.1295 +/- 2.3843 (0.9984)
CCL intact	135	-11.6750 +/- 5.4263 (0.0844)	-1.2235 +/- 0.8077 (0.2878)	-0.5460 +/- 1.9332 (0.9570)

Table 8: Comparisons of stifle angle (azimuth, elevation, roll). Simple effect comparisons of stifle angle on least square mean difference (degrees) between extension-flexion (azimuth), internal-external rotation (elevation), and varus-valgus (roll) of the stifle by treatment.