ENDOVASCULAR TROPHOBLAST CELL BEHAVIOR IN NORMAL AND ABNORMAL PREGNANCY

by

Yasuhiro Endo

Dissertation submitted to the Faculty of the
Virginia Polytechnic Institute and State University
in partial fulfillment of the requirements for the degree of

Doctor of Philosophy

in

Veterinary Medical Sciences

Ludeman A. Eng, Chairperson

Klaus D. Elgert

Bernard F. Feldman

Hara P. Misra

Carl J. Pfeiffer

April, 1995
Blacksburg, Virginia. USA.

Key words: Endovascular trophoblast cells, Preeclampsia, M-CSF, Spiral artery

c.2

LD
5655
V856
1995
E536
c.2

ENDOVASCULAR TROPHOBLAST CELL BEHAVIOR IN NORMAL AND ABNORMAL PREGNANCY

by

Yasuhiro Endo

Committee Chairperson: Ludeman A. Eng, Ph.D.
Veterinary Medical Sciences

(ABSTRACT)

Preeclampsia is an important disease during pregnancy and causes significant maternal and fetal mortality and morbidity. Despite intense research efforts, the etiology and pathogenesis of the disease remain largely unknown.

Since placentas from preeclamptic patients are smaller than normal, and cytokine growth factors are suggested to be important in placental growth, the effects of macrophage-colony stimulating factor (M-CSF) on human trophoblast cells were examined. While term trophoblast cells did not respond to M-CSF, those from early trimester and choriocarcinoma cells showed enhanced growth after treatment. In addition, the serum level of M-CSF in hypertensive pregnant women at the second trimester were significantly lower than those of normal pregnant women. These data suggest possible roles of M-CSF in preeclampsia.

When M-CSF was administered to pregnant rats on days 8-11, rats had smaller placentas at day 12 and increased fetal resorption rate at day 20. The effects of interleukin-12 (IL-12) was also examined on days 8-11. While placental development was normal at both days 12 and 20, fetuses were significantly smaller at day 20.

To remedy the difficulties and dangers associated with obtaining human placentas, I characterized endovascular trophoblast cell behavior in pregnant rats. In normal

pregnancy, rat trophoblast cells simulated all features of human endovascular trophoblast behavior including selective invasion into the spiral arteries, retrograde migration, embedding, and secretion of PAS-positive materials as well as "physiological changes." In pregnancy terminated with a certain type of spontaneous fetal resorption, defective endovascular trophoblast cell behavior was observed, which was similar to that reported in preeclamptic pregnancy.

Finally, the roles of cytoskeleton on trophoblast cell locomotion were investigated *in vivo* with a cytoskeleton-disrupting agent, cytochalasin B. This treatment impaired trophoblast cell invasion at day 12 and induced smaller fetuses at day 20, suggesting the importance of cytoskeleton in trophoblast movement.

In conclusion, the results suggest the importance of the use of appropriate specimens and endpoints in the study of pregnancy, and rats may serve as a suitable animal model for the study of endovascular trophoblast cell behavior with clinical relevance to preeclampsia.

ACKNOWLEDGMENTS

I would like to express my gratitude to my advisor, Dr. Eng, for his patience, encouragement and support in the completion of my doctoral program. I would also like to thank him and the other members of my committee, Drs. Elgert, Feldman, Misra, and Pfeiffer, for their guidance and assistance throughout my graduate program. Special thanks also to Dr. Keith who sitimulated my interests in preeclampsia and provided me wonderful research experiences and opportunities. Drs. Pijnenborg, Hanssen, Spitz and Van Assche gave me encouragment and excellent support while I was in Leuven. Also, I would like to thank all technical staffs for their excellent expert service. I would like to express my appreciation to the Virginia-Maryland Regional College of Veterinary Medicine, Genetics Institute Inc, and Rakuno Ikuei-kai for their financial generous support during the course of this program. Finally, I would like to thank my friends and family for being there when I needed them.

TABLE OF CONTENTS

Page

ABSTRACT ii
ACKNOWLEDGMENTS iv
TABLE OF CONTENTS v
LIST OF TABLES viii
LIST OF FIGURES ix
ABBREVIATIONS xi

PART I. INTRODUCTION

HYPOTHESES 2
LITERATURE REVIEW 3
1. Hypertension in pregnancy 3
2. Endovascular trophoblast cell invasion and 'physiological changes' 5
3. Tumor metastasis and leukocyte trafficking - relevance to trophoblast invasion - 15
4. Does a cytokine network at the maternal-fetal interface exist? 17
5. Animal models 20
6. References 25

PART II. RESULTS

CHAPTER 1. *IN VITRO* EFFECTS OF CYTOKINE GROWTH FACTORS ON TERM SYNCYTIOTROPHOBLAST CELLS ISOLATED FROM PLACENTAS OF NORMAL AND PREECLAMPTIC PREGNANT WOMEN 34
Abstract 34
Introduction 34
Materials and methods 36
Results 40
Discussion 44
References 49

CHAPTER 2. DECREASED SERUM LEVELS OF MACROPHAGE-COLONY STIMULATING FACTOR IN HYPERTENSIVE PREGNANT WOMEN AT THE 16TH WEEK OF PREGNANCY 51
Abstract 51
Introduction 51
Materials and methods 53
Results 55
Discussion 55
References 58

CHAPTER 3. ENDOVASCULAR TROPHOBLAST CELL BEHAVIOR IN NORMAL PREGNANT RATS 60
Abstract 60
Introduction 61
Materials and methods 63
Results 64
Discussion 69
References 101

CHAPTER 4. ABNORMAL BEHAVIOR OF ENDOVASCULAR TROPHOBLAST CELLS IN SPONTANEOUS FETAL RESORPTION IN RATS 105
Abstract 105
Introduction 105
Materials and methods 107
Results 108
Discussion 109
References 118

CHAPTER 5. ASSOCIATION OF MACROPHAGE-COLONY STIMULATING FACTOR TREATMENT WITH ADVERSE PREGNANCY OUTCOMES IN PREGNANT RATS 120
Abstract 120
Introduction 120
Materials and methods 122

Results 122
Discussion 124
References 130

CHAPTER 6. USE OF LOG CONCENTRATIONS OF NEGATIVE CONTROL ANTIBODIES AS A PART OF CONTROL STUDIES IN IMMUNOHISTOCHEMICAL STAINING 132
Abstract 132
Introduction 132
Materials and methods 133
Results and discussion 135
References 145

PART III. DISCUSSION

DISCUSSION 146
CONCLUSIONS 164
FUTURE DIRECTION 166

PART IV. LITERATURE CITED

LITERATURE CITED 169

VITA

VITA 181

LIST OF TABLES

Section	Table #	Page
Introduction		
I-1	Three types of trophoblast cells	15
Chapter 1		
1-1	Effects of M-CSF and GM-CSF on trophoblast cells	41
1-2	The effects of M-CSF and GM-CSF on giant cell formation of trophoblast cells	42
1-3	Relative expression of M-CSF receptors	43
1-4	M-CSF levels in supernatants from cultured trophoblast cells	43
Chapter 2		
2-1	Serum M-CSF levels at the 16th weeks of gestation	55
Chapter 5		
5-1	Results of cytokine treatment of pregnant rats	124
Chapter 6		
6-1	List of reagents used in immunohistochemistry	134
Discussion		
D-1	Three types of spontaneous fetal resorption in rats	153

LIST OF FIGURES

Section	Figure #	Page
Introduction		
I-1	Four types of placentas (Grosser classification)	6
I-2	Implantation processes	8
I-3,4	Interstitial trophoblast cell invasion (HE & anti-cytokeratin staining)	9
I-5,6	Endovascular trophoblast cell in the spiral artery	11
I-7,8	"Physiological changes" of the spiral arteries (HE & PAS staining)	12
I-9	Trophoblast cell invasiveness in normal and preeclamptic pregnancies	14
I-10	Availability of specimens in terms of clinical manifestation	21
Chapter 3		
3-1 (A-F)	Endovascular trophoblast cell behavior in the spiral arteries of pregnant rats	79
3-2 (A-G)	Morphology of endovascular trophoblast cells	84
3-3 (A-C)	Asymmetrical distribution of endovascular trophoblast cells	89
3-4 (A-E)	Leukocyte attachment to the spiral arteries	92
3-5 (A-F)	"Priming" effects of the spiral artery and morphology of GMG cells	96
3-6	Comparison of human and rat placentas	70
Chapter 4		
4-1 (A-D)	Type 2 fetal resorption	113
4-2 (A,B)	Type 3 fetal resorption	116
Chapter 5		
5-1 (A-D)	Placentas treated with M-CSF and control	127
5-2	Blood supply to the conceptus	125
Chapter 6		
6-1 (A-F)	Sections stained with various antibodies	140
Discussion		

D-1 Abnormal endovascular trophoblast cell behavior in man, rat and hamster 155

ABBREVIATIONS

BSA:	Bovine serum albumin
CAM:	Cell adhesion molecules
CB:	Cytochalasin B
CSF:	Colony stimulating factor
DAB:	3,3'-diaminobenzidine tetrahydrochloride
DMSO:	Dimethyl sulfoxide
ELISA:	Enzyme linked immunosorbent assay
FCS:	Fetal calf serum
GM-CSF:	Granulocyte macrophage colony stimulating factor
GMG:	Granulated metrial gland cells
Ig:	Immunoglobulin
IL-12:	Interleukin-2
IL-12:	Interleukin 12
LGL:	Large granular lymphocyte
M-CSF:	Macrophage colony stimulating factor
MTT:	3-[4,5-dimethylthiazol-2-yl]-2,5-diphenyl- tetrazolium bromide
PAS:	Periodic acid Schiff
PBS:	Phosphate buffered saline
PE:	Preeclampsia
PGI_2:	Prostacyclin
PIH:	Pregnancy induced hypertension
rh:	recombinant human
TBS:	Tris buffered saline
TNFα:	Tumor necrosis factor α
TxA_2:	Thromboxane A2

PART I

INTRODUCTION

HYPOTHESES

Overall hypotheses:

The hypotheses to be tested in this research were: (1) that trophoblast cells obtained from placentas of normal and abnormal pregnant women respond to growth factors differently and, (2) that pregnant rats can be used to better understand trophoblast cell behavior and physiological changes of the spiral arteries.

Specific hypotheses:

(1) The *in vitro* responses of trophoblast cells isolated from preeclamptic patients to cytokine growth factors are different from those from normal patients.

(2) The secretion of M-CSF from *in vitro* trophoblast cells obtained from preeclamptic patients is different from that of normal pregnant women.

(3) The expression of M-CSF receptors on term trophoblast cells *in vitro* is less than that seen on JEG-3 choriocarcinoma cells.

(4) Serum levels of M-CSF are different between normotensive and preeclamptic pregnant women.

(5) The distribution of M-CSF in placental beds is different between normotensive and preeclamptic pregnant women.

(6) IL-12 distributes in human placental beds.

(7) The behavior of rat endovascular trophoblast cells is similar to that of humans.

(8) Rat endovascular trophoblast cell invasion *in situ* is impaired by cytochalasin B treatment.

(9) M-CSF and IL-12 treatment affect pregnancy outcomes and endovascular trophoblast cell behavior in rats.

LITERATURE REVIEW

1. Hypertension in pregnancy

1-1. General

Preeclampsia or hypertension in pregnancy is a disease unique to humans and one of the leading causes of maternal and perinatal mortality and morbidity during pregnancy.[1] Approximately 350,000 cases of preeclampsia occur annually in the United States.[2] Since there is still no rational treatment protocol, the only therapeutic modality available is bed rest and prompt delivery. The latter is responsible for significant neonatal mortality and morbidity due to preterm delivery.[3] The maternal disease generally resolves rapidly without any treatment in a few days after delivery.

1-2. Clinical signs and diagnosis

Classically, preeclampsia is characterized by sequential development of hypertension, proteinuria and peripheral edema after the 20th week of gestation, and is classified based on the severity of proteinuria and hypertension. However, these signs are considered to be the secondary, and not the primary, pathological conditions.[4] A patient with the above clinical manifestations may progress to a seizure-like state. She is then said to have eclampsia, in which both the mother and fetus portend the possibility of death in the most severe case, though generally this is dependent on the gestational stage of pregnancy.

1-3. Etiology and Pathogenesis

Recently, alterations of various local and/or systemic mediators such as oxygen free radicals[5], prostaglandins[6], nitric oxide[7] and tumor necrosis factor α (TNFα)[8] have been demonstrated in sera of preeclamptic pregnant women. These alterations are

proposed as factors that may link the placental hypoxia to the systemic manifestation of the disease. In addition, cytotoxic factors have been proposed to exist in preeclamptic sera and to mediate the endothelial cell damage seen in this syndrome.[9] However, these factors are also considered to be the secondary, not the primary, pathological events, or perhaps the links between the primary and secondary pathology.[10] At present, both etiology and pathogenesis are incompletely characterized and controversial. Accordingly, despite intensive research efforts, little improvement has been made in early detection, diagnosis, prevention, and treatment of the disease although, because of improved obstetric care in general, outcomes of preeclamptic pregnancy have improved in the past few decades.

1-4. Pathology

In preeclamptic pregnancy, the kidney and placenta show characteristic morphological abnormalities. In the kidney, microscopic lesions are confined to the glomeruli where capillary endothelial cells swell and vacuolate. This change is known as glomerular capillary endotheliosis, the severity of which tends to correlate with the severity of the disease.[11,12] The cause of this morphological change is unknown.

The placenta is divided into two parts: villi consisting entirely of fetal cells, and placental beds containing both maternal and fetal cells. The major pathological change in the villi is an occasional syncytial sprout and an increased number of cytotrophoblast cells.[13] Since similar alterations are observed when villi were incubated under a hypoxic state *in vitro*,[14,15] these morphological changes are ascribed to placental hypoxia shown to occur in preeclamptic pregnancy.[16,17] In contrast to relatively mild changes in the villi, there are many characteristic morphological alterations in the placental beds of preeclamptic patients. Among them, inappropriately shallow invasion of endovascular trophoblast cells and failure of spiral artery remodeling are the earliest and the most

characteristic abnormalities in this disease.[18,19] The characterization of endovascular trophoblast cell behavior is one of the major topics in this investigation. Another common vascular pathology is acute atherosis originally discovered by Hertig,[20] in which foam cells are present in the damaged necrotic vessel walls and lipid accumulate in the intima.[21,22] The lesions are similar to atheroma but different in two aspects: acute atherosis contains more plasma components and undergoes spontaneous necrosis.[23] In pregnant women with preeclampsia superimposed on established hypertension, the spiral arteries may undergo arteriosclerosis to a degree usually not seen in women of reproductive age.[23]

Thus, the most important and characteristic changes and abnormalities in preeclamptic women are seen in placental beds. Therefore, the study of placental beds, particularly abnormal behavior of endovascular trophoblast cells reported in all preeclamptic patients, appears to be critical to better understand this disorder.

In the following sections, the sequential events of placentation in humans will be described beginning from implantation through term. Detailed descriptions will be provided on endovascular trophoblast cell behavior and resulting "physiological changes" of the spiral arteries.

2. Endovascular trophoblast cell invasion and "physiological changes"

2-1. Definition of the placenta

"An intimate apposition between parental and fetal tissues for the purpose of physiological exchange."

This definition is the most widely accepted and elegant definition of "placentas."[24] To achieve the goal described, depending on species, there are several types of placentas based on the degree of apposition; namely epitheliochorial, syndesmochorial, endotheliochorial and hemochorial. In the epitheliochorial placenta, trophoblast cells do not invade the maternal uterine epithelium, thus all three maternal layers (epithelium, connective tissues and endothelium) are intact. Placentas of pigs and horses belong to this type. In the syndesmochorial placenta, trophoblast cells destroy the uterine epithelium and make contact with the endometrial stroma but not with endothelial cells. Ruminants such as sheep have this type of placentas. The endotheliochorial placenta has further invasion of trophoblast cells into the maternal tissues. As a result, the chorion makes a direct contact with the maternal capillary endothelium. Carnivores such as cats have this type of placenta. The hemochorial placenta represents the most close association between the mother and fetuses since trophoblast cells are directly perfused by maternal blood without the intervention of other cells. Placentas of primates (including humans) and rodents are hemochorial (Figure I-1).

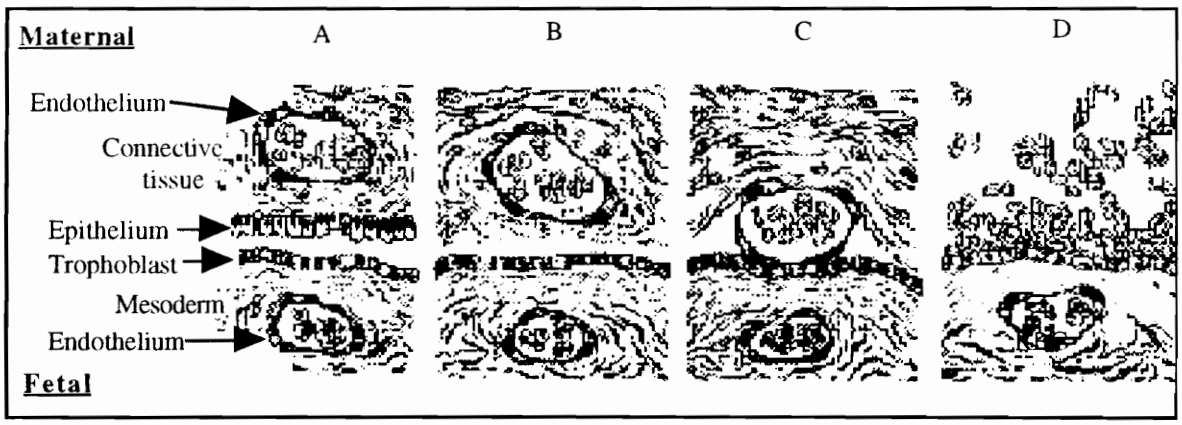

Figure I-1. A schematic representation of the tissue layers composing the various types of placentas. A: Epitheliochorial, B: Syndesmochorial, C: Endotheliochorial, D: Hemochorial (Grosser classification). (From Rosenfeld (ed). The uterine circulation. Perinatology Press, Ithaca, NY. p277).

2-2. Implantation

After fertilization, a conceptus grows rapidly and three layers of cells (endoderm, mesoderm and ectoderm) are formed. Among them, trophoblast cells are the outermost layer of the blastocyst, and hence are of epithelial cell origin, and the only cell population that is directly in contact with the maternal blood throughout pregnancy. Through the interaction between trophoblast cells and maternal tissues, hemochorial placentas are formed.

In humans, following implantation, trophoblast (more accurately primitive syncytiotrophoblast) cells aggressively digest cells beneath the uterine epithelial cell layer and start to invade maternal tissues. Because of this, blastocysts are completely embedded in the uterine endometrium until around day 10. Then, trophoblast cells continue to digest the superficial part of the endometrium and create numerous lacunar and sinusoidal spaces around the blastocyst where maternal blood starts to perfuse (Figure I-2). Attachment of the blastocyst to maternal tissues is gradually restricted mainly to growing 'primary' villi or anchoring villi. This outermost part of the trophoblast cell population serves as the source of extravillous trophoblast cells that invade deep into maternal tissues in the subsequent periods of pregnancy. Trophoblast cells that stay on the surface of villi form a thin layer of multinucleate cells called syncytiotrophoblasts. This trophoblast cell layer separates maternal and fetal circulation and plays the major role in transferring O_2 and nutrients from the mother to the fetus, and CO_2 and waste materials in the opposite direction. This process is called "physiological exchange" by Mossman.[24]

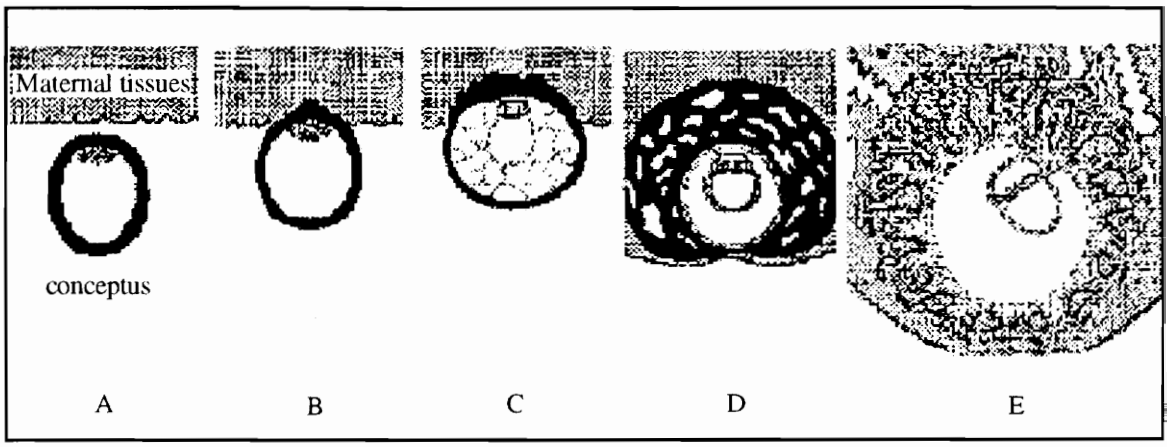

Figure I-2. At the left, a conceptus has not yet implanted (A). The conceptus just attached to the maternal uterine epithelium (=implantation) (B) and start to invade the maternal tissues (C). The outer layer (black) consists of trophoblast cells. Until around day 10 of pregnancy, the conceptus is completely embedded in the uterine tissues (D). Thereafter, trophoblast cells gradually migrate into the maternal tissues both endovascularly and interstitially (E). (Modified from Boyd and Hamilton. The human placenta. Heifer, Cambridge. 1970)

2-3. Interstitial trophoblast cell invasion

Apart from the syncytiotrophoblast cells described above, there are two types of trophoblast cells that invade the maternal portion of placentas or so called placental beds. Since they are exclusively derived from the proliferating tips of anchoring villi and leave from there, they are called extravillous trophoblast cells. One type, interstitial trophoblast cells, migrate through the endometrial stroma (the decidua basalis and the inner part of the myometrium) (Figure I-3 and 4).[25] At some point, they form multinucleate giant cells and are called giant trophoblast cells.[26] Recently much has been learned about this process. In brief, the invasive activity of interstitial trophoblast cells appears to be in part a function of secretion of proteolytic enzymes such as metalloproteinase[27,28] and temporal expression of integrins on trophoblast cells.[29,30] The function of interstitial trophoblast cells is yet to be elucidated although 'priming' of a myometrial portion of placental spiral

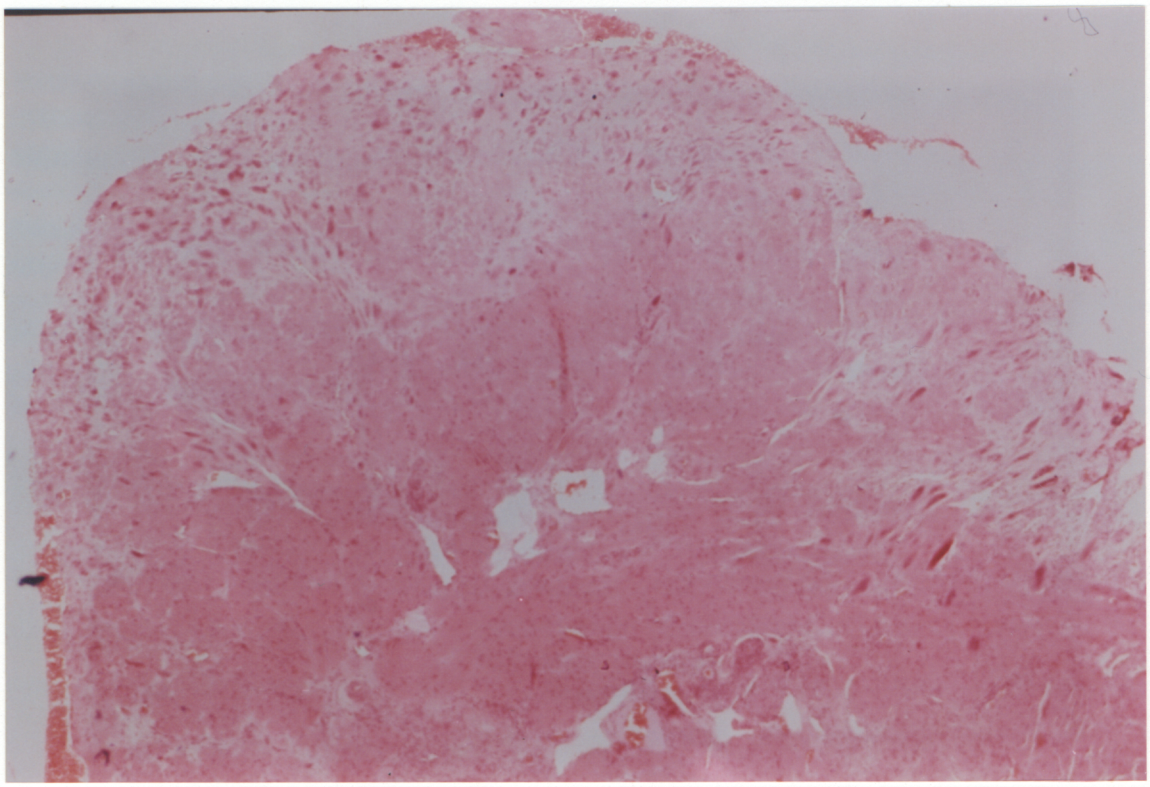

Figure I-3. Interstitial trophoblast cells invading the the placental bed. (x 80) HE staining.

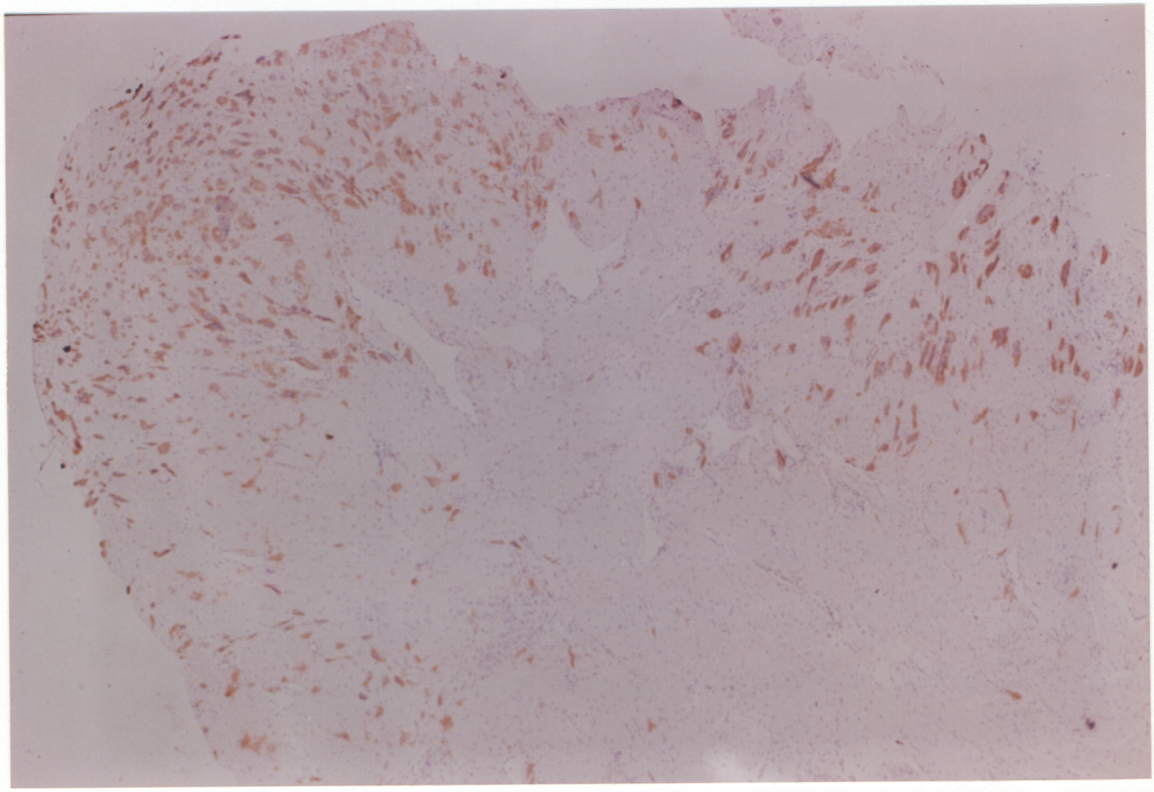

Figure I-4. Anti-cytokeratin antibody staining of the serial section of the above. (x 80)
(Counter-stained with Harris hematoxylin)

arteries has been suggested.[31] In addition, recently many cytokines have been immunohistochemically localized in this cell type. Therefore, these cells may be involved in putative cytokine cross-talks at the maternal-fetal interface.[32]

2-4. Endovascular trophoblast cell invasion

The other type of trophoblast cell, the endovascular trophoblast selectively taps into the spiral arteries and migrates along the lumen of vessels, against the flow of blood (Figure I-5). The idea was not initially acepted that large cells on the surface of the maternal arteries were trophoblast cells they (because endovascular trophoblast cells) are distant from the placental villi. In the late 1960's and early 1970's, the origin of endovascular trophoblast cells and their retrograde movement in the arteries were suggested based on the study of serially cut placental bed sections,[33,34] and later confirmed as fetally-derived based on chromatin characteristics[35] and electron microscopic studies.[36,37] They continue to move up to the inner one third of the myometrium portion of the spiral arteries (Figure I-6) and sometimes even to the terminal segments of the radial arteries.[38] At some point, these endovascular trophoblast cells start to extravasate and become embedded into the vessel wall. The invaded spiral arteries lose their musculature, which is replaced by fibrinoid material (Figures I-7 and 8). Embedded trophoblast cells are considered to be a primary source of these materials.[39] Having lost resistant components (muscle and elastic lamina), the spiral arteries are transformed into markedly distended tortuous uteroplacental arteries. Brosens et. al. coined the term "physiological changes" to describe these processes.[40] By the end of the second trimester, almost all placental spiral arteries are converted to uteroplacental arteries.[41] Since the uteroplacental arteries now possess no muscular component and are devoid of sympathetic control,[18,41] with enhanced flow of blood to the intervillous space, the mother

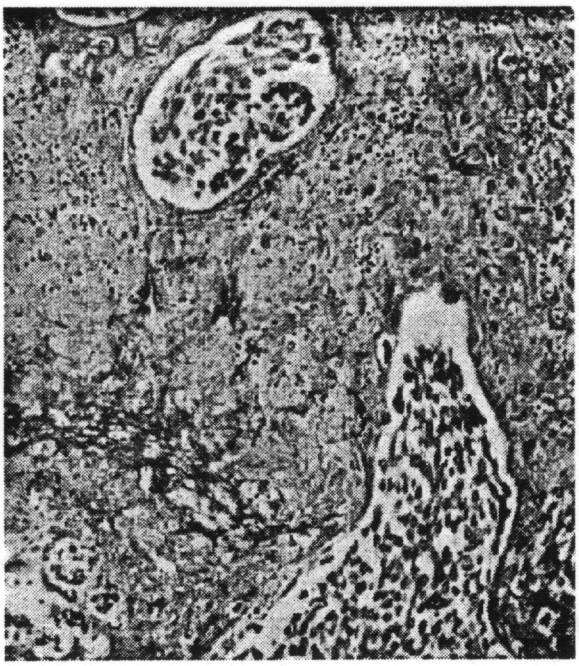

Figure I-5

From Boyd, Hamilton, The human placenta. Heifer and Son Co. Cambridge, 1970

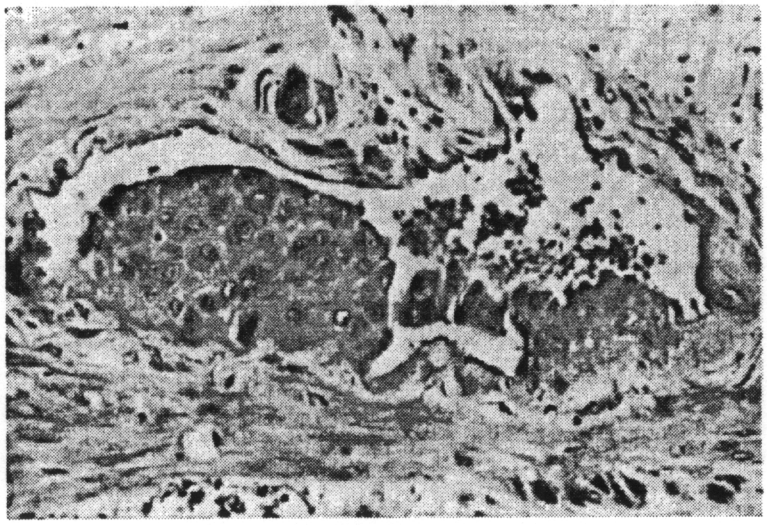

Figure I-6

From Pijnenborg et. al. Placenta. 1983;4:397-414.

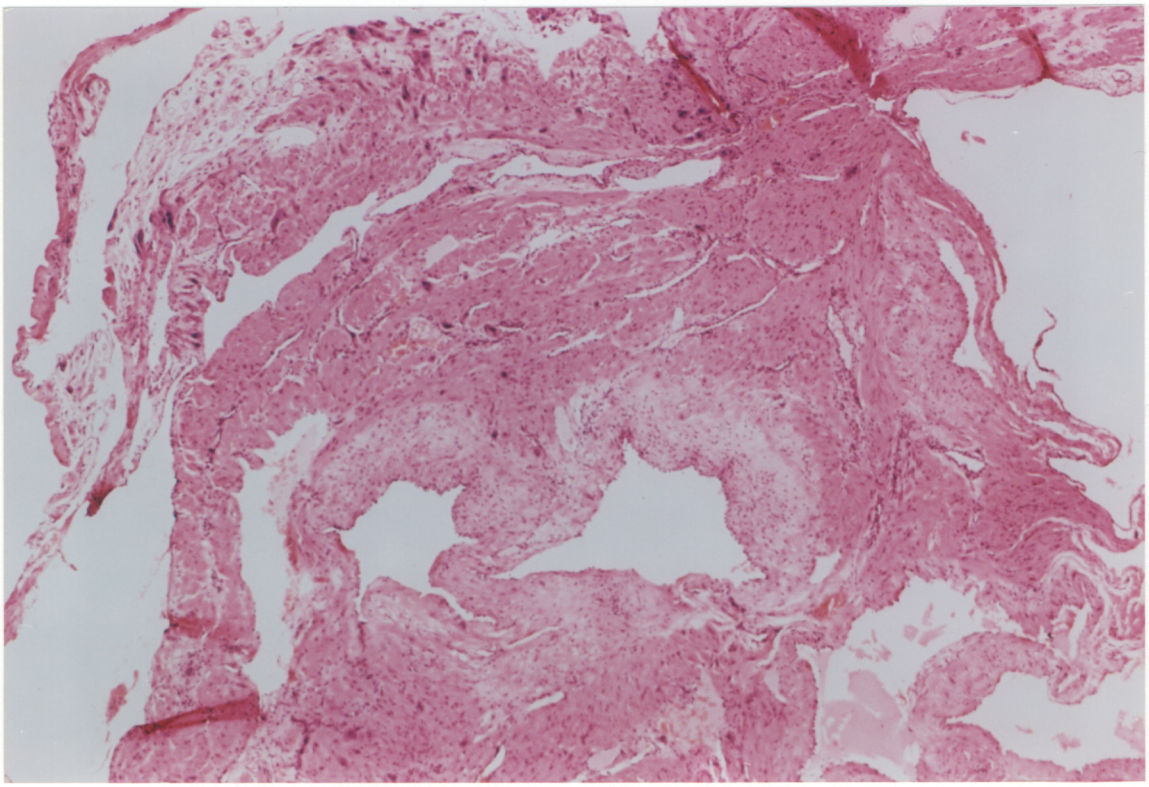

Figure I-7. Uteroplacental artery (center) showing extreme dilation and loss of normal structure. (x 80) HE staining.

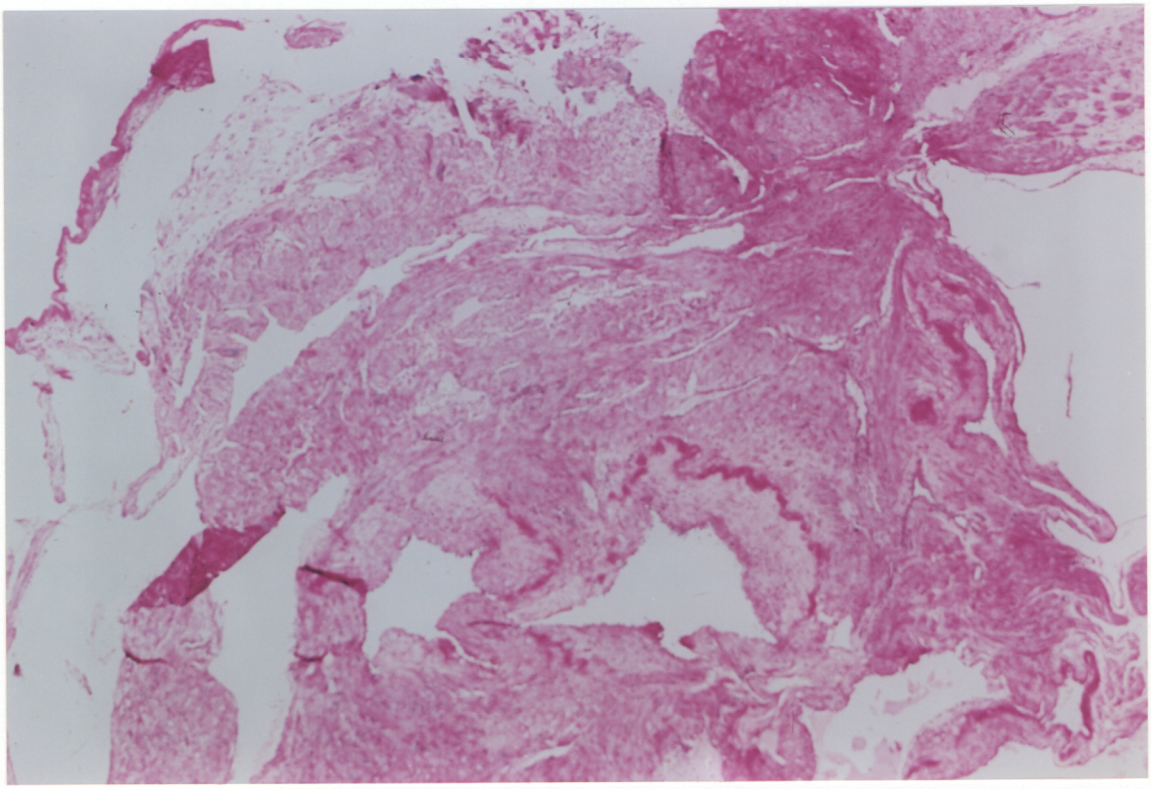

Figure I-8. PAS staining of the serial section of the above. The same artery has a layer of PAS positive materials. (x 80)

can provide more O_2 and nutrients to meet the increasing demands from the developing fetus later in pregnancy.[42]

Radial arteries give rise to two types of terminal branches: basal and spiral arteries. It is important to note that one of them, basal arteries, do not receive trophoblast cell invasion, hence incur no "physiological changes" even in normal pregnancy. The major difference between spiral and basal arteries is their diameters, being of an external diameter greater than 200 μm and less than 120 μm, respectively.[18] This poses a great difficulty in assessing the presence or absence of physiological changes in the spiral arteries, and is a cause of much confusion in interpreting placental bed morphology.[43]

Although endovascular trophoblast cells thus invade selectively into and interact with the spiral arteries, their superficial invasion into the veins has been observed in macaques, and suggested in humans.[44] However, the venous invasion is in general very shallow and "physiological changes" equivalent to the spiral arteries have not been reported. Therefore, fundamentally different mechanisms may operate in the interaction of trophoblast cells with the spiral arteries and veins. In general, venous invasion is viewed as physiologically less important.

It is important to note that "physiological changes" are a function of endovascular trophoblast cells, not interstitial trophoblast cells. Interstitial trophoblast cells do not invade the spiral arteries from the outside of the vessel walls, although they frequently surround the spiral arteries but remain in the adventitial layers. Sometimes, they may be passively incorporated into fibrionid materials. This is the most confusing aspect of the invasive pathways of extravillous trophoblast cells.

The above two processes of trophoblast cell invasion (interstitial and endovascular) are considered to diminish by the end of the second trimester.[38] Thereafter, reparative processes start to operate in some of the invaded arteries. As a result, endothelial cells are re-established (so called re-endothelialization), along with

accumulation of inflammatory cells. These changes occur in both normal and abnormal pregnancies.

It is important to emphasize that in preeclamptic pregnancy, only endovascular trophoblast cell invasion is suppressed: the depth of interstitial trophoblast cell invasion is considered to be normal (Figure I-9).[45] Some even consider that preeclamptic placental beds contain more giant cells.[46] Since endovascular trophoblast cells are derived directly from extravillous trophoblast cells, not from interstitial trophoblast cells, endovascular trophoblast cell behavior is the major abnormality in preeclamptic pregnancy. Therefore, the study of endovascular trophoblast cells rather than interstitial trophoblast cells appears essential to understanding this disorder. Recently, some consider that in preeclamptic pregnancy, invaison of extravillous trophoblast cells (both endovascualr and interstitial) are impaired. Their misconception appears to be based on the assumption that endovascular trophoblast cells are derived from interstital trophoblast cells and the lack of criteria to confirm the origin of tissue materials.[47]

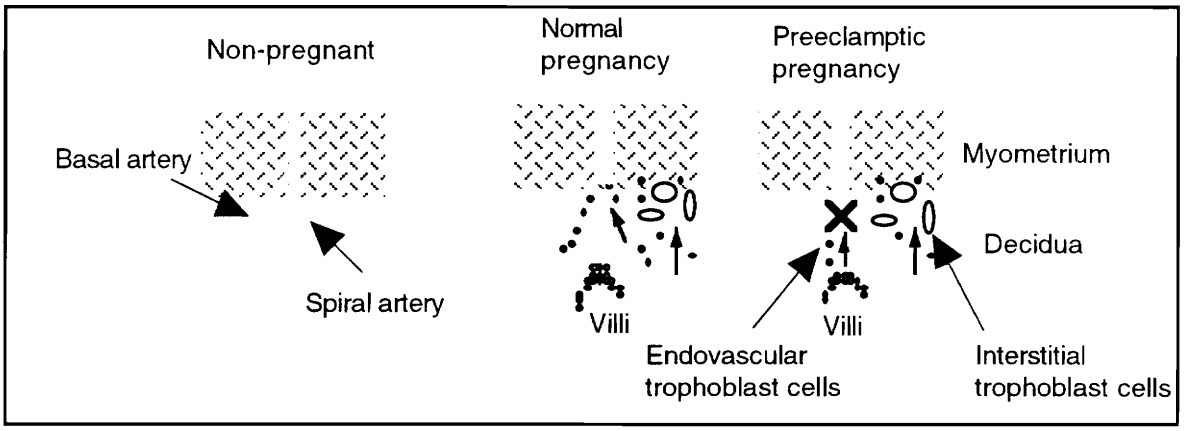

Figure I-9. In preeclamptic pregnancy, only endovascular trophoblast cell invasiveness is suppressed. In contrast, interstitial trophoblast cells invade the maternal tissues normally.

In summary, there are three types of trophoblast cells: (1) syncytiotrophoblast cells which line the placenta and serve as a physical barrier between the mother and

fetus; (2) interstitial trophoblast cells which invade the uterine interstitial space and are considered to participate in creating placental milieu; and (3) endovascular trophoblast cells which modify the arterial vasculature physically to help build infrastructures to provide more nutrition and O_2 to the growing fetus (Table I-1). Little is known about factors that control trophoblast cell behavior and 'physiological changes.'

Table I-1. Three types of trophoblast cells

Cell types	Location	Major functions
Syncytiotrophoblast cells	Villi	Physical barrier between the maternal and fetal circulation
Interstitial trophoblast cells including giant cells	Interstitial space (decidua basalis and myometrium)	Creating placental milieu ?
Endovascular trophoblast cells	Placental spiral arteries	'Physiological changes'

3. Tumor metastasis and leukocyte trafficking - Relevance to trophoblast cell invasion

As described above, endovascular trophoblast cells attach to and interact with the endothelium of selected vessels and extravasate. Since similar phenomena occur in leukocyte trafficking[48] and tumor metastasis,[49] by comparing the interaction of leukocytes and metastasizing tumor cells with endothelial cells and endovascular trophoblast cells, important insights may be obtained regarding the underlying principles of endovascular trophoblast cell behavior.

3-1. Tumor metastasis

Although some metastases appear to be dependent on anatomical location of the primary tumor and the hemodynamic consequence, many of them are apparently site-specific. To explain site-specificity of tumor metastasis, 'the seed and soil' hypothesis was introduced more than a century ago by Paget,[50] in which organ predilection of some

metastases is the consequence of the provision of a fertile environment (*the soil*) in which compatible tumor cells (*the seed*) could proliferate. This hypothesis was later supported by Weiss who suggested tumor cells identified specific vascular beds during their travel in the circulation.[51] It is by the recognition of adhesion molecules on the endothelium that tumor cells settle in specific tissues.[52,53]

3-2. Leukocyte trafficking/homing

Similar to tumor metastasis, leukocyte trafficking is, in general, controlled in several ways: (1) cell lineage specific migration; (2) preferential homing of memory cells to tissues related to the ones that were previously stimulated; and (3) loss of the selectivity that governs normal homing due to inflammation.[49] In short, the adhesion of leukocytes to endothelial cells requires regulated expression of molecules on both the endothelial cell and the leukocytes.[54,55] These proadhesive molecules are called cell adhesion molecules (CAM) and have diverse structures and mechanisms of expression.[56]

Because of site-specific expression of adhesion molecules, administration of anti-CAM antibodies prevents or ameliorates various diseases including tumor metastasis and autoimmune diseases as well as suppressing allograft transplantation reaction in humans[57,58] and animals,[59,60] suggesting that adhesion molecules could become a therapeutic target for abnormalities in cell-to-cell contact.

3-3. Expression of cell adhesion molecules in placental beds

The fact that endovascular trophoblast cells attach only to the spiral arteries but not to basal arteries and venules nor any other vessels in the maternal circulation, suggests that spiral arteries express specific receptors *("the soil")* for trophoblast cells *("the seed").* Indeed, recent evidence demonstrated that spiral arteries of human placental beds at the first trimester differentially express E- and P-selectins[61] and that trophoblast cells express their ligand, the blood group-related carbohydrate antigen (sialyl Le^x) in

normal pregnancy.[62] Thus, these findings suggest a similarity of underlying mechanisms between leukocyte trafficking/homing, some tumor metastasis, and trophoblast cell invasion.

4. Does a cytokine network exist at the maternal-fetal interface?

Cytokines provide important communication systems in coordinating immune and inflammatory responses. Although they were originally assumed to be cell lineage-specific and named according to their major target cells (for example, M-CSF for macrophage-colony stimulating factor), recently they are demonstrated to be pleiotropic and to have overlapping activities. Consistent with this, various cytokines localize at organs other than those of the immune system, including the human endometrium and placentas.

4-1. Macrophage-colony stimulating factors (M-CSF)

Among many cytokines, M-CSF, a glycoprotein with a molecular weight of approximately 90kD is considered to be important at the maternal-fetal interface. The possible roles of M-CSF in the female reproductive system were first demonstrated in pregnant mice. Pollard et al. demonstrated that the concentration of M-CSF increased a thousand-fold in the first few days of pregnancy,[63] and its receptors were present on decidual cells, trophoblast cells and macrophages.[64] In addition, both M-CSF and granulocyte macrophage-colony stimulating factor (GM-CSF) prevented spontaneous abortion when injected to an abortifacient strain of mice, and produced increased placental and fetal weight.[65,66] Finally, *op/op* mice, which lack M-CSF, can not reproduce.[67]

Similar to mice, M-CSF and its receptors are demonstrated immunohistochemically in human placentas.[68,69] Maternal cells that produce M-CSF during pregnancy are considered to be the glandular and luminal epithelial cells as well as cells lining the blood

vessels within the endometrium.[70] In the placenta, M-CSF is localized in both extravillous trophoblast and syncytiotrophoblast cells in the first and second trimester. By the third trimester, placental M-CSF expression is restricted to cells lining fetal vessels in villi.[70] In addition to M-CSF, its receptors are localized in the glandular epithelium, luminal epithelium and decidual cells in the maternal part of placentas. They also are localized in extravillous trophoblast and syncytiotrophoblast cells.[71] The concentrations of M-CSF are reported to be higher than those of non-pregnant women and increase with gestation.[72] Moreover, M-CSF is reported to have growth and/or giant cell formation promoting activities on trophoblast cells *in vitro*.[69,73] These data suggest that M-CSF has important physiological roles in human pregnancy.

Thus, the above data strongly suggest the involvement of some of the CSF family of molecules on placental biology. However, there are conflicting reports: when a high dose of M-CSF was administered to certain strains of pregnant mice, fetal resorption rates increased prominently.[74] Moreover, recently, Drake and Head[75] did not observe known growth-promoting effects of M-CSF on trophoblast cells obtained from the middle of mouse pregnancy after they critically re-evaluated the methodology of *in vitro* proliferation assays used by other investigators so far. In addition, localization of M-CSF receptors are totally conflicting between two groups.[71,76] Thus, although a role for M-CSF during pregnancy is strongly suggested, its exact activity remains to be elucidated.

4-2. Large granular lymphocytes (LGL) -an NK cell lineage?

The decidua, a maternal part of the placenta, is rich in bone-marrow derived cells whose primary function is considered to be immune regulation at the maternal-fetal interface. At the time of implantation, lymphoid and myeloid cells start to infiltrate the endometrium/decidua.[77 78] The major cell population in the decidual basalis in the first trimester is LGL, which is considered to be natural killer (NK) cell lineage based on surface

phenotypes.[79] This decidual subset of LGL expresses a set of surface markers ($CD3^-/CD16^-/CD56^+$).[80] This class of LGL comprises less than 2% of peripheral blood but 70% of bone marrow cells in the decidua in the first trimester. The function of decidual LGL *in vivo* is under debate although many functions such as protection against invading trophoblast cells[81,82] or infection,[83] and the production of cytokines[84] are suggested. Among them, cytotoxic activity has received intense attention since an increased number of LGL in the decidua is demonstrated in women with incipient abortion.[85] Also, administration of interleukin-2 (IL-2), an NK cell activator increased fetal resorption rate in mice.[86]

4-3. Interleukin-12 (IL-12)

At present, there are no data regarding the involvement of IL-12 in pregnancy. However, if LGL are of NK cell origin, IL-12, an NK cell activator may have some roles in maintaining pregnancy. IL-12 was originally isolated from B lymphoblastoid cell lines,[87] but the majority of IL-12 is produced by macrophages/monocytes.[88] This cytokine is a heterodymeric cytokine which has been shown to cause the proliferation of activated T cells and NK cells, to enhance the lytic activity of NK cells, and to induce the production of cytokines.[89] Since placentas also contain many macrophages, the study of IL-12 may reveal some new insights regarding the roles of LGL/GMG cells and this new cytokine in pregnancy.

5. Animal models

5-1. Advantage to use whole animal models for the study of endovascular trophoblast cell behavior

Pregnancy is an epiphenomenon, in which placentas grow rapidly under dynamic continuous flux and the mother launches various physiological adjustments throughout pregnancy. Therefore, changes which may be considered to be pathological in non-pregnant states are not always pathognomic during pregnancy, particularly at placental beds. The best example is "physiological changes" of the spiral arteries, in which the spiral arteries are gradually transformed to uteroplacental arteries during the course of pregnancy. Thus, the significance of utilizing appropriate placental materials cannot be over emphasized.

5-1-1. Difficulties associated with obtaining human specimens

Since the invasive activity of endovascular trophoblast cells into the placental spiral arteries is considered to occur at around four weeks of gestation. Most of them are largely diminished by the end of the second trimester. Therefore, the use of specimens encompassing that time period is crucial. However, because of the on-going nature of pregnancy, controlled placental bed specimens are virtually impossible to obtain from both normal and abnormal pregnant women. In addition, even when early placental bed specimens are available, we can not tell which one is normal or preeclamptic. This is because of the fact that there is no reliable method to diagnose or predict preeclampsia until the mother develops clinical signs which is the 20th week of gestation in the earliest case (Figure I-10). Furthermore, collection of early specimens is not justified ethically since the majority of preeclamptic patients are successfully managed symptomatically.

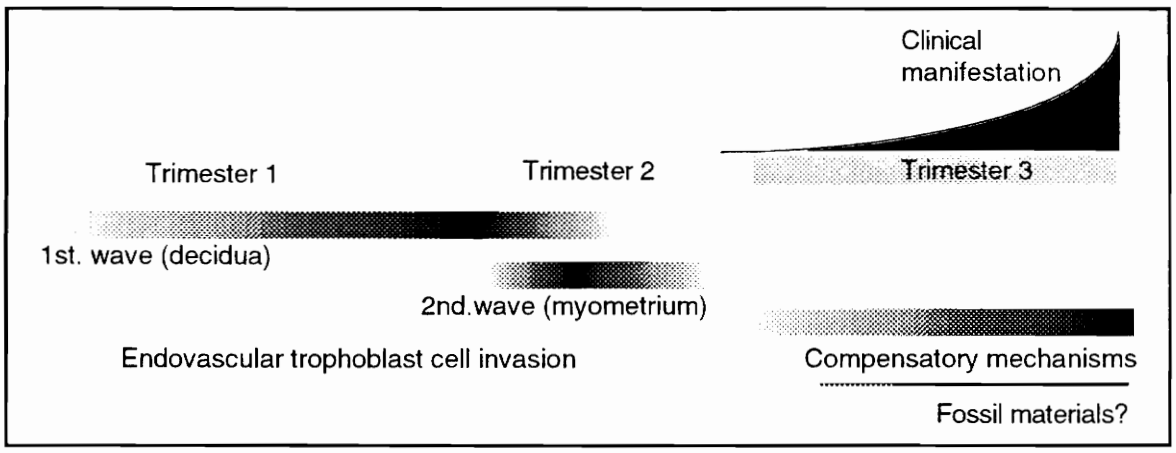

Figure I-10. The 1st. wave of endeovascular trophoblast cell invasion into the decidual part occurs during the 1st. trimester. The 2nd. wave into the myometrial part occurs from the 16th week to the end of 2nd trimester. When endovascular trophoblast cells fail to invade, the mother develops compensatory mechanisms, which lead to clinical manifestation at the 3rd. trimester. Available placental bed specimens are mostly those obtained at delivery, and presumed to be a kind of fossil material for the study of endovascular trophoblast cell behavior by some placental morphologists.

5-1-2. Difficulties of conducting *in vivo* funcitonal studies in humans

Needless to say, because of ethical considerations, no functional studies are allowed which may adversely affect pregnancy outcomes in humans. Therefore, functional studies are strictly limited to *in vitro* by utlilizing trophoblast cells isolated from the fetal part of placentas. However, in preeclamptic pregnancy, as emphasized previously, it is only those trophoblast cells that invade the spiral arteries which show abnormal behavior. However, most studies in preeclampsia have been conducted utilizing syncytiotrophoblast cells. Therefore, these *in vitro* functional studies have inherent difficulties in the interpretation of data. Moreover, there is no method to isolate endovascular trophoblast cells from placentas.

Therefore, these situations have hindered the study of both normal and abnormal placentation in humans. Since these difficulties associated with the nature of pregnancy will not change in the near future, the utilization of laboratory animals is essential.

5-2. Limitations of available animal models

Thus far, several attempts have been made to establish animal models for the study of preeclampsia with varying degrees of success. However, all of them were developed to investigate the pathophysiological mechanisms of the syndrome. For example, our laboratory has developed a model of preeclampsia in sheep and has documented the beneficial effects of a thromboxane synthase inhibitor during pregnancy-induced hypertension.[90,91] This ovine model appeared valuable in the study of pathogenesis of preeclampsia and in the evaluation of treatment efficacy. However, our model was not suitable for the study of the more fundamental abnormality of preeclampsia, i.e., failure of endovascular trophoblast cell invasion and lack of physiological changes, because of the basic differences in trophoblast cell invasiveness (hemochorial in humans v.s. syndesmochorial in sheep). Until now, no model has been described for the investigation of abnormal behavior of endovascular trophoblast cells in preeclamptic pregnancy.

5-3. Placentation in rodents

Both humans and rodents have a population of proliferating trophoblast cells in the area where the mother and fetus come into contact, i.e., anchoring villi in humans and ectoplacental cone in rodents. From there, trophoblast cells invade the maternal tissues. In humans, both interstitial and endovascular trophoblast cells invade deep into the maternal tissues. On the other hand, in rodents, the invasive activity of interstitial trophoblast cells is minimal. The labyrinth in rodents is equivalent to villi in humans where

interchange of nutrients and gases between the mother and fetus occurs. Thus, there are marked differences in placental anatomy and the behavior of interstitial trophoblast cells between human and rodents.

In contrast to interstitial trophoblast cells, the existence of 'large cells' in the maternal arteries was already reported by Duval in 1891.[92] Thereafter, others[93,94,95,96] described detailed vascular changes of placental arteries during rat pregnancy and documented enlargement of the spiral arteries. However, these authors focused their attention on vascular patterns during pregnancy (such as the number of arteries and their diameter). Accordingly, detailed information regarding endovascular trophoblast cell behavior in the rat is not yet available. In contrast, endovascular trophoblast cell behavior, particularly retrograde migration, has been well characterized in the hamster, and shown to be basically the same as in humans.[97,98]

In addition to endovascular trophoblast cell invasion, in rodents, granulated metrial gland (GMG) cells, which are considered to be equivalent to decidual LGL in humans, accumulate in the placenta.[99] Similar *in vitro* activities are reported in both cell types[100,101] although the exact nature and functions of these cells are unknown. Most studies regarding GMG cells in rodents have been conducted in mice.

Thus, despite the differences in placental anatomy and gestational days, both human and rodents have endovascular trophoblast cell invasion. Therefore, rodents may be appropriate for the study of endovascular trophoblast cell behavior. As mentioned above, although hamster placentation is better characterized than rats, it was decided to examine rat placentation, particularly endovascular trophoblast cell behavior because of a greater potential for in-depth studies (see section 5-4 below). Until now, no effort has been made to compare each step of endovascular trophoblast cell behavior and "physiological changes" between human and rats. Also, few attempts have been made to modulate endovascular trophoblast cell invasiveness pharmacologically*in vivo* .

5-4. The pros and cons of using rat models

Several features of this model warrant further comment: (1) availability of genetically well-defined animals, (2) low cost, (3) standardization of experimental conditions, (4) access to ante- and postmortem samples (both placental beds and blood) and (5) short gestational periods. None of these features are available in humans.

Although these characteristics are common to many rodents, rats appear to possess distinct advantages over mice and hamsters. First of all, mouse placentation is very complex and poorly characterized morphologically. In contrast, as mentioned above, hamster placentation is much better characterized than any other rodent including rats. However, rats have a greater potential for in-depth studies because, being the second most widely used laboratory animals, many more reagents are available for rats, including cytokines and antibodies against cell adhesion molecules. This will permit functional studies both *in vivo* and *in vitro,* which are critical to identify a molecular basis of endovascular trophoblast cell invasion. Using hamsters, these types of study are very difficult to conduct. While non-human primates more closely approximate human placentation and many reagents cross-react, the cost is prohibitive and not available to the majority of investigators. Thus, the rat was chosen as the model for this study.

However, it must be borne in mind that there are important differences between human and rat pregnancy, e.g. (1) in gestational periods [3 weeks in rats vs. 40 weeks in humans], (2) in placental anatomy, and (3) the lack of a clinical syndrome of preeclampsia in non-human animals. Because of these differences, rats may not be useful for the study of the *pathogenesis* of the syndrome. However, the rat model described in this study is designed to examine the underlying principles of endovascular trophoblast cell behavior (*etiology*), not the pathogenesis of preeclampsia. Therefore, the above differences may not diminish the usefulness of the rat model for the purpose of this study.

REFERENCES

1 Roberts JM. Pregnancy related hypertension. *In* Maternal Fetal Medicine, Creasy RK, Resnik R (eds) Philadelphia, WB Saunders, 1989.

2 Ramon de Alvarez R. *Current Obstetric and Gynecologic Diagnostics and Treatment, 5th. edition.* Lange medical publications, Los Altos, California, 1984, p. 763.

3 Facts on Infant Mortality in *Death Before Life: The Tragedy of Infant Mortality* ,The report of the national commission to prevent infant mortality. Senator Lawton Chiles, Chairman. Washington, DC, August 1988.

4 Redman CWG. The definition of pre-eclampsia. In: Hypertension in pregnancy. Sharp F, Symonds EM (ed). Ithaca, Perinatology Press. 1986. p.3-13.

5 Zeeman GG, Dekker GA. Pathogenesis of preeclampsia: a hypothesis. Clin. Obset Gynecol. 1992;35:317-37.

6 Walsh SW. Preeclampsia: an imbalance in placental prostacyclin and thromboxane production. Am J Obstet Gynecol. 1985;152:335-40.

7 Seligman SP, Buyon JP, Clancy RM, Young BK, Abramson SB. The role of nitric oxide in the pathogenesis of preeclampsia. Am J Obstet Gynecol. 1994;171:944-8.

8 Keith JC, Rowles TK, Dilorenzo K, Mishra S, Misra HP. Letter. J Perinatology. 1993;5:417-8.

9 Rodgers GM, Taylor RN, Roberts JM. Preeclampsia is associated with a serum factor cytotoxic to human endothelial cells. Am J Obstet Gynecol. 1988;159:908-14.

10 Roberts JM, Redman CWG. Pre-eclampsia: more than pregnancy-induced hypertension. Lancet. 1993;341:1447-51.

11 Spargo B, McCartney CP, Winemiller R. Glomerular capillary endotheliosis in toxemia of pregnancy. Arch Pathol. 1959;68:593-9.

12 Altchek A, Albright NL, Sommers SC. The renal pathology of toxemia of pregnancy. Obstet Gynecol. 1968;31:595-607

13 Fox H. Pathology of placenta. W.B. Saunders, Philadelphia. 1978.

14 MacLennon AH, Sharp F, Shaw-Dunn J. The ultrastructure of human trophoblast in spontaneous and induced hypoxia using a system of organ culture: a comparison with ultrastructural changes in pre-eclampsia and placental insufficiency. J Obstet Gynaecol Br Cmwlth. 1972;79:113-21.

15 Fox H. Effect of hypoxia on trophoblast in organ culture. Am J Obstet Gynecol. 1970;107:1058-64.

16 Lunell NO, Nyluna LE, Lewander R, Sarby B. Uteroplacental blood flow in preeclampsia: measurements with Indium-113M and a computer-linked gamma camera. Clin Exp Hpertens. 1982;1:105-17.

17 Fox H. The villous cytotrophoblast as an index of placental ischemia. J Obstet Gynaecol Br Cmwlth. 1964;71:885-93.

18 Brosens I, Robertson WB, Dixon HG. The role of the spiral arteries in the pathogenesis of pre-eclampsia. Obstet Gynecol Ann. 1972;1:177-91.

19 Khong TY, De Wolf F, Robertson WB, Brosens I. Inadequate maternal vascular response to placentation in pregnancies complicated by pre-eclampsia and by small-for-gestational-age infants. Br J OBstet Gynaecol. 1986;93:1049-59.

20 Hertig AT. Vascular pathology in the hypertensive albuminuric toxemias of pregnancy. Clinic. 1945;4:602-14.

21 Sexton LI, Hertig AT, Reid DE, Kellogg FS, Patterson WS. Premature separation of the normally implanted placenta. Am J Obstet Gynecol. 1950;59:13-24.

22 Robertson WB, Brosens I, Dixon HG. The pathological response of the vessels of the placental bed to hypertensive pregnancy. Obstet Gynecol. 1964;24:350-6.

23 Robertson WB, Brosens I, Dixon G. Uteroplacental vascular pathology. Eur J Obstet Gynecol Reprod Biol. 1975;5:47-65.

24 Mossman HW. Comparative morphogenesis of the foetal membranes and accessory uterine structures. Contrib Embriol Carneg Instn. 1937;26: 129-246.

25 Pijnenborg R, Bland JM, Robertson WB, Dixon G, Brosens I. The pattern of interstitial trophoblastic invasion of the myometrium in early human pregnancy. Placenta. 1981;2:303-16.

26 Robertson WB, Warner B. The ultrastructure of the human placental bed. J Pathol. 1974;112:203-11.

27 Librach CL, Werb Z, Fitzgerald ML, Chiu K, Corwin NM, Esteves RA, Grobelny D, Galardy R, Damsky CH, Fisher SJ. 92-kD type IV collagenase mediates invasion of human cytotrophoblasts. J Cell Biol. 1991;113:437-49.

28 Graham CH, Lala PK. Mechanisms of placental invasion of the uterus and their control. Biochem Cell Biol. 1992;70:867-74.

29 Damsky CH, Fitzgerald ML, Fisher SJ. Distribution patterns of extracellular matrix components and adhesion receptors are intricately modulated during first trimester cytotrophoblast differentiation along the invasive pathway, in vivo. J Clin Invest. 1992;89:210-22.

30 Aplin JD. Expression of integrin $\alpha 6\beta 4$ in human trophoblast and its loss from extravillous cells. Placenta. 1993;14:203-15.

31 Pijnenborg R, Bland JM, Robertson WB, Brosens I. Uteroplacental arterial changes related to interstitial trophoblast migration in early human pregnancy. Placenta. 1983;4:397-414.

32 Mitchell MD, Trautman MS, Duddley DJ. Cytokine networking in the placenta. Placenta. 1993;14:249-75.

33 Hamilton WJ, Boyd JD. Trophoblast in human utero-placental arteries. Nature. 1966;212:906-9.

34 Ramsey EM, Harris WS. Comparison of uteroplacental vasculature and circulation in the rhesus monkey and man. Cont Embryo. 1966;261:61-70.

35 Ramsey EM, Houston ML, Harris JW. Interactions of the trophoblast and maternal tissues in three closely related primates species. Am J Obstet Gynecol. 1976;124:647-52.

36 Wynn RM. Cytotrophoblastic specialisations. An ultrastructural study of the human placenta. Am J Obstet Gynecol. 1972;114:339-55.

37 Wynn RM, Panigel M, MacLennan AH. Fine structure of the placenta and fetal membranes of the baboon. Am J Obstet Gynecol. 1971;109:638-48.

38 Pijnenborg R, Dixon G, Robertson WB, Brosens I. Trophoblastic invasion of the human decidua from 8 to 18 weeks of pregnancy. Placenta. 1980;1:3-19.

39 Pijnenborg, R (Personal communication).

40 Brosens I, Robertson WB, Dixon HG. The physiological response to the vessels of the placental bed to normal pregnancy. J Pathol Bacteriol. 1967;93:569-79.

41 Thorbet A, Alm P, Bjorklund AB, Owman C, Sjoberg NO. Adrenergic innervation of the human uterus. Disappearance of the transmitter and transmitter-forming enzymes during pregnancy. Am J Obstet Gynecol. 1979;135:223-6.

42 Moll W, Kunzel W, Herberger J. Hemodynamic implications of hemochorial placentation. Eur J Gynaecol Reprod Biol. 1975;5:67-74.

43 Robertson WB, Khong TY, Brosens I, De Wolf F, Sheppard BL, Bonnar J. The placental bed biopsy: Review from the European centers. Am J Obstet Gynecol. 1986;155:401-12.

44 Blankenship TN, Enders AC, King BF. Trophoblastic invasion and modification of uterine veins during placental development in macaques. Cell Tissue Res. 1993;274:135-44.

45 Gerretsen G, Huisjes HJ, Hardonk MJ, Elema JD. Trophoblast alterations in the placental bed in relation to physiological changes in spiral arteries. Br J Obstet Gynaecol. 1983;90:34-9.

46 Pijnenborg R. Uteroplacental ischemia and hypertensive disorders of pregnancy. Issues in Nephrosciences 1.91. Milano, Italy. Wichtig Editore. 1991. p8-13.

47 Zhou Y, Damsky CH, Chiu K, Roberts JM, Fisher SJ. Preeclampsia is associated wtih abnormal expression of adhesion molecules by invasive cytotrophoblasts. J Clin Invest. 1993;91:950-60.

48 Zimmerman GA, Prescott SM, McIntyre TM. Endothelial cell interactions with granulocytes: tethering and signaling molecules. Immunol Today. 1992;13:93-100.

49 Chin YH, Sackstein R, Cai JP. Lymphocyte-homing receptors and preferential migration pathways. Proc Soc Exp Biol Med. 1991;196: 374-480.

50 Paget S. Lancet. 1889;1: 571-573 (reviewed by Schirrmacher V. Cancer metastasis: Experimental approaches, theoretical concepts, and impacts for treatment strategy. Adv Cancer Research. 1985;43: 1-69.

51 Weiss L. *In: Current Concepts in Cancer.* Rubin P [ed]. Pergamon, Oxford. 1975. p.97-9.

52 Jackson AM, Alexandrov AB, Gribben SC, Esuvamathan K, James K. Expression and shedding of ICAM-1 in bladder cancer and its immunotherapy. Int J Cancer. 1993;55(6): 921-5.

53 Ishikawa T, Imura A, Tanaka K, Shirane H, Okuma M, Uchiyama T. E-selectin and vascular cell adhesion molecule-1 mediate adult T-cell leukemia cell adhesion to endothelial cells. Blood. 1993;82(5): 1590-8.

54 Shimizu Y, Newman W, Tanaka Y, Shaw S. Lymphocyte interactions with endothelial cells. Immunol Today. 1992;13:106-12.

55 Picker LJ, Butcher EC. Physiological and molecular mechanisms of lymphocyte homing. Ann Rev Immunol. 1992;10:561-91.

56 Springer TA. Adhesion receptors of the immune system. Nature. 1990;346:425-34.

57 Harning R; Myers C; Merluzzi VJ. Monoclonal antibodies to lymphocyte function-associated antigen-1 inhibit invasion of human lymphoma and metastasis of murine lymphoma. Clin Exp Metastasis. 1993;11: 337-42.

58 Yednock T, Cannon C, Fritz LC, Sanchez-Madrid F, Steinman L, Karin N. Prevention of experimental autoimmune encephalomyelitis by antibodies against a4b1 integrin. Nature. 1992;356: 63-6.

[59] Zhu D, Cheng CF, Pauli. Blocking of lung endothelial cell adhesion molecule-1 (Lu-ECAM-1) inhibits murine melanoma lung metastasis. J Clin Invest. 1992;89(6): 1718-24.

[60] Isobe M, Yagita H, Okumura K, Ihara A. Specific acceptance of cardiac allograft after treatment with antibodies to ICAM-1 and LFA-1. Science. 1992;255: 1125-7.

[61] Burrows TD, King A, Loke YW. Expression of adhesion molecules by endovascular trophoblast and decidual endothelial cells: Implications for vascular invasion during implantation. Placenta. 1994;15: 21-33.

[62] King A Loke YW. Differential expression of blood-group related carbohydrate antigens by trophoblast subpopulations. Placenta 1988;9: 513-21.

[63] Pollard JW, Bartocci A, Arceci R, Orlofsky A, Ladner MB, Stanley ER. Apparent role of the macrophage growth factor CSF-1 in placental development. Nature. 1987;330:484-6.

[64] Arceci R, Shanahan JF, Stanley ER, Pollard JW. Temporal expression and location of colony-stimulating factor 1 (CSF-1) and its receptor in the female reproductive tract development. Proc Natl Acad Sci. 1989;86:8818-22.

[65] Wegmann TG, Athanassakis L, Gilbert L, Branch D, Dy M, Menu E, Chaouat G. The role of M-CSF and GM-CSF in fostering placental growth, fetal growth survival. Trans Proc. 1989;21:566-8

[66] Armstrong DT, Chaouat G. Effects of lymphokines and immune complexes on murine placental cell growth *in vitro*. Biol Reprod. 1989;40:466-74.

[67] Pollard JW, Hunt JS, Wiktor-Jedrzejczak W, Stanley ER. A pregnancy defect in the osteopetrotic (*op/op*) mouse demonstrates the requirement for CSF-1 in female fertility. Dev Biol. 1991;148:273-83.

[68] Saito S, Motoyoshi K, Saito M, Kato Y, Enomoto M, Nishikawa K, Morii T, Ichijo M. Localization and production of human macrophage colony-stimulating factor (hM-CSF) in human placental and decidual tissues. Lymphokine Cytokine Res. 1993;12:101-7.

[69] Daiter E, Pollard JW. Colony stimulating factor-1 (CSF-1) in pregnancy. Reprod Med Rev. 1992;1:83-97.

[70] Daiter E, Pampfer S, Yeung YG, Barad D, Stanley ER, Pollard JW. CSF-1 in the human uterus and placenta. J Clin Endocrinol Metabol. 1992;74:850-8.

[71] Pampfer S, Daiter E, Barad D, Pollard JW. Expression of colony stimulating factor-1 receptor (the *c-fms* proto-oncogene product) in the human uterus and placenta. Biol Reprod. 1992;46:48-57.

[72] Saito S, Motoyoshi K, Ichijo M, Saito M, Takaku E. High serum human macrophage colony-stimulating factor level during pregnancy. Int J Hematol. 1992;55:219-25.

73 Saito S, Ibaraki T, Enomoto M, Ichijo M, Motoyoshi K. Macrophage colony-stimulating factor induces the growth and differentiation of normal pregnancy human cytotrophhoblast cells and hydatidiform moles but does not induce the growth and differentiation of choriocarcinoma cells. Jpn J Cancer Res. 1994;85:245-52.

74 Tartakovsky B, Goldstain O, Brosh N. Colony-stimulating factor-1 blocks early pregnancy in mice. Biol Reprod. 1991;44:906-12.

75 Drake BL, Head JR. GM-CSF and CSF-1 stimulate DNA synthesis but not cell proliferation in short-term cultures of mid-gestation murine trophoblast. J Reprod Immunol. 1994;26:41-56.

76 Jokhi PP, Chumbley G, King A, Gardner L, Loke YW. Expression of the colony stimulating factor-1 receptor (*c-fms* product) by cells at the human uteroplacental interface. Lab Invest. 1993;68:308-20.

77 Bulmer JN, Sunderland CA. Immunohistochemical characterization of lymphoid cell populations in the early human placental bed. Immunology 1984; 52: 349-57.

78 Kabawat SE, Mostaufui-Zedeh M, Driscoll SG, Bhan AK. Implantation site in normal pregnancy: A study with monoclonal antibodies. Am J Pathol. 1985;118: 76-84.

79 King A, Balendran N, Wooding P, Carter NP, Loke YW. Phenotypic and morphologic characterization of novel $CD3^-$, $CD56^{bright}$ + lymphocytes in the pregnant human uterus. Dev Immunol 1991;1:169-190.

80 Lanier LL, Le AM, Civin CI, Loken MR, Philips JH. The relationship of CD16 (Leu11) and Leu-19 (NKH-1) antigen expression on human peripheral blood NK cells and cytotoxic T lymphocytes. J Immunol 1986;136: 4480-6.

81 Ferry BL, Sargent LL, Starkey PM, Redman CWG. Cytotoxic activity against trophoblast and choriocarcinoma cells of large granular lymphocytes from human early pregnancy decidua. Cellular Immunol. 1991;132:140-9.

82 King A, Loke YW. Human trophoblast and JEG choriocarcinoma cells are sensitive to lysis by IL-2 stimulated decidual NK cells. Cellular Immunol. 1990;129:435-48.

83 Redline RW, Lu CY. Specific defects in the anti-listerial immune response in discrete regions of the murine uterus and placenta account for susceptibility to infection. J Immunol. 1988;140:3947-55.

84 Athanassakis I, Bleackley RC, Paektau L, Guilbert L, Barr PJ, Wegmann TG. The immunostimulatory effect of T cells and T cell lymphokines on murine fetally derived placental cells. J Immunol. 1987;138:37-44.

85 Michel M, Underwood J, Clark DA, Mowbray JF, Beard RW. Histologic and immunologic study of uterine biopsy tissue of women with incipient abortion. Am J Obstet Gynecol. 1989;161:409-14.

86 Gendron RL, Farookhi R, Baines MG. Resorption of CBA/J x DBA/2 mouse conceptuses in CBA/J uteri correlates with failure of the feto-maternal unit to suppress natural killer cell activity. J Reprod Fertil. 1990;89:277-84.

87 Gubler U, Chua AO, Schoenhaut DS, Co-expression of two distinct genes is required to generate secreted bioactive cytotoxic lymphocyte maturation factor. Proc Natl Acad Sci USA. 1991;88:4143-7.

88 D'Andrea A, Rengaraju M, Valiante NM. Production of natural killer cell stimulatory factor (Interleukin 12) by peripheral blood mononuclear cells. J Exp Med. 1992;176:1387-98.

89 Naume B, Espevik T. Immunoregulatory effects of cytokines on natural killer cells. Scand J Immunol. 1994;40:128-34.

90 Keith, Jr, JC , Thatcher CD, Schaub RG. Beneficial effects of U-63,557A, a thromboxane synthetase inhibitor, in an ovine model of pregnancy-induced hypertension. Am J Obstet Gynecol 1987; 157:199-203.

91 Keith Jr. JC, Endo Y, Warwick K, Keith KE, Brugh S, Rowles TK. Ridogrel improves maternal / fetal homeostasis in an ovine model of pregnancy-induced hypertension. Prostaglandins. 1994;47:247-53.

92 Duval M. Le placenta des rongeurs. III. Le placenta de la souris et du rat. J Anat. Physiol. (Paris) 1891;27:515-612.

93 Bridgeman J. A morphological study of the development of the placenta of the rat. I. An outline of the development of the placenta of the white rat. J Morphol. 1948;83:61-86.

94 Holmes RP, Davies DV. The vascular pattern of the placenta and its development in the rats. J Obstet Gyn Br Empire. 1948;55:583-607.

95 Young A. The vascular architecture of the rat uterus. Trans Roy Soc Edinburgh. 1952. Sect B. 64;292-311.

96 Young A. The vascular architecture of the rat uterus during pregnancy. Trans Roy Soc Edinburgh. 1956;63:167-83.

97 Pijnenborg R. Ph. D. thesis: Placentation in the golden hamster (*Mesocricetus auratus* waterhouse). 1975.

98 Ornisi MW. The trophoblastic giant cells and endovascular cells, associated with pregnancy in the hamster, *Cricetus auratus.* Am J Anat. 1954;94:273-331.

99 Peel S. Granulated metrial gland cells. Adv Anat Embryol Cell Biol. 1989;115:1-112.

100 Ginsburg H, Coleman R, Davidson S, Khoury C, Mor R. Lymphokine activated killer (LAK) cells are identical to the uterine granulated metrial gland (GMG) cells. Transplant Proc. 1989;21:186-9.

101 King A, Loke YW. Human uterine large granular lymphocytes: what are they and what is their function? Immunol Today. 1991;12:432-5.

PART II

RESULTS

CHAPTER 1

IN VITRO EFFECTS OF CYTOKINE GROWTH FACTORS IN TERM SYNCYTIOTROPHOBLAST CELLS ISOLATED FROM PLACENTAS OF NORMAL AND PREECLAMPTIC PREGNANT WOMEN

ABSTRACT

The effects of macrophage-colony stimulating factor (M-CSF) and granulocyte macrophage-colony stimulating factor (GM-CSF) were investigated on cultured term syncytiotrophoblast cells obtained from placentas of normal and abnormal pregnancies. In contrast to reported trophic effects of M-CSF on early trimester trophoblast cells, both M-CSF and GM-CSF had little effect on cell proliferation and giant cell formation of our term trophoblast cells whether they were obtained from normal or preeclamptic pregnant women. Moreover, the concentration of M-CSF in culture supernatant and the expression of M-CSF receptors were below the detection limits of the assay system. On the other hand, a trophoblast tumor cell line, JEG-3 that is considered to be similar to trophoblast cells in early pregnancy, did show increased proliferation in response to M-CSF. Based on these observations, the specimens used in this study might have been obtained too late to respond to these cytokines.

INTRODUCTION

Cytokines were originally presumed to be cell lineage specific and described particularly in relation to the immune system. However, recently many cytokines are shown to be pleiotropic in function and localized at various different tissues including placentas.[1] Among the cytokines found at the maternal-fetal interface, M-CSF has

received intense attention because of its putative trophic effects on placentas and its trimester dependent distribution.[2]

Most of what we know about the roles of M-CSF during pregnancy have been derived from experiments in mice. The involvement of M-CSF in pregnancy was first suggested by the observation of markedly increased decidual M-CSF levels in murine pregnancy.[3] Thereafter, the temporal and topological expression of mRNA encoding M-CSF and its receptors, *c-fms* were demonstrated in rodent placentas and appeared to correlate with placental growth and differentiation.[4] In addition, an *in vitro* trophic effect of M-CSF on trophoblast cells was reported.[5] Since injections of both M-CSF and GM-CSF were reported to decrease the spontaneous abortion rate in mice, and were associated with increased placental and fetal weights,[4,6] these growth factors were considered to promote placental and fetal development.[7] However, there are conflicting observations: M-CSF has been reported to increase a fetal resorption rate in a certain strain of mice.[8,9] Therefore, the exact roles of M-CSF in the female reproductive tract during pregnancy remain to be elucidated.

Similar to the observations in mice, trimester-dependent distribution of M-CSF[10,11] and its receptors[12,13] in placentas were recently reported in humans. In addition, the concentration of circulating M-CSF progressively increases during pregnancy and is higher than those of non-pregnant women.[14] These data suggest important physiological roles for M-CSF during pregnancy.

At present, no information is available regarding the roles of M-CSF in abnormal pregnancy. By comparing the response of different types of trophoblast cells to M-CSF, we may be able to obtain important insights regarding the roles of M-CSF in normal and abnormal pregnancies. Therefore, in this study, three types of trophoblast cells were used: those obtained from (1) normal pregnant and (2) preeclamptic women, and (3) a choriocarcinoma cell line, JEG-3. The latter two types of trophoblast cells were chosen

because of their unique characteristics. In preeclamptic pregnancy, the depth of endovascular trophoblast cell invasion is inappropriately shallow.[15] In addition, the number of interstitial trophoblast cells are reported to be higher than normal.[16] On the other hand, the JEG-3 cells, a known neoplastic form of trophoblasts, are invasive and immortal. Interestingly, patients with choriocarcinoma sometimes show a clinical syndrome smilar to that seen in preeclamptic patients. Trophoblast cells from normal pregnant women served as a control.

EXPERIMENTAL DESIGNS

Trophoblast cells were isolated from term placentas and subsequently cultured. After attachment of trophoblast cells to the culture dish, test compounds were added to the medium and the effects were evaluated at 24hr, 48hr, 72hr, and 5 days. As endpoints, cell proliferation and giant cell formation were measured by MTT assay and light microscopic observation, respectively. The relative number of M-CSF receptors on cultured trophoblast cells were measured using biotinylated-M-CSF. Also, the secretion of M-CSF was measured by ELISA.

METHODS

Subjects:

Patients in this study were women who received medical care at University Hospital of Leuven, Belgium. Placentas were obtained at delivery from normal and preeclamptic pregnant women by particpating obstetricians.

Processing of placentas and cell culture technique:

Primary cell cultures of trophoblast cells isolated from the third trimester human placentas of normal and preeclamptic pregnancies were established according to a technique modified from Kliman et al.[17]

(Day 1) The placentas were obtained using aseptic technique and rinsed with cold phosphate buffered saline (PBS). Several sections (approximately 10 gram) of tissues taken from the maternal side of the placenta, were placed in a sterile petri dish and a scalpel was used for rough separation of cell components from the most obvious fibrous tissues. The cells were weighed and added to 50 ml of trypsin solution supplemented with EDTA.

(Day 2) After storing overnight at 4 °C, 0.01 gram of DNase I was added and the mixture was incubated in a shaking waterbath (60 revs/min) at 37 °C for 15 minutes. Dulbecco's modified essential medium (DMEM) supplemented with 20% of fetal calf serum (FCS) was added and left for 1 minute to inactivate trypsin. Then, the solution was poured into sterile Gibco flasks through sterile cloth of 100µm mesh diameter to remove cell debris. Finally, the cell suspension was centrifuged over a continuous Percoll gradient at 2,300 rpm for 20 min and the trophoblast cell layer was aspirated (a specific gravity of 1.048-1.062 g/ml).

Two hundred µl of trophoblast cells (200,000 cells/ml) were cltured in microtiter plates with plating medium (Gibco) to encourage cell attachment. After attachment of trophoblast cells, medium was replaced to remove non-adherent cells.

JEG-3 cells were obtained from those maintained in the laboratory of Obstetrics and Gynaecology, University of Leuven, Beligum. Culture of the JEG-3 choriocarcinoma cell line was performed according to standard cell culture techniques, using DMEM supplemented with 20 % FCS.

Identify of trophoblast cells by staning with cytokeratin

The purity of trophoblast cells was evaluated by staining isolated cells with anti-cytokeratin antibodies. Cytokeratin exists in cells of epithelial origin including trophoblast cells, hence it has been widely regarded as a cell marker for trophoblast cells. Cells

were fixed with buffered neutral formalin. Endogenous peroxidase was quenched by incubating cells with 0.5 % hydrogen peroxide (Sigma, MO) and 0.1 % of NaN_3 for 15 min. After washing with Tris buffered saline (TBS) pH 7.8 (3 x 5 minutes each), non-specific binding was inhibited by incubating cells 3 times with 2% bovine serum albumin (Sigma) in TBS for a minimum of 15 min. Then, cells were incubated with anti-cytokeratin (1/400) (Dako) for 30 minutes. After washing with TBS (3 x 5 minutes each), 2% bovine serum albumin was again applied to cells for 15 min. Then, secondary biotinylated rabbit anti-mouse immunoglobulins (1/400) preincubated 30 min with 4 % whole human serum (Organon Teknika) were incubated for 30 min followed by washing with TBS (3 x 5 minutes each). Thereafter, streptavidin-peroxidase (1/800) (Jackson Immunoresearch Laboratory) was used to bind peroxidase to the secondary antibodies (30 min). Finally, peroxidase was developed by DAB (Sigma) and sections were counter-stained with Harris hematoxylin (Sigma) for microscopic observation.

Addition of test compounds:

After the wells of the Nunc microtiter plates had been prewashed with DMEM, the medium was changed to the culture medium supplemented with test compounds. The trophoblast cells were incubated for 24hr, 48hr, 72hr, and 5 days and the medium collected was centrifuged at 600 g for 10 minutes to eliminate cell debris. The supernatants were stored at -80 °C until assayed. The plates were fixed with ethanol and 4 % paraformaldehyde and stained with trypan blue for evaluation of cell morphology.

ELISA for M-CSF Receptors:

The relative expression of M-CSF receptors was measured using biotinylated-M-CSF (Genetics Institute, Cambridge, MA).[18] Cells (2 x 10^5 cells/ml) were incubated with 100 µl of biotinylated M-CSF (0.5 µg/mL) in PBS containing 0.02 % Na azide for 45 min

at 4°C. Cells were centrifuged at 500g for 5 min, washed once, and resuspended in 100 µl of streptavidin-peroxidase (0.5 µg/mL) (Boehringer-Mannheim). After incubation at 4 C° for 30 min, cells were washed twice and 100 µl of 2,2'-Azinobis(3-ethylbenz-thiazolinesulfonic Acid) (ABTS) (Kirkegaard and Perry) were added followed by microplate reading at 490 nm.

Proliferation Assay (MTT):

The MTTassay is a method for measuring cell proliferation, originally developed by Mossman in 1983.[19] As cells are dead or damaged, their mitochondria lose the ability to metabolize MTT to formazan, the product measured in the assay.

After 24, 48 and 72 hour incubation periods, 40 µl containing 2.5 mg (3[4,5-dimethylthiazol-2-yl]-2,5-diphenyl-tetrazolium bromide (MTT, Sigma Chemical Co., St. Louis, MO) were added to each well and incubated at 37 C° for 2 hours. Then the media were removed and replaced with 120 µl of a mixture of dimethyl sulphoxide (DMSO) and Sorenson's glycine buffer (1:5). Plates were agitated well to solubilize the formazan crystals. Thereafter, color reactions were read at 540 nm using a microplate reader. Proliferation was expressed as % control: (Test MTT O.D. / control MTT O.D.) x 100.

Assay for M-CSF in culture fluids

M-CSF levels were determined by enzyme-linked immunosorbent assay (ELISA) developed by Genetics Institute Inc. Briefly, 100 µl of coating solution consisting of mouse monoclonal antibodies against recombinant human M-CSF (HM7/2.4.4) (Genetics Institute) diluted in Tris buffered solution / 0.05% Tween 20 (Sigma, MO) [TBST] were added to each microtiter well (Nunc, Denmark) and incubated for 18-24 h at 4-8 °C. Then the plates were washed four times with 300 µl of TBST. Then, 300 µl of gelatin-containing buffer pre-warmed to 37 °C was distributed to each well and incubated

for 120 min. The coated wells were sealed and stored at 4°C until used, within one month.

Before use, the plates were washed four times with TBST. Eighty µl of unknown, control or standard solution, diluted with 25% of normal bovine serum in Tris high salt buffered solution / 0.05% Tween 20 (THST), were added to wells and incubated while shaking for 2 hours at room temperature (RT). Following four washes with THST, remaining moisture was blotted. Eighty µl of detector antibodies (anti-M-CSF) (Genetics Institute) was added to all wells, and incubated while shaking for 90 min at RT. After washing the plates four times with THST, 80 µl/well of horseradish avidin peroxidase was added and allowed to incubate for 1 h. Following washing, 80 µl of ABTS substrate was added to each well and plates were protected from light for 9 min at RT. The reaction was stopped with stop solution (Kirkegaard and Perry). The color reaction was read on an automatic plate reader, using dual-beam wavelengths of 405 nm and 620 nm. The level of M-CSF was calculated from corresponding standard curve.

Statistical analysis

The significance of differences between mean values of each experiment was evaluated by ANOVA. Relationships between selected parameters were determined by regression analysis. A p value ≤ 0.05 was considered significant.

RESULTS

Purity of isolated trophoblast cells

Cells from selected patients were stained with anti-cytokeratin antibodies. Based on the number of cells positive to the antibody, the purity of cells was considered to be 80-90 %. Contaminating cells included fibroblasts, macrophages, endothelial cells, and glandular cells.

Proliferation

Cultured term trophoblast cells isolated from both normal and preeclamptic pregnancies did not proliferate and the number of cells gradually diminished. Trophoblast cells from normal pregnant women survived significantly better than those from preeclamptic pregnancy at day 5 ($P<0.01$). Trophic effects of CSFs on term trophoblast cells were not observed. On the other hand, JEG-3 cells, a choriocarcinoma cell line, proliferated spontaneously and did show enhanced proliferation after the addition of M-CSF and GM-CSF throughout the observation period. Similarly, trophoblast cells from a 15th week missed abortion patient survived better than term trophoblast cells and proliferated after growth factors treatment.

Table 1-1. Effects of M-CSF and GM-CSF on Trophoblast Cells

Normal pregnancy (n=15)	Control	M-CSF (2000U/ml)	GM-CSF (2000U/ml)
Day 1	100	104 ±13.5	95 ±7.2
Day 3	93 ±10.7	90 ±12.3	96 ±11.6
Day 5	80 ±12.8[a]	82 ±16.0[a]	80 ±12.9[a]

[a] $0.05 < P < 0.02$ (Compared to day 1 of each treatment).

Preeclamptic pregnancy (n=10)	Control	M-CSF (2000U/ml)	GM-CSF (2000U/ml)
Day 1	100	97 ±8.8	97 ±9.0
Day 3	84 ±6.6[a]	87 ±11.4	80 ±14.4
Day 5	58 ±13.5[b]	60 ±18.7[b]	66 ±19.1[b]

[a] $P < 0.05$, [b] $0.005 < P < 0.001$ (Compared to day 1 of each treatment).

JEG-3 choriocarcinoma cells	Control	M-CSF (2000U/ml)	GM-CSF (2000U/ml)
Day 1	100	124 ±10.5[a]	120 ±9.7[a]
Day 2	145 ±10.3	187 ±15.6[b]	203 ±20.1[b]
Day 3	197 ±25.9	341 ±37.1[c]	337 ±45.2[c]

[a] $P < 0.05$, [b] $P < 0.03$, [c] $P < 0.001$

* Data were expressed as a per cent ratio of each values compared to control (Day 1 without growth factors). % = value (OD) / control (OD) (Day 1) x 100.

Trophoblast cells from a missed abortion placenta at the 15th week of gestation

n=1	Control	M-CSF (2000U/ml)	GM-CSF (2000U/ml)
Day 1	100	127 ±7.9[a]	146 ±2.2[b]
Day 2	105 ±5.4	141 ±6.3[b]	163 ±6.8[c]
Day 3	102 ±5.3	-	175 ±2.8[c]

[a] $P < 0.05$, [b] $0.02 < P < 0.01$, [c] $0.004 < P < 0.001$

Giant cell formation

Trophoblast cells from both normal and preeclamptic patients started to form cell aggregates spontaneously immediately after seeding onto the culture dish. This activity was observed throughout the observation period (5 days). Cells in these aggregates fused together to form giant cells. At day 5, giant cells / cell aggregates consisted of more than 90% of all cells. There was no significant difference in the rate of giant cell formation between normal and preeclamptic trophoblast cells whether supplemented with growth factors or not.

Table 1-2. The Effects of M-CSF and GM-CSF on Giant Cell Formation from Trophoblast Cells

Normal pregnancy (n=15)	Control	M-CSF (2000U/ml)	GM-CSF (2000U/ml)
6 hours	37 ±11.7	39 ±9.2	50 ±8.0
Day 1	72 ±7.6	70 ±10.9	75 ±3.7
Day 3	81 ±9.2	85 ±9.3	87 ±8.6
Day 5	90 ±6.1	89 ±5.7	91 ±4.3

Preeclamptic pregnancy (n=10)	Control	M-CSF (2000U/ml)	GM-CSF (2000U/ml)
6 hours	36 ±9.5	38 ±7.6	51 ±19.3
Day 1	71 ±12.4	76 ±7.2	78 ±10.1
Day 3	80 ±10.2	80 ±6.9	88 ±8.8
Day 5	85 ±5.5	86 ±4.7	87 ±6.3

* Giant cell index (%)= (total # of nuclei within both giant cells and cell aggregates) / total # of nuclei) x 100. 200 µl of 200,000 cells/ml were seeded into each microtiter well.

Relative expression of M-CSF receptors:

In this experiment, I examined the relative expression of M-CSF receptors among three types of trophoblast cells used in this study. The receptor expression by normal and preeclamptic trophoblast cells were under the detection limit of the assay. On the other hand, M-CSF receptors on JEG-3 cells were weakly detectable.

Table 1-3. Relative Number of M-CSF Receptors

Trophoblast cells from normal pregnant	0.075 ± 0.012
Trophoblast cells from preeclamptic pregnant	0.076 ± 0.008
JEG-3 cells	0.15 ± 0.021[a]
Background	0.078 ± 0.0005

[a] $p < 0.02$ * The unit is optical density (OD) of absorbency at 490 nm.

Concentration of M-CSF in culture media

M-CSF concentration in culture media collected from three types of trophoblast cells was below our detection limit (20U/ml).

Table 1-4. M-CSF Levels in Supernatants from Cultured Trophoblast Cells.

Normal pregnant (n=10)	below detection limit
Preeclamptic pregnant (PE) (n=10)	below detection limit
JEG-3 cells	below detection limit

DISCUSSION

Since the trophic effects of CSFs on trophoblast cells are proposed as a major function of placental CSFs, proliferative effects of CSFs were first evaluated on cultured trophoblast cells. As have been shown, trophoblast cells did not show an increased growth after either M-CSF nor GM-CSF treatment. In fact, the total number of trophoblast cells appeared to decrease. The discrepancy between other reported data[11] and this study may be explained by difference in the nature of materials and experimental methods. This study utilized fully differentiated term trophoblast cells from the fetal side of the placenta which contained syncytiotrophoblast cells as a major cell type and cytotrophoblast cells as a minor one with possible contamination of villous mesenchymal cells. In contrast, trophoblast cells that were reported to have a proliferative activity after M-CSF treatment were invariably those obtained from medically indicated abortion materials early in pregnancy, which contain proliferating tips of anchoring villi.

In addition to the difference of specimens, most reports used ^{3}H-thymidine uptake to demonstrate proliferation of trophoblast cells. In this study, I used an MTT method which measures the activity of mitochondria. However, when Drake and Head counted the actual cell numbers of mouse trophoblast cells after M-CSF treatment, they could not see any increase of cell numbers while they observed an increased ^{3}H-thymidine uptake by trophoblast cells.[20] Instead trophoblast cells were associated with giant nuclei formation. Therefore, there is no surprise that ^{3}H-thymidine uptake does not correspond with increased cell number ot proliferation. Indeed, cultured trophoblast cells have not been shown to have a proliferative activity *in vitro* when an actual counting method was used, except for tumor cell lines such as JEG-3, JAR, BeWo or SV40 transformed cells. Moreover, *op* pregnant mice, which lack M-CSF, have a decreased pregnancy success rate but normal placental weights.[21] Apparently, more research has

to be done regarding putative trophic effects of M-CSF on placental cells in both *in vivo* and *in vitro* systems. Thus, because of the limitation of specimens and assay method in this study, proliferation may not be an appropriate endpoint although the results of this study do not exclude the role of M-CSF as a trophic factor for placental development.

Another endpoint evaluated was giant cell formation. In normal pregnancy, the majority of interstitial trophoblast cells which invaded the maternal tissues form giant cells spontaneously until term. Similarly, trophoblast cells which stay at the primary villi form syncytiotrophoblast cells. The reported topology of M-CSF appears to correlate with the proliferating activity of trophoblast cells, or inversely with giant or syncytial cell formation: the staining intensity was observed to be the strongest in proliferating cytotrophoblast cell columns and to gradually decrease as trophoblast cells invade deep into the maternal tissues and form giant cells.[10,11] Therefore, it is suggested that M-CSF restrains giant cell formation of trophoblast cells *in vivo*.[12] Interestingly, in preeclamptic pregnancy, the number of trophoblastic giant cells in the decidua and myometrium at term was reported to be increased.[16] However, again, I could not see any effects of CSFs on giant cell formation by trophoblast cells *in vitro* whether cells were from normal or preeclamptic pregnant women. Trophoblast cells spontaneously formed giant cells. Within as little as a few hours, trophoblast cells started to aggregate and by day 5, more than 90% of trophoblast cells formed giant cells. Therefore, M-CSF appears to have little effect on preventing giant cell formation *in vitro*.

At present, Kliman's technique is the most widely accepted method to isolate trophoblast cells.[17] However, his method requires mechanical dissagregation and use of trypsin and other enzymes such as DNAase. If the *in vivo* milieu is necessary for trophoblast cells to remain viable and active, and is very important in their function and differentiation, isolation procedures may have profound effects on isolated trophoblast

cells, which may therefore be less active. This possibility makes extrapolation of *in vitro* data to the *in vivo* condition very difficult.

I also examined the relative expression of M-CSF receptors among different types of trophoblast cells. As has been shown above (Table 3), receptors on normal and preeclamptic trophoblast cells were under the detection limits of assay system used in this study, suggesting that cultured villous trophoblast cells express few M-CSF receptors. At present, the distribution of M-CSF receptors in human placentas is fiercely debated. Two groups used their own sets of monoclonal and polyclonal antibodies raised against human M-CSF receptors.[12,13] However, their observations are totally different. While Jokhi et al. found a weak staining on villous syncytiotrophoblast cells and modest staining on extravillous trophoblast cells, Pampfer et al. observed the strongest staining on the syncytiotrophoblast cells throughout pregnancy and no staining on the extravillous trophoblast cells. There are other serious discrepancies between these two groups. The exact cause of these differences is unclear. However, the finding in this study that term syncytiotrophoblast cells express few M-CSF receptors is in agreement with the observation by Jokhi et al.[12]

M-CSF receptors were detected on JEG-3 cells though the reaction was weak, as Jokhi et al. demonstrated.[12] Indeed, I observed enhanced proliferation of JEG-3 to both M-CSF and GM-CSF treatment. At first glance, these data suggest a role of CSFs on growth or proliferation of JEG-3 cells. However, again, there is a discrepancy, Saito et al. could not observe an increased ^{3}H-thymidine uptake after M-CSF treatment of JEG-3 cells. The difference of assay methods (mitochondria activity v.s. ^{3}H incorporation) may be a cause of the discrepancy.

With regard to M-CSF production by cultured trophoblast cells, I could not detect M-CSF in culture media. The results of this study are in accordance with the results of an immunohistochemical study, in which the staining of M-CSF was absent in term

syncytiotrophoblast cells and positive only in endothelial cells in the villous stroma.[10] Although Kauma reported M-CSF production by villous cells, he used placental explants, not isolated trophoblast cells.[22] The majority of reported data that demonstrated M-CSF production by trophoblast cells were based on early trimester materials. Again, the nature of materials used may explain the discrepancy.

One of the limitations expected before this study was suitability of term trophoblast specimens since pregnancy is an epiphenomenon in which striking physiological adaptations and a dynamic process of tissue remodeling are ongoing through term. However the only trophoblast cells available for this study were those obtained from the third trimester or at term. They were mostly villous syncytiotrophoblast cells which form a monolayer of giant cells *in situ* and are considered to be specialized in the maternal fetal transfer of nutrients and gases, and the separation of maternal and fetal circulation. In preeclamptic pregnancy, these cells are relatively normal except for occasional syncytial sprouts and proliferation of cytotrophoblast cells which are considered to be due to a response to placental hypoxia.[23,24] The most important abnormality of trophoblast cells in placentas of preeclamptic pregnancy is, as discussed in the literature review, shallow invasion of endovascular trophoblast cells that occur in the first and second trimesters. That trophoblast cell population is generally inaccessible because of our inability to predict preeclampsia before the onset of clinical syndrome, lack of isolation methods and the nature of pregnancy.

I was able to obtain one specimen from the 15th week of gestation, that from a missed abortion patient. Trophoblast cell from this patient showed increased proliferation after addition of M-CSF, suggesting the importance of gestational age in evaluating trophoblast cell functions. However, this result must be interpreted with caution since the specimen was not from normal pregnancy.

In conclusion, despite the intense attention and the large amount of data published in the past regarding placental M-CSF, surprisingly little is known regarding the exact roles of this cytokine both *in vivo* and *in vitro* as discussed above. There are too many discrepancies to draw definitive conclusions. Accordingly, further studies are necessary to elucidate the role of this cytokine at the maternal-fetal interface. The data suggest that disaggregated term villous syncytiotrophoblast cells used in this study may have been no longer able to respond CSFs at least *in vitro*. The use of specimens from early trimester, as well as determing suitable endpoints appear critical in appropriately evaluating the effects of CSFs on trophoblast cells.

REFERENCES

[1] Mitchell MD, Trautman MS, Duddley DJ. Cytokine networking in the placenta. Placenta. 1993;14:249-75.

[2] Daitor E, Pollard JW. Colony stimulating factor-1 (CSF-1) in pregnancy. Reprod Med Rev. 1992;1:83-97.

[3] Pollard JW, Bartocci A, Arceci R, Orlofsky A, Ladner MB, Stanley ER. Apparent role of the macrophage growth factor CSF-1 in placental development. Nature. 1987;330:484-6.

[4] Arceci RJ, Shanahan F, Stanley ER, Pollard JW. Temporal expression and location of colony-stimulating factor 1 (CSF-1) and its receptor in the female reproductive tract are consistent with CSF-1-regulated placental development. Proc Natl Acad Sci USA. 1989;86:8818-22.

[5] Armstrong DT, Chaouat G. Effects of lymphokines and immune complexes on murine placental cell growth *in vitro*. Biol Reprod. 1989;40:466-74.

[6] Chaouat G, Menu E, Clark DA, Dy M, Minkowski M, Wegmann TG. Control of fetal survival in CBA x DBA/2 mice by lymphokine therapy. J Reprod Fert. 1990;89:447-58.

[7] Wegmann TG, Athanassakis L, Gilbert L, Branch D, Dy M, Menu E, Chaouat G. The role of M-CSF and GM-CSF in fostering placental growth, fetal growth survival. Trans Proc. 1989;21:566-8

[8] Tartakovsky B. CSF-1 induces resorption of embryos in mice. Immunol Letters. 1989;23:65-70.

[9] Tartakovsky B, Goldstain O, Brosh N. Colony-stimulating factor-1 blocks early pregnancy in mice. Biol Reprod. 1991;44:906-12.

[10] Daiter E, Pampfer S, Yeung YG, Barad D, Stanley ER, Pollard JW. CSF-1 in the human uterus and placenta. J Clin Endocrinol Metabol. 1992;74:850-8.

[11] Saito S, Motoyoshi K, Saito M, Kato Y, Enomoto M, Nishikawa K, Morii T, Ichijo M. Localization and production of human macrophage colony-stimulating factor (hM-CSF) in human placental and decidual tissues. Lymphokine Cytokine Res. 1993;12:101-7.

[12] Jokhi PP, Chumbley G, King A, Gardner L, Loke YW. Expression of the colony stimulating factor-1 receptor (c-fms product) by cells at the human uteroplacental interface. Lab Invest. 1993;68:308-20.

[13] Pampfer S, Daiter E, Barad D, Pollard JW. Expression of the Colony-stimulating factor-1 (*c-fms* proto-oncogene product) in the human uterus and placenta. Biol Reprod. 1992;46:48-57.

[14] Saito S, Motoyoshi K, Ichijo M, Saito M, Takaku F. High serum human macrophage colony-stimulating factor level during pregnancy. Int J Hematol. 1992;55:219-25.

[15] Brosens I, Robertson WB, Dixon HG. The role of the spiral arteries in the pathogenesis of pre-eclampsia. Obstet Gynecol Ann. 1972;1:177-91.

[16] Gerretsen G, Huisjes HJ, Hardonk MJ, Elema JD. Trophoblast alterations in the placental bed in relation to physiological changes in spiral arteries. Br J Obstet Gynaecol. 1983;90:34-9.

[17] Kliman HJ, Nestler JE, Sermasi E, Sanger JM, Strauss JF. Purification, characterization, and in vitro differentiation of cytotrophoblast cells from human term placentas. Endocrinol. 1986;1118:1567-82.

[18] Datta R, Imamura K, Goldman SJ, Dianoux AC, Kufe DW, Sherman ML. Functional expression of the macrophage colony-stimulating factor receptors in human THP-1 monocytic leukemia cells. Blood. 1992;79:904-12.

[19] Mosmann TJ. Rapid colorimetric assay for cellular growth and survival: application to proliferation and cytotoxicity assays. Immunol Methods. 1983;65:55-63.

[20] Drake BL, Head JR. GM-CSF and CSF-1 stimulate DNA synthesis but not cell proliferation in short-term cultures of mid-gestation murine trophoblast. J Reprod Immunol. 1994;26:41-56.

[21] Pollard JW, Hunt JS, Wiktor-Jedrzejczak W, Stanley ER. A pregnancy defect in the osteopetrotic (op/op) mouse demonstrates the requirement for CSF-1 in female fertility. Dev Biol. 1991;148:273-83.

[22] Kauma SW. Interleukin-1 beta stimulates colony-stimulating factor-1 production in human term placenta. J Clin Endocrinol Metab. 1993;76:701-3.

[23] Fox H. Effect of hypoxia on trophoblast cells in organ culture. Am J Obstet Gynecol. 1970;107:1058-64.

[24] MacLennon AH, Sharp F, Shaw-Dunn J. The ultrastructure of human trophoblast in spontaneous and induced hypoxia using a system of organ culture: a comparison with ultrastructural changes in pre-eclampsia and placental insuffciency. J Obstet Gynaecol Br Cmwlth. 1972;79:113-21.

CHAPTER 2

DECREASED SERUM LEVELS OF M-CSF IN HYPERTENSIVE PREGNANT WOMEN AT THE 16TH WEEK OF GESTATION

ABSTRACT

To overcome sampling problems faced in the previous *in vitro* experiments, serum M-CSF levels at the 16th week of gestation were measured using ELISA, and examined if any correlation between serum M-CSF levels and pregnancy outcomes exists. Serum M-CSF levels of hypertensive pregnant women (461.5 ± 10.7) were significantly lower ($p<0.05$) than those of normal pregnant women (536.0 ± 20.4 U/ml). However, despite the lowest level of M-CSF in preeclamptic group (433.8 ± 28.4), the difference between normal and preeclamptic women was not statistically significant. This was likely due to the small number of the latter patient group. The results of this study suggest potential roles of M-CSF at the time the most important physiological adaptation mechanisms during pregnancy (spiral artery remodeling) occurs, and warrant further research on the roles of M-CSF in normal and abnormal pregnancy.

INTRODUCTION

According to the World Health Organization, preeclampsia is one of the most important causes of maternal and fetal mortality and morbidity, and a disease unique to human beings during pregnancy.[1] The only effective treatment for the mother has been bed rest and prompt delivery which causes significant perinatal mortality and morbidity due to pre-term delivery.[2] Although clinical signs are well characterized, the etiology and pathogenesis of the disease remain little unknown. To reduce the risk of pre-term delivery and improve monitoring, development of acceptable and reliable screening tests is

warranted. At present, however, there is no reliable method to predict this disease before the onset of clinical manifestation.

M-CSF is a glycoprotein growth factor that governs the proliferation and differentiation of monocyte-macrophage lineage cells.[3] Although, like other cytokines, M-CSF was originally considered to be cell lineage specific, recent evidence suggest that it is also involved in the reproductive tract, particularly during pregnancy. For example, decidual levels of M-CSF in mice increase a thousand fold in the first few days of pregnancy.[4] Growth promotive effects of M-CSF in trophoblast cells are reported in cultured trophoblast cells obtained from early pregnancy.[5] Moreover, both M-CSF and its receptors are demonstrated immunohistochemically to be present on the invasive type of trophoblast cells.[6]

Similar to rodents, the serum level of M-CSF in pregnant women is reported to increase progressively and to remain higher than that of non-pregnant women although the increase is modest compared to the dramatic rise in the decidua of pregnant mice.[7,8,9] Soon after pregnancy, M-CSF levels return to normal. At present, the exact source of M-CSF during pregnancy is unknown. However, placental tissues are considered to be the major source of M-CSF because of its production from cultured trophoblast cells isolated from early trimester.[10,11,12]

Thus, with the ever increasing number of reports regarding M-CSF and pregnancy, M-CSF is considered to have important physiological roles in both human and mouse pregnancy although the exact mechanisms are still unknown. Considering the fact that this cytokine is localized in the invasive type of trophoblast cells in a trimester dependent manner, the alteration of the serum levels of M-CSF may reflect trophoblast cell invasiveness, particularly in preeclamptic pregnancy, in which endovascular trophoblast cells are suppressed in the depth of invasion.[13] Thus far, no data are available concerning the levels of M-CSF in preeclamptic pregnancy. In this study,

therefore, I measured serum M-CSF levels at the 16th week of gestation, at the time trophoblast cells fail to invade maternal arterial systems in preeclamptic pregnancy.

METHODS

Blood collection

Whole venous blood was collected from 68 pregnant women at the 16th week of gestation. Sera were prepared by centrifugation of clotted blood at 2,000g for 20 minutes, and aliquots were frozen at -70°C.

Diagnostic criteria

Women recruited for this study were members of one of three groups. One group consisted of healthy nulliparous pregnant women who have received prenatal care during pregnancy. They had: (1) demonstrated no abnormalities in blood pressures before or during their pregnancy; (2) had normal urinalysis results with no proteinuria; and (3) evidenced normal fetal growth. The second group consisted of women who have received prenatal care during pregnancy, who were normotensive prior to pregnancy, and who were healthy before they developed diastolic blood pressure of greater than 90 mmHg but no sign of proteinuria. The third group consisted of women diagnosed as having preeclampsia. Preeclampsia was defined according to the criteria published by the World Health Organization. The onset of hypertension after the 20th week of pregnancy with systolic, mean arterial, and diastolic blood pressures greater than 140, 106, 90 mmHg, respectively, obtained on two separate occasions 6 hours apart after the initiation of bedrest and hospitalization and the presence of more than 300 mg of albumin in a 24 hour urine collection were minimum inclusion criteria. The presence of multiple fetuses, molar pregnancy, and intrauterine infection with/without ruptured fetal membranes were exclusion criteria.

Procedures

Serum M-CSF levels were determined by an enzyme-linked immunosorbent assay (ELISA) (Genetics Institute, Andover, MA). Briefly, 100 µl of coating solution consisting of mouse monoclonal antibodies against recombinant human M-CSF (HM7/2.4.4) (Genetics Institute) diluted in Tris buffered solution / 0.05% Tween 20 (Sigma, MO) [TBST] were added to each microtiter well (Nunc, Denmark) and incubated for 18-24 h at 4-8 °C. Then plates were washed four times with 300 µl of TBST. Then, 300 µl of gelatin-containing buffer pre-warmed to 37 °C was distributed to each well and incubated for 120 min. The coated wells were sealed and stored at 4°C until use, within one month.

Before use, the plates were washed four times with TBST. Eighty µl of unknown, control or standard solution, diluted with 25% of normal bovine serum in Tris high salt buffered solution / 0.05% Tween 20 (THST), were added to wells and incubated while shaking for 2 hours at room temperature (RT). Following four washes with THST, remaining moisture was blotted. Eighty µl of detector antibodies (anti-M-CSF) (Genetics Institute) was added to all wells, and incubated while shaking for 90 min at RT. After washing plates four times with THST, 80 µl/well of horseradish avidin peroxidase was added and allowed to incubate for 1 h. Following washing, 80 µl of ABTS substrate (Kirkegaard and Perry) was added to each well and plates were protected from light for 9 min at RT. The reaction was halted with stop solution (Kirkegaard and Perry). The color reaction was read on an automatic plate reader, using dual-beam wavelengths of 405 nm and 620 nm. The level of M-CSF was calculated from corresponding standard curve.

Patient groups were compared using the student's *t*-test. A p value < 0.05 was considered significant. Data were expressed as the mean ± S.E.

RESULTS

Table 2-1. Serum M-CSF levels at the 16th weeks of gestation

	Normal (46)	Hypertensive (17)	Preeclamptic (5)
Serum M-CSF levels	536 ± 20.4	461.5 ± 10.7[a]	433.8 ± 28.4[b]

*The total number of patients was 68. The number of patients is included in parenthesis. Data are expressed as U/ml.

a: $p < 0.05$, b: $p < 0.07$ (compared to normal pregnant women)

The mean level of serum M-CSF at the 16th week of normal pregnant women was 536 ± 20.4 U/ml. In hypertensive pregnant women, the value was significantly lower than that of normal pregnant women and decreased to 461.5 ± 10.7 U/ml. Although preeclamptic women had the lowest mean M-CSF level (433.8 ± 28.4 U/ml). This was not statistically different from that of normal pregnant groups ($p < 0.07$). This may be due to the small number of patients in the preeclamptic group (n=5). The range of serum M-CSF levels in this study are in agreement with those of reported data.[7,8,9]

DISCUSSION

It is still controversial whether increased levels of M-CSF during pregnancy is due to an increased local production at the maternal-fetal interface or enhanced myeloid and/or splenic activities.

The most possible source of serum M-CSF during pregnancy is uterine and placental tissues although the spillover of placental M-CSF into the systemic circulation is unknown. This is reasonable because the most well known effects of M-CSF on progenitor cells in the bone marrow is the growth of macrophage lineage cells, and the placenta where M-CSF and its receptors were extensively localized is a rapidly growing organ.

Another possible source of high serum M-CSF levels during pregnancy is the increased production from myeloid and/or splenic tissues rather than the increased production of M-CSF at the maternal-fetal interface. Indeed, the circulating number of monocytic cells increases progressively through term in humans.[9] Since the elevation of M-CSF levels is reported to correlate with an increase in splenic colony forming unit and a monocytosis in pregnant mice,[14] the difference of serum M-CSF levels in different patient groups observed in this study might be due to the difference of the splenic/myeloid activity and may reflect the relative number of circulating monocytes. At present, no report has been made regarding the myeloid or splenic activity and the number of circulating monocytes in preeclamptic women. Accordingly, further research is warranted to elucidate the origin of circulating M-CSF in pregnant women.

Among the various roles of placental M-CSF that have been proposed, trophic effects have received the most intense attention. Indeed, if M-CSF has such a growth promoting effects on placentas and low serum levels thereof reflect the decreased production of placental M-CSF, the fact that preeclamptic placentas tend to be smaller than those of normotensive ones fits the picture that M-CSF promotes the growth of the placentas. However it is a fact that some preeclamptic placentas and fetuses are heavier than normal (unpublished observation). Also, little correlation between the levels of M-CSF and birth weight was detected. Accordingly, the idea to consider the role of M-CSF as growth promotion of placental cells may be too simplistic. In addition to this, based on literature review, it appears that much has to be done before a conclusion can be drawn regarding the roles of M-CSF as trophic factor in the placental development. This is discussed in Chapter 1.

At present, it appears reasonable to think that M-CSF plays a role in a complex mechanism of placental development with possible communication with other cytokines. In other words, alteration of M-CSF levels in a putative cytokine network[15] may induce

derangement of other regulatory mechanisms in the placentas, which may affect pregnancy outcomes favorably or adversely.

In conclusion, it remains to be elucidated whether decreased levels of serum M-CSF in hypertensive pregnant women are due to impaired production of M-CSF at placentas or to the decreased activity of myeloid and/or splenic activity. However, data presented here warrant further study for the role of M-CSF in normal and abnormal pregnancies and indicate that the serum level of M-CSF may be a potential candidate of screening tests for preeclampsia.

REFERENCES

[1] Roberts JM, Taylor RN Friedman SA, Goldfien A. *In* Fetal Medical Review, Dunlop W (ed). Arnold, London, 1993.

[2] Facts on Infant Mortality In: *Death Before Life: The Tragedy of Infant Mortality* ,The report of the national commission to prevent infant mortality. Senator Lawton Chiles, Chairman. Washington, DC, August 1988.

[3] Stanley ER, Guilbert LJ, Tushinski RJ, Baltelmez SH. CSF-1: A mononuclear phagocyte lineage-specific hemopoietic growth factor. J Cell Biochem. 1983;21:151-9.

[4] Pollard JW, Bartococci A, Arceci R, Orlofsky A, Ladner MB, Stanley ER. Apparent role of the macrophage growth factor, CSF-1, in placental development. Nature 1987;330;484-6.

[5] Armstrong DT, Chaouat G. Effects of lymphokines and immune complexes on murine placental cell growth in vitro. Biol Reprod. 1989;40:466-74.

[6] Arceci R, Shanahan JF, Stanley ER, Pollard JW. Temporal expression and location of colony-stimulating factor 1 (CSF-1) and its receptor in the female reproductive tract development. Proc Natl Acad Sci. 1989;86:8818-22.

[7] Yong K, Salooja N, Donahue RE, Hegde U, Linch D. Human macrophage colony-stimulating levels are elevated in pregnancy and in immune thrombocytopenia. Blood 1992;80:2897-02.

[8] Praloran V, Coupey L, Donnard M, Berrada L, Naud MF. Elevation of serum M-CSF concentrations during pregnancy and ovarian hyperstimulation. Br J Hematol. 1994;86:675-7.

[9] Saito S, Motoyoshi K, Ichijo M, Saito M, Takaku F. High serum human macrophage colony-stimulating factor level during pregnancy. Int J Hematol. 1992;55:219-25.

[10] Saito S, Motoyoshi K, Saito M, Kato Y, Enomoto M, Nishikawa K, Morii T, Ichijo M. Localization and production of human macrophage colony-stimulating factor (hM-CSF) in human placental and decidual tissues. Lymphokine Cytokine Res. 1993;12:101-7.

[11] Daiter E, Pampfer S, Yeung YG, Barad D, Stanley ER, Pollard JW. CSF-1 in the human uterus and placenta. J Clin Endocrinol Metabol. 1992;74:850-8.

[12] Pampfer S, Daiter E, Barad D, Pollard JW. Expression of colony stimulating factor-1 receptor (the *c-fms* proto-oncogene product) in the human uterus and placenta. Biol Reprod. 1992;46:48-57.

[13] Brosens I, Robertson WB, Dixon HG. The role of the spiral arteries in the pathogenesis of pre-eclampsia. Obstet Gynecol Ann. 1972;1:177-91.

[14] Bartocci A, Pollard JW, Stanley ER. Regulation of colony stimulating factor 1 during pregnancy. J Exp Med. 1986;164:956-61.

[15] Wegmann TG, Athanassakis I, Guilbert L, Branch D, Dy M, Menu E, Chaouat G. The role of M-CSF and GM-CSF in fostering placental growth, fetal growth, and fetal survival. Transplant Proc. 1989;21:566-8.

CHAPTER 3

BEHAVIOR OF ENDOVASCULAR TROPHOBLAST CELLS IN THE PREGNANT RAT

ABSTRACT

A normal sequence of endovascular trophoblast cell invasion in rats from implantation through day 20 was characterized. Despite large differences in placental anatomy and gestational days between human and rats, rat endovascular trophoblast cells simulated all features of endovascular trophoblast cell behavior in humans: selective attachment to the spiral arteries, movement against the flow of blood, embedding, and secretion of PAS-positive materials. At the end of pregnancy, placental spiral arteries of pregnant rats showed "physiological changes" similar to those seen in humans. Thus, the biology of endovascular trophoblast cells in these two species appears quite similar. Therefore, rats appear to be useful for the study of endovascular trophoblast cell behavior.

I also examined the role of intracellular cytoskeleton in trophoblast cell movement. For that purpose, I administered cytochalasin B, an actin-disrupting agent, to pregnant rats intraperitoneally from day 8 through 11. Spiral arteries of treated rats contained no endovascular trophoblast cells at day 12 and smaller fetuses at day 20 (2.52 vs. 2.8 gram. $p < 0.04$). The results suggest an important role of cytoskeleton in trophoblast cell invasion.

In addition to endovascular trophoblast cells, many leukocytes were observed to adhere to placental spiral arteries, but less to veins during pregnancy. Trophoblast cell and leukocyte attachment to the endothelium of placental spiral arteries was closely

associated with 'priming' effects of the arteries such as swelling of endothelial cells and accumulation of granulated metrial gland (GMG) cells around the spiral arteries. Because of the selectivity of trophoblast cell and leukocyte attachment, the spiral artery may express adhesive phenotypes during pregnancy.

Finally, endovascular trophoblast cells were observed to distribute preferentially to the inside of the curvature of the spiral arteries, suggesting physiological roles of 'spiral' structures in endovascular trophoblast cell migration.

INTRODUCTION

Fetally-derived endovascular trophoblast cells are unique cells that invade the spiral arteries, scroll up on the inner surface of the artery against the flow of arterial blood, and finally settle down within vessel walls. Subsequently, embedded trophoblast cells destroy smooth muscle cells and secrete eosinophilic PAS positive materials. As a result, arterial vessels lose resistant components and dilate prominently with accompanying deposition of fibrinoid materials. These morphological changes of the spiral artery are called "physiological changes,"[1] and well characterized morphologically, but little is known regarding their underlying mechanisms.

Since the movement of endovascular trophoblast cells on the luminal surface of the spiral arteries is known to be antidromical or retrograde,[2] trophoblast cells must generate a propulsive force against the flow of arterial blood. Inasmuch as organization and disorganization of actin filament are fundamental in cell locomotion of many cell types including amoebae, fibroblast, neuronal cells, etc.,[3] similar mechanisms may be involved in endovascular trophoblast cell movement as well.

Cytochalasin B is a widely used chemical in the study of cell movement *in vitro*. Also, *in vivo,* it is shown to inhibit spontaneous lung metastasis[4] and cytoskeleton

mediated-movement such as canalicular motility.[5] Therefore, pregnant rats were treated with this chemical and examined trophoblast cell invasiveness.

Another interesting aspect of endovascular trophoblast cell behavior is selective invasion into and attachment to the spiral arteries.[2] Mechanisms underlying this trophoblast cell behavior are poorly elucidated. However, similar selective intercellular interactions are seen in leukocyte homing/trafficking, in which particular phenotypes of leukocytes extravasate from specific sites of the vasculature where endothelial cells express an array of cell adhesion molecules (CAM).[6] Therefore, fundamentally similar principles may underlie both phenomena; some kinds of adhesive relationship may exist between trophoblast and endothelial cells of the spiral arteries.

Finally, these processes must be coordinated to regulate trophoblast cell invasiveness. Otherwise, trophoblast cells may fail to invade the maternal arteries as seen in placentas of preeclampsia and small-for-gestational-age infants,[7] or they may behave like invasive tumors and invade deep into maternal tissues as in choriocarcinoma.[8] Thus, the study of endovascular trophoblast cells has important clinical implication. However it has been severely hindered because of a lack of appropriate human specimens at the time trophoblast cells invade the maternal arterial systems.

Since retrograde migration of endovascular trophoblast cells is a common characteristic in animals with hemochorial placentation, rodents may be proven to be useful for the study of underlying mechanisms of endovascular trophoblast cell behavior. The choice of animals was made based on a potential for in-depth studies. In this sense, as the second most widely used laboratory animal, rats appear to have an advantage with respect to the availability of reagents such as antibodies against cytokines and CAMs, compared to hamster, which placentation is better characterized among rodents.

Most of available information regarding rat placentation is morphological observation by Holmes and Davies,[9] Bridgeman,[10,11] and Young.[12] However, these studies concentrated mostly on changes of the vascular pattern of rat uterus and intracellular structures during pregnancy, not the invasive activity and/or behavior of endovascular trophoblast cells. Therefore, although the existence of endovascular trophoblast cell invasion and dilation of the placental spiral arteries in rats have been known for years, detailed information regarding the timing of trophoblast cell invasion, morphology of endovascular trophoblast cells, and structural changes of the spiral arteries is not available to date.

MATERIALS AND METHODS

Sprague-Dawley rats (Harlan SD, Dublin, VA) weighing 225-250 gram were housed in a room with 12 h light/dark cycle, and maintained at 72 ± 3 °F with relative humidity of 50 % ± 15 % in the Animal Care Facility of this institution. Rats were acclimated for a week after arrival. During study, animals had free access to water at all times. Laboratory rat chow (Ralston Purina Co., St. Louis, MO) free of known contamination were fed in accordance with standard feeding practices. All animals were individually identified with metal ear tags. Rats were assigned at random to each group after acclimation. All animal procedures were approved by the Animal Care and Use Committee at Virginia Tech. After completion of acclimation, mating was started.

All rats were observed for adverse clinical signs throughout the experiment. The mental attitude and equilibrium of each rat were observed and recorded. Clinical signs were recorded in a study notebook as well.

The day of mating was identified by vaginal washes and sperm plug formation, and designated as day 1 pregnancy. Two control animals were killed each at days 8, 10, 12, 14, 16, 18 and 20 of pregnancy under a protocol approved by the Institutional Animal

Care and Use Committee. Cytochalasin B was dissolved into a mixture of 1 % Tween 20/2% carboxymethyl cellulose[13], and 100 mg/animal was administered to pregnant rats intraperitoneally as a bolus at days 8, 9, 10 and 11. Treated rats were killed at days 12 and 20. The uterus and other tissues including liver, kidney and spleen were removed and fixed in 4 % paraformaldehyde-PBS buffered solution. Weight of fetuses and fetal resorption rate were assessed after fixation. The whole thickness of placentas including mesometrial triangle areas were cut and placed in freshly prepared fixative for a week. Thereafter, specimens were dehydrated and paraffin-embedded according to standard technique. Hematoxylin and eosin staining was performed using an automatic staining machine (Sakura stainer, Japan) to obtain consistent staining results. Selected sections were stained with periodic acid-Schiff (PAS). PAS stains carbohydrates and has been extensively used to reveal the depostion of so called "fibrinoid materials" in the vessel wall of the uteroplacental arteries. All tissue blocks were serially (5 μm) or step-serially cut (every 50 μm). Such sequential sectioning was necessary to identify placental spiral arteries and to evaluate trophoblast cell invasion into these vessels.

RESULTS

Temporal sequence of endovascular trophoblast cell invasion

At day 10, a primitive ectoplacental cone was already formed, but there was no invasion of trophoblast cells into the maternal spiral arteries. At this gestational day, spiral arteries remained to be narrow. Endovascular trophoblast cells were first observed at the opening site of the central spiral arteries at day 12 (Figure 3-1A) (page 80). They were directly from ectoplacental cone trophoblast cells. In general, endovascular trophoblast cells did not pass over the circumferential muscular layer at day 12. By day 14, trophoblast cells reached deep in the mesometrial triangle area, but remained on the inner surface of the arteries (Figure 3-1B) (page 80). Thereafter, trophoblast cells changed the

direction of their invasion toward the vessel wall and settled down in it. Consequently, the number of endovascular trophoblast cells in the lumen gradually decreased beginning from the decidual portion to the mesometrial triangle. After embedding, some trophoblast cells spread out to the surrounding interstitial space (Figure 3-1C) (page 81). This is in contrast to humans in which embedded trophoblast cells stay within the vessel wall. At day 20, few trophoblast cells were found in the luminal surface of the spiral arteries in the decidual and the superficial portions of the mesometrial triangle area, but some were in the deeper portion of the mesometrial area. Deposition of PAS positive materials in the wall of the spiral arteries gradually became apparent at day 16 and thereafter. By day 20, invaded arteries, particularly in the decidua and the giant cell layer were extensively entrapped by eosinophilic PAS positive materials (Figures 3-1D and E) (page 82). However, this phenomenon was not prominent in the deeper part of the mesometrial triangle area even at day 20. Near term, placental arteries penetrating the labyrinth and the trophospongium became a straight conduit with a diameter of more than 300 μm (so called maternal arterial space[2]), but those in the decidua and the mesometrial triangle area remained tortuous although enlarged prominently (Figure 3-1F) (page 83).

Other types of trophoblast cells

In contrast to the aggressive invasion of trophoblast cells into the maternal arterial systems, invasion of trophoblast cells into the interstitial space of the decidua was minimum throughout pregnancy. The giant trophoblast cell layer, which is the outside of the trophospongium, directly apposed to the decidua but minimally invaded the maternal tissues. As the labyrinth and the trophospongium expanded with gestation, the decidua was compressed to the circumferential muscular layer and became thin later in pregnancy.

Morphology of endovascular trophoblast cells and the effects of cytochalasin B

After invasion into the spiral arteries, four types of endovascular trophoblast cells were observed based on their morphological characteristics. At the leading tip of invasion, some trophoblast cells had strong basophilic staining with protruded cytoplasm and spindle shapes (Figure 3-2A) (page 85). This form was found only at day 12. Until day 14, however, the most predominant trophoblast cells were a 'rounded' type (Figure 3-2B) (page 85). They were frequently observed to be piled up each other. At certain points, endothelial cells beneath these trophoblast cells disappeared suddenly with no accompanying inflammatory reactions (Figure 3-2C) (page 86), but those without the contact with trophoblast cells did not. At day 14-16, many trophoblast cells became flattened against the vessel wall (Figure 3-2D) (page 86) and finally formed giant cells (Figure 3-2E) (page 87)after embedding. These giant cells were surrounded by eosinophilic PAS-positive materials (Figure 3-2F) (page 87). In general, endovascular trophoblast cells at any stages were much larger than endothelial cells, and readily distinguishable from surrounding maternal cells, and showed no mitotic activity once invaded.

When cytochalasin B was administered to pregnant rats, little endovascular trophoblast cell invasion was observed at day 12 (Figure 3-2G) (page 88). The thickness of ectoplacental cone trophoblast cells and the gross size of placentas were similar in both control and treatment groups. At day 20, treated rats had significantly smaller fetuses compared to control (2.52 gram vs. 2.8 gram, $p<0.04$). Although placentas of treated animals showed almost normal "physiological changes" of the spiral arteries and trophoblast cell invasiveness at day 20, the shape of the mesometrial triangle area was 'flattened' compared to a 'triangle' shape in normal placentas (not shown). Treated animals were clinically normal throughout treatment periods. Vehicle control rats had fetuses of normal weight and placental morphology.

Topology of endovascular trophoblast cells within the spiral arteries

At the opening site of the spiral arteries into the ectoplacental cone, trophoblast cells almost occluded the arteries at day 12 (Figure 3-1A) (page 80). Such a tight occlusion of the arteries was no longer observed at day 14. In the decidual area, endovascular trophoblast cells were more likely to distribute to the entire lumen of the spiral arteries. In contrast, in the mesometrial triangle area, they frequently distributed in a clustered form to one side of the arterial turn, particularly to the inner side of each curvature, rather than distributing uniformly to the entire luminal surface (Figures 3-3A and B) (page 90) although this is not the case of all specimens.

Venous invasion of trophoblast cells

Although one of the hallmarks of endovascular trophoblast cell invasion is considered to be its selectivity to placental spiral arteries, I have occasionally observed trophoblast cell invasion into veins, particularly those near the ectoplacental cone (Figure 3-3C) (page 91). This venous invasion was observed only at day 12 placentas and never found later in pregnancy. Trophoblast cells which invaded veins were flattened but morphologically different from those invaded the spiral arteries, lined the inner lumen, and did not pile up one another, as seen in arteries. The depth of venous invasion was generally shallow compared to arteries but sometimes reached up to the inner one third of the decidua. Invaded veins were not particularly associated with GMG cells.

Trophoblast cells and leukocyte attachment to the spiral arteries

At the time when endovascular trophoblast cells started to invade spiral arteries (day 12), a large number of leukocytes frequently attached to the endothelium of the spiral artery, but less often to veins (Figure 3-4A) (page 93). Most of them were

polymorphonuclear leukocytes. The number of leukocytes attached to the endothelium varied widely even when placentas were from the same mother. This leukocyte attachment had some correlation with endovascular trophoblast cell invasion: at day 12, the attachment was at the peak in the decidual area but not prominent in the mesometrial area. This is the time period in which the invasive activity of endovascular trophoblast cells is the highest. As gestation proceeds and trophoblast cells invade deeper portions of the spiral arteries, the shift of leukocyte attachment was observed from the decidua to the mesometrial area: at day 20, the phenomenon was not in the maternal arterial space in the labyrinth nor the trophospongium but occasionally present in the mesometrial triangle area (Figure 3-4B) (page 93). When endovascular trophoblast cells coexist, leukocytes preferentially attached to the endothelial cells (Figure 3-4C) (page 94). In addition, little leukocyte attachment was observed in vessels in non-pregnant uteri and other organs whether animals were pregnant or not (Figures 3-4D and E) (page 95). Despite a large number of leukocytes attached to the vessel walls, they appeared not to extravasate.

Priming of the spiral artery

Before endovascular trophoblast cell invasion took place, placental spiral arteries had undergone several morphological changes. At day 8, endothelial cells of decidual arteries started to hypertrophy and protruded into the lumen (Figure 3-5A) (page 97). The degree of swelling and the number of arteries that underwent these changes increased with gestation until day 12. In addition, smooth muscle cells of spiral arteries were gradually disorganized and disappeared. When endovascular trophoblast cell invasion set in motion, the placental spiral arteries were already converted from muscular arteries to those similar to veins, and difficult to recognize as arteries. These morphological changes or 'priming' were most prominent in the central placental spiral arteries and not observed in

placental veins/venules nor in any vessels in other organs examined, including liver and kidney (Figures 3-4D and E).

In addition to structural alterations, granulated metrial gland (GMG) cells started to accumulate in the area surrounding placental spiral arteries at day 10 and were most prominent at days 12-14 (Figure 3-5B) (page 97). During days 10-12, some GMG cells were under mitosis. No specific accumulation of GMG cells was observed in the implantation sites nor in the area near giant cells. GMG cells were sometimes observed within the lumen of spiral arteries (Figure 3-5C) (page 98) but not in veins. Attachment of GMG cells to the inner surface of the spiral arteries was rarely observed. There was no specific association of GMG cells with veins although there was sparse distribution of GMG in the interstitial space of both the decidua and the mesometrial triangle area. After spiral arteries had undergone morphological changes described above, GMG cell accumulation as was used as a criterion to distinguish spiral arteries from veins. GMG cells were not observed in uteri of non-pregnant rats nor in other organs during pregnancy.

As gestation proceeds, GMG cells released their eosinophilic cytoplasmic granules (Figure 3-5D) (page 99) and appeared 'exhausted' with empty cytoplasmic space with remnants of granules near the nucleus (Figure 3-5E) (page 99). This process began at the area near the ectoplacental cone in the decidua starting as early as day 12 and gradually progressed to the mesometrial triangle area. During degranulation, a small number of leukocytes sometimes accumulated in the immediate area. After degranulation, the cell volume of GMG cells increased prominently. Throughout pregnancy, GMG cells were much larger than leukocytes. After embedding, endovascular trophoblast cells invaded between these GMG cells (Figure 3-5F) (page 100).

DISCUSSION

Similarity of trophoblast cell behavior between human and rat

In this study, attention was placed on the behavior of rat endovascular trophoblast cells and resulting "physiological changes" of the spiral artery. Despite the large differences in placental anatomy and gestational days, the sequence of endovascular trophoblast cell behavior observed in this study including selective invasion into the spiral arteries, locomotion against the flow of blood, embedding into the arterial walls, and secretion of fibrinoid materials, all of these were strikingly similar to human.[1,14,15] Accordingly, behavior of endovascular trophoblast cells and resulting "physiological changes" of the spiral arteries appear to be quite similar between these two species (Figure 3-6). In addition, I observed 'priming' effects of spiral arteries prior to endovascular trophoblast cell invasion, and similar priming effects are also observed in humans.[16] Furthermore, GMG cells accumulated and became a predominant cell type in rat placentas.[9] These cells have been considered to be a cell population equivalent to large granular lymphocytes (LGL), the major leukocytes in the decidua basalis in early human pregnancy.[17] Accordingly, in addition to endovascular trophoblast cell behavior, the spiral arteries and the environmental keys surrounding the spiral arteries may be quite similar between these two species.

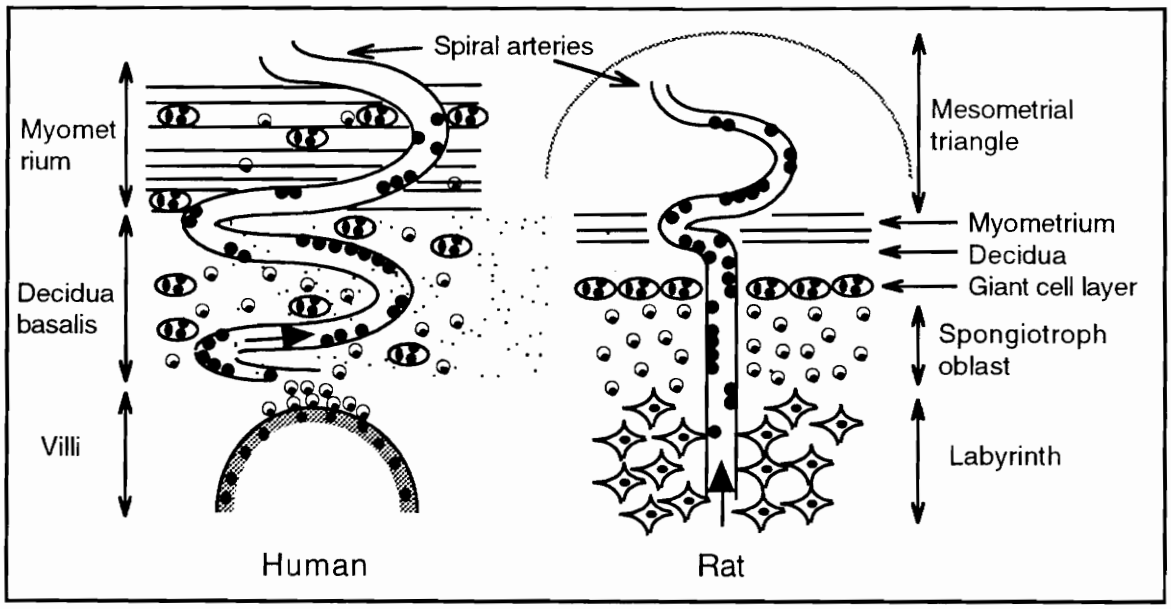

Figure 3-6. Comparison of trophoblast cell invasiveness between human and rat. In humans, both interstitial and endovascular trophoblast cells invade deep into maternal tissues. In contrast, rats have only single pathway of invasion, endovascularly. However, behavior of endovascular trophoblast cells and "physiological changes" of the spiral arteries are very similar between these two species.

Comparison of trophoblast invasion to leukocyte trafficking

Since both leukocytes and trophoblast cells interact with endothelial cells, the similarity of endovascular trophoblast cell behavior with those of leukocyte trafficking/homing and tumor metastasis has recently been emphasized.[18,19] However, it should be noted that there are both similarities and differences. For example, leukocytes attach to the activated or primed endothelial cells of venules, passively roll down, and migrate through the vessel wall or diapede into the interstitial space. In contrast, trophoblast cells adhere to the primed spiral arteries, actively scroll up on the surface in a retrograde manner, and are embedded in the vascular walls. These differences may arise from the different physiological purposes between leukocytes and trophoblast cells.

Leukocytes utilize the vasculature as a simple PATH for their transportation from the blood stream to the interstitial space. On the other hand, endovascular trophoblast cells interact with the endothelium to induce "physiological changes" of the spiral arteries, which help adequate "physiological exchanges"[20] of nutrients and gases between the mother and fetus by inducing "physiological changes" of the invaded spiral arteries. Accordingly, for trophoblast cells, vessels appear to be not a path but a final TARGET.

In the following, each step of trophoblast cell invasion and that of leukocyte trafficking will be compared.

Priming effects

During immune and inflammatory crisis, leukocytes always extravasate ONLY from activated or primed endothelial cells.[6] Morphologically, 'priming' consists of swelling of endothelial cells, protrusion into the lumen and having a cobble-like appearance. These changes are considered to be important to modify a laminar flow into a turbulent one, which increases the chances of contact between circulating leukocytes and the endothelial cell surface.[21] In addition to structural alterations, primed endothelial cells also undergo functional changes by expressing an array of CAM to recruit leukocytes with corresponding ligands.[6, 22]

In pregnant rats, endothelial cells of the spiral arteries hypertrophied prominently and acquired a cobble-like appearance. These changes occurred before trophoblast cell invasion. Similar changes are also reported in the spiral arteries of other species during pregnancy including humans.[23,24,25] Endothelial cells were not the only target of 'priming' effects during pregnancy. Before endovascular trophoblast cell invasion, smooth muscle cells of the plaental spiral arteries were disorganized and disappeared. Moreover, the large number of GMG cells accumulated around the spiral arteries. Because of close association of GMG cells with the spiral arteries, they have apparently some important effects on the structure and function of the spiral arteries and/or trophoblast cell invasion. Interestingly, GMG cells showed striking morphological changes, which were correlated with trophoblast cell invasion/behavior.

The origin of GMG cells

In the past, GMG cells have been considered to be a natural killer lineage and their immunological relevance such as cytotoxicity to trophoblast cells was argued based on *in vitro* studies.[26,27] However, recently the antigenic profile of GMG cells was reviewed and GMG cells were proposed to belong to a novel class of the leukocyte population.[28]

At present, the origin of GMG cells are still controversial and considered to be either from the systemic circulation or transformed from decidual cells. If GMG cells belong to the leukocyte population and come from the circulation, they should get into the placentas from venules where leukocyte trafficking occurs and need to move to spiral arteries through the interstitial space. However, I have never observed attachment/accumulation of GMG cells to or around veins. Indeed, accumulation of GMG cells was always restricted to the spiral arteries from the beginning. In addition, despite the large number of leukocytes attached to the endothelial cells of the spiral arteries, attachment of GMG cells was rare. These morphological data strongly suggest that GMG cells are transformed from decidual cells *in situ* during pregnancy, not from the circulation.

One of the possible roles of GMG cells may be to help placental spiral arteries dilate prominently in a short period of time. Such a goal may be accomplished by replacing connective tissues around the spiral arteries and by increasing their cell volume with empty space under light microscope, which provides room for arterial expansion.

Attachment

As mentioned previously, as a part of "priming" effects in leukocyte trafficking, activated endothelial cells express CAM. Therefore, the spiral arteries may also express CAM to help endovascular trophoblast cells attach to them. Indeed, in humans, selective expression of CAM has been demonstrated on the spiral arteries of the decidua basalis in the first trimester placenta.[19,29] In support of this hypothesis, a large number of leukocytes was seen to be attached to the spiral arteries at the same time that trophoblast cells attached. This suggests that during rat pregnancy, placental spiral arteries express adhesive phenotypes or CAM and both trophoblast cells and leukocytes have corresponding ligands.

At present, the significance of leukocyte attachment to the spiral artery in rat pregnancy is unknown. They may modulate the surface structures of the endothelium or might happen to adhere to the 'sticky' endothelium because of a possible multiplicity of molecules that mediate cell to cell interaction. Leukocyte adhesion to the endothelium is generally regarded as an 'adhesion cascade' in which each step initiates amplification and regulation beginning from adhesion through extravasation, as in clotting and complement cascades.[6] However, this model does not appear to apply to placentas of pregnant rats since the sequence is arrested at the initial event or attachment and transendothelial migration of leukocytes was not generally observed. The reason for this dichotomy remains to be elucidated.

Previously, venous invasion of trophoblast cells was not reported in pregnant rats. However, I could sometimes observe venous invasion. I do not think that the phenomenon is physiologically important since the invasion was observed only at day 12 placentas, and veins did not show any morphological changes thereafter. Similar features are also demonstrated in human and macaque.[30,31]

Morphology of endovascular trophoblast cells and scrolling

Scrolling on the endothelium is unique to trophoblast cells and are not observed in any other cell types. However, its underlying mechanisms are little known or even poorly investigated. First of all, I categorized endovascular trophoblast cells into four types based on morphology: (1) spindle, (2) round, (3) flattened, and (4) giant cell forms. A spindle form may represent the most invasive type of trophoblast cells since it was observed only at the time the invasive activity of endovascular trophoblast cells is the highest, and particularly at the leading tip of invasion. However, in general, 'round' type trophoblast cells were a predominant cell type until day 14 and are considered to have the ability to migrate. This type of trophoblast cell is shown to have numerous filopodia

extended to the endothelium.[14,32] I am not sure round type trophoblast cells are an actual form *in vivo* or post-mortem artifacts since cells within the arterial circulation are expected to receive some degrees of morphological deformity due to arterial blood flow. Since such a deformity is passive, post-mortem morphology of trophoblast cells may not reflect actual forms *in vivo*.

Nevertheless, regardless of morphology, assembly of actin filament beneath plasma membranes appears crucial in the locomotion of trophoblast cells. Indeed, bundles of actin-like filament are shown in endovascular trophoblast cells under electron microscopy.[14] Therefore, to examine the roles of cytoskeleton, I administered an actin-disorganizing agent, cytochalasin B to pregnant rats. Similar to amoebae and *in vitro* eucaryotic cell locomotion,[33,34] endovascular trophoblast cell movement *in vivo* was, indeed, sensitive to cytochalasin B in this study, supporting a hypothesis that fundamentally similar mechanisms may underlie cell movement of a diverse range of cell types.

Since trophoblast cell invasion was impaired by the treatment when the fetuses were still small, the effect of cytochalasin B was not fatal. Instead, fetal growth might have been just delayed. Consequently, the weight of fetuses might not reach that of normal pregnancy at day 20. Since cytoskeleton B also affects cell mitosis, the results of cytochalasin treatment may be due to suppression of trophoblast cell proliferation. However, in this study, the thickness of ectoplacental cone trophoblast cell layers was the same in both control and treatment groups. In addition, endovascular trophoblast cells did not show any mitotic activity even in normal pregnancy. Accordingly, the invasive activity of endovascular trophoblast cells appears to be sensitive to cytoskeleton disrupting agents.

Possible physiological roles of "spiral" arteries in endovascular trophoblast cell migration

Finally, the topology of endovascular trophoblast cells within the spiral arteries may provide some clues regarding physiological roles of the unique structure of "spiral" arteries, if any. The spiral arteries are found in the uterus only in animals with hemochorial placentation. Therefore, it deserves more than a casual glance. Marais assumed that the "spiral" arteries cause strong turbulence and hypothesized that turbulence activates fibrinolysis and helps maintain the blood supply to the intervillous space.[35] However, the opposite is true (activation of coagulation systems and acceleration of thrombosis). Therefore, his remark regarding turbulence has received little attention since then. However, the effects of turbulence in the spiral arteries may be reevaluated in terms of endovascular trophoblast cell behavior.

In this respect, by comparing endovascular trophoblast cell behavior to leukocyte trafficking once more, we may obtain some insights. Leukocyte attachment to the endothelial cells is a function of (1) the expression of CAM and (2) sluggish blood flow near the endothelium. The results of this study strongly suggest the expression of CAM on the spiral arteries because of selective attachment of both trophoblast cells and leukocytes to the same vessels. However, endovascular trophoblast cells interact with endothelial cells of the spiral arteries, where the flow of blood is much faster than venules. It is only in venules that leukocytes and immune cells are able to attach to the endothelium and diapede. On the other sites, they may be washed away. This is one of the most critical differences between endovascular trophoblast cell behavior and leukocyte trafficking. How did the mother develop the mechanisms that help endovascular trophoblast cells attach to and migrate on the arterial environment?

As Marais speculated, blood flow in the spiral artery is expected to be turbulent. Turbulent flow creates many spots of a nidus near the surface of the endothelium, which may serve as a 'preferred site' for endovascular trophoblast cells to settle down. Also

because of turbulence and eddy current, trophoblast cells may sometimes pile up. In contrast, if the spiral artery were a straight artery, blood flow is expected to be laminar and endovascular trophoblast cells may form a monolayer on the endothelium to reduce flow resistance. In other words, under a laminar flow condition, the formation of such a 'clump' of trophoblast cells requires lots of energy. The topology of endovascular trophoblast cells reported in the literature[36,37,38] and the current observations support the former.

In addition to turbulence, blood flow in the spiral artery is apparently asymmetrical; the flow is fastest in the outside of a curvature, and slowest in the inside. Therefore, to reduce shear stress, trophoblast cells are expected to distribute to the inside of each curvature. My observation on the topology of endovascular trophoblast cells support this assumption. Trophoblast cells preferentially distributed to the inner side of each turn of spiral arteries in the mesometrial portion. However, in the decidual portion, this topological relationship was not clear: the entire lumen was frequently surrounded by trophoblast cells. This may be due to the effects of the occlusion of the opening site of placental spiral arteries by trophoblast cells themselves, which may effectively reduce arterial flow significantly to the degree that the effects of shear stress is minimum. Because of this sluggish flow environment, trophoblast cells may be able to migrate all the way through the decidual portion of spiral arteries for a short time period. However, since arterial occlusion disappears later in pregnancy, endovascular trophoblast cells in the mesometrial portion may become subject to hemodynamic stress, resulting in asymmetrical distribution, as described above. In conclusion, three mechanisms (turbulence, asymmetric flow distribution and occlusion) are considered to be advantageous for endovascular trophoblast cell migration by providing a nidus, area of low shear stress and slow flow conditions, respectively. Since the former two are related to the unique structure of spiral arteries, the spiral structure of the "spiral" arteries are advantagenous for endovascular trophoblast cell migration.

Summary

In conclusion, based on the similarity of endovascular trophoblast cell behavior and physiological changes between human and rat, rats may serve as an acceptable and economical animal model for the study of underlying mechanisms of endovascular trophoblast cell behavior.

Figure 3-1. Endovascular trophoblast cells were invading the central spiral artery which was surrounded by GMG cells at day 12 (A), and reached deep in the arteries in the mesometrial triangle area at day 14 (B). At this gestational day, "physiological changes" were not yet observed. Thereafter, trophoblast cells settled in the vessel walls, then they migrated into the interstitial space (C). At day 20, "physiological changes" were fully developed (D) with fibrinoid deposition (E). Converted arteries remained tortuous in the decidua and the mesometrial triangle area, but straight in the labyrinth and trophospongium area (F).

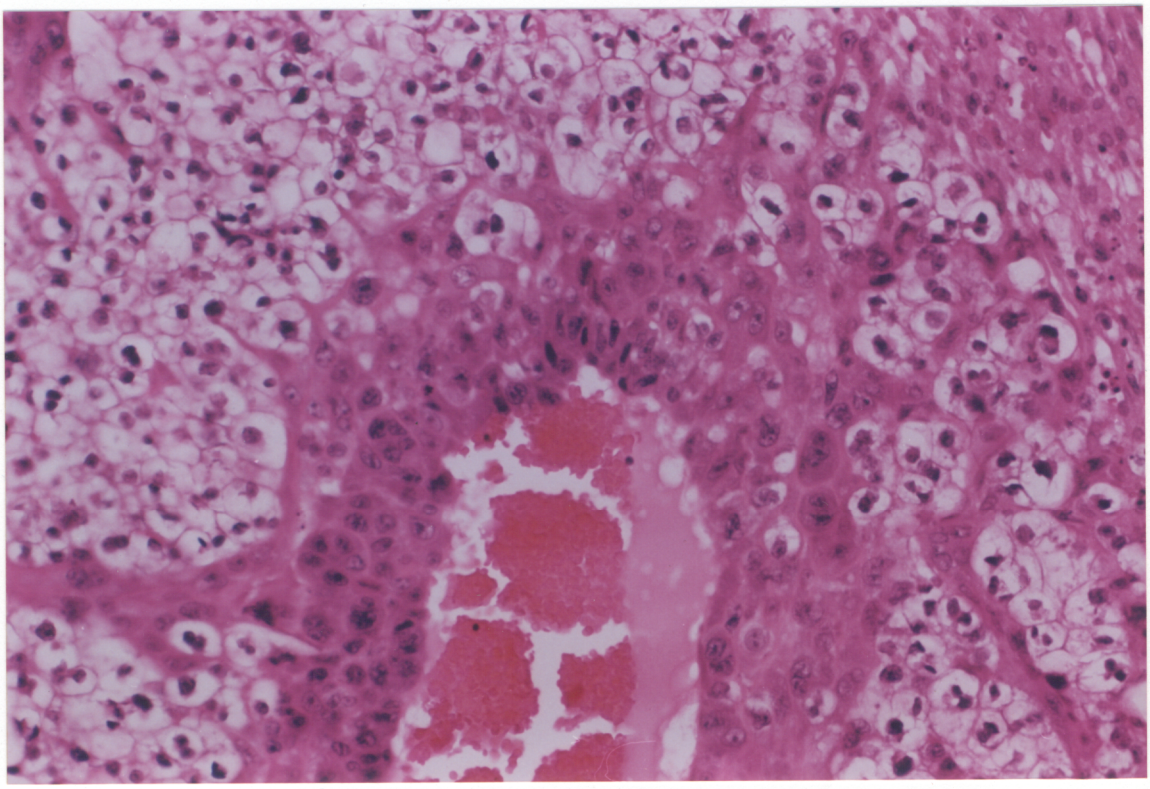

Figure 3-1C. (x 500) HE staining.

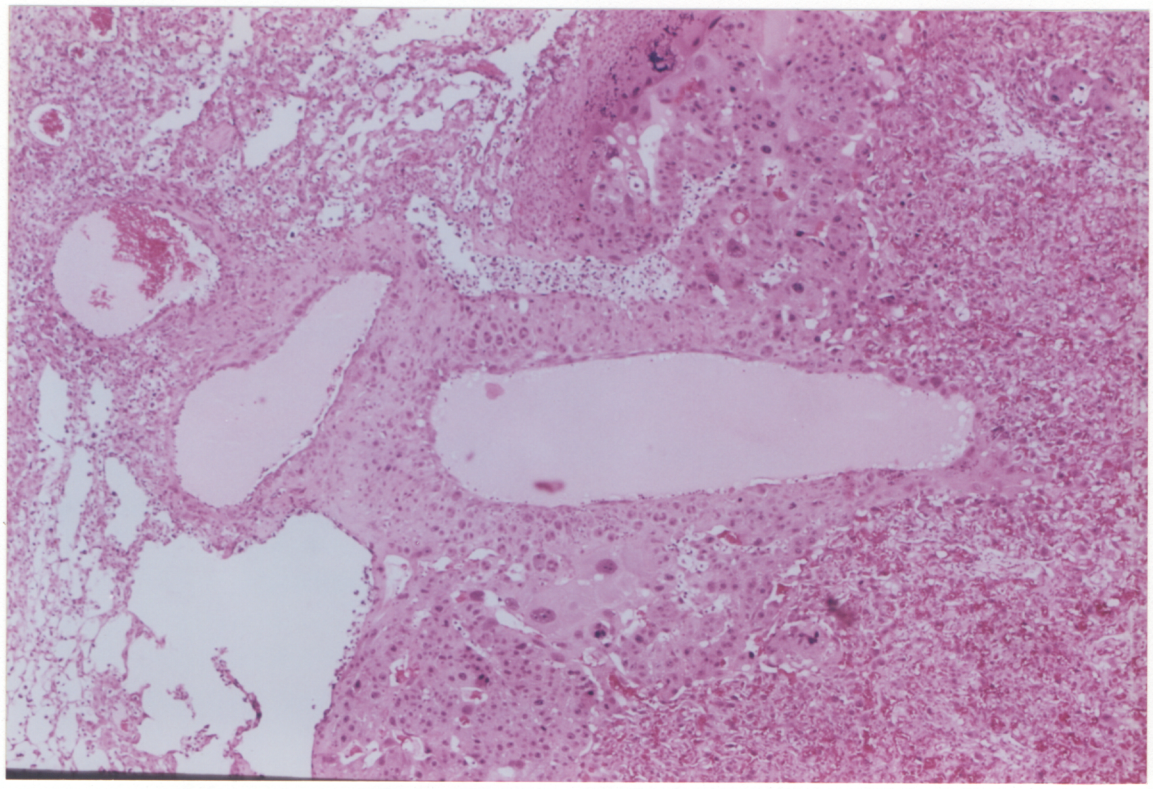

Figure 3-1D. (x 200) HE staining.

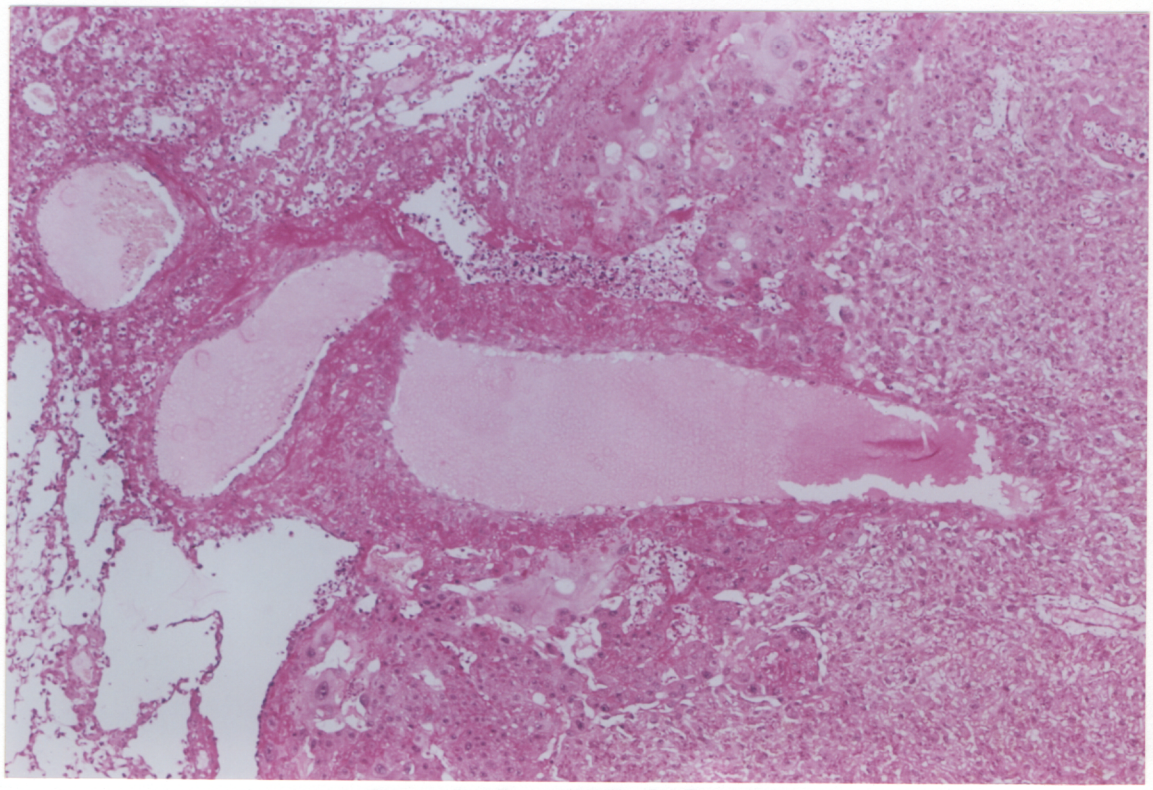

Figure 3-1E. (x 200) PAS staining.

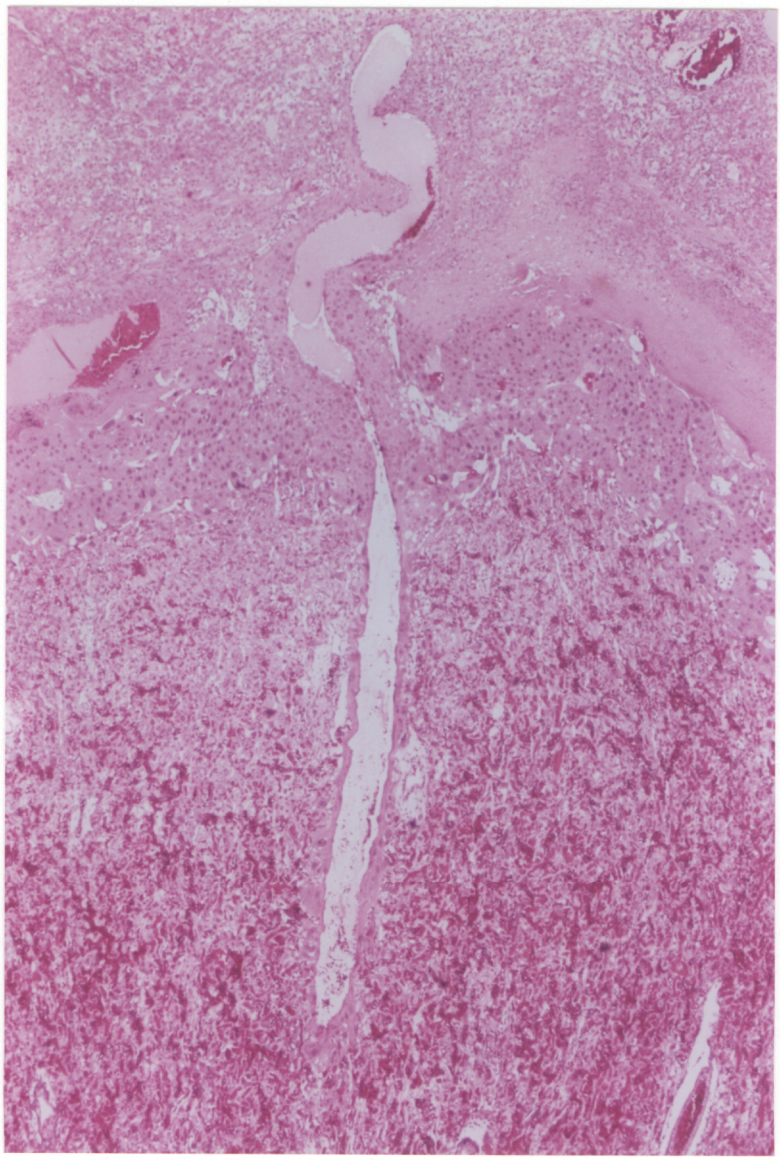

Figure 3-1F. (x 200) HE staining.

Figure 3-2. Some endovascular trophoblast cells were basophilic and had a spindle shape at the leading tip of invasion at day 12 (A) although the majority of trophoblast cells were a round type at days 12-14 (B). As gestation proceeds, endothelial cells beneath endovascular trophoblast cells disappeared with no trace of inflammatory reactions (C). Eventually, trophoblast cells became flattened against the vessels (D) and settled down in the vessel walls (E). Ginat cells were surrounded by PAS positve mateirlas (F). CB treated rats had spiral arteries of a narrow caliber with no endovascular trophoblast cells at day 12 (G).

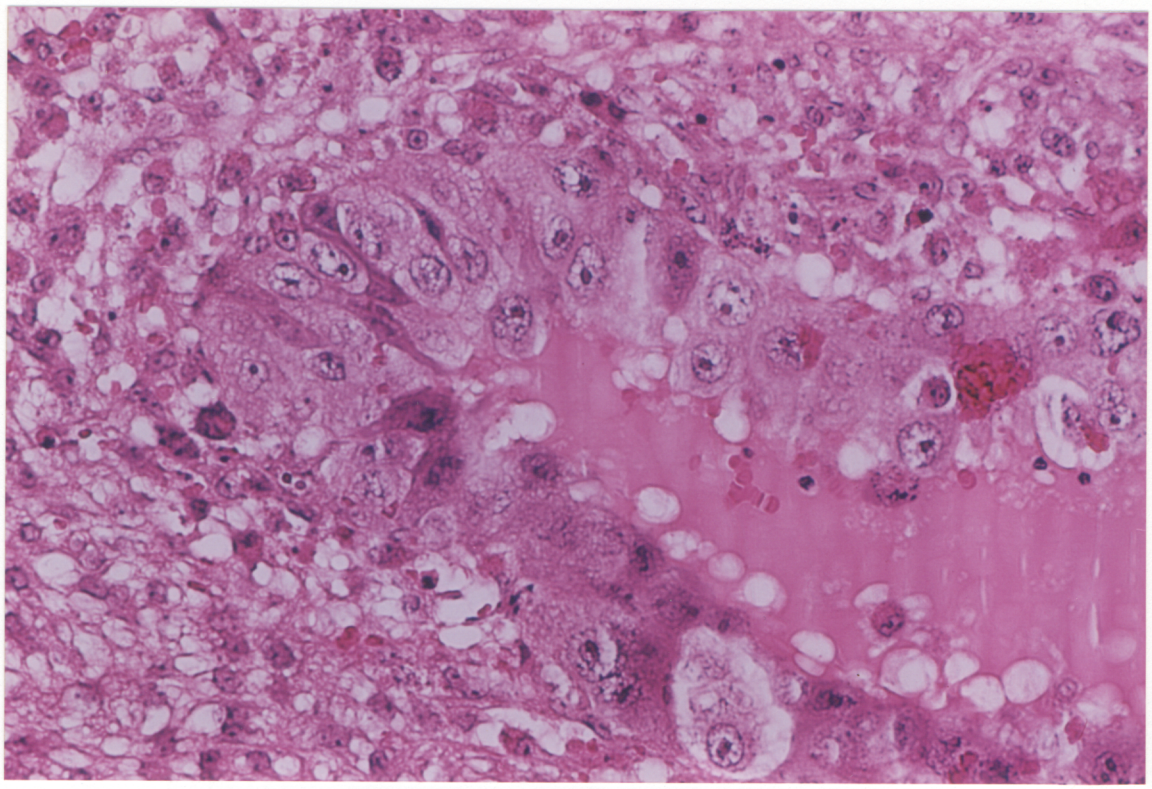

Figure 3-2A. (x600) HE staining.

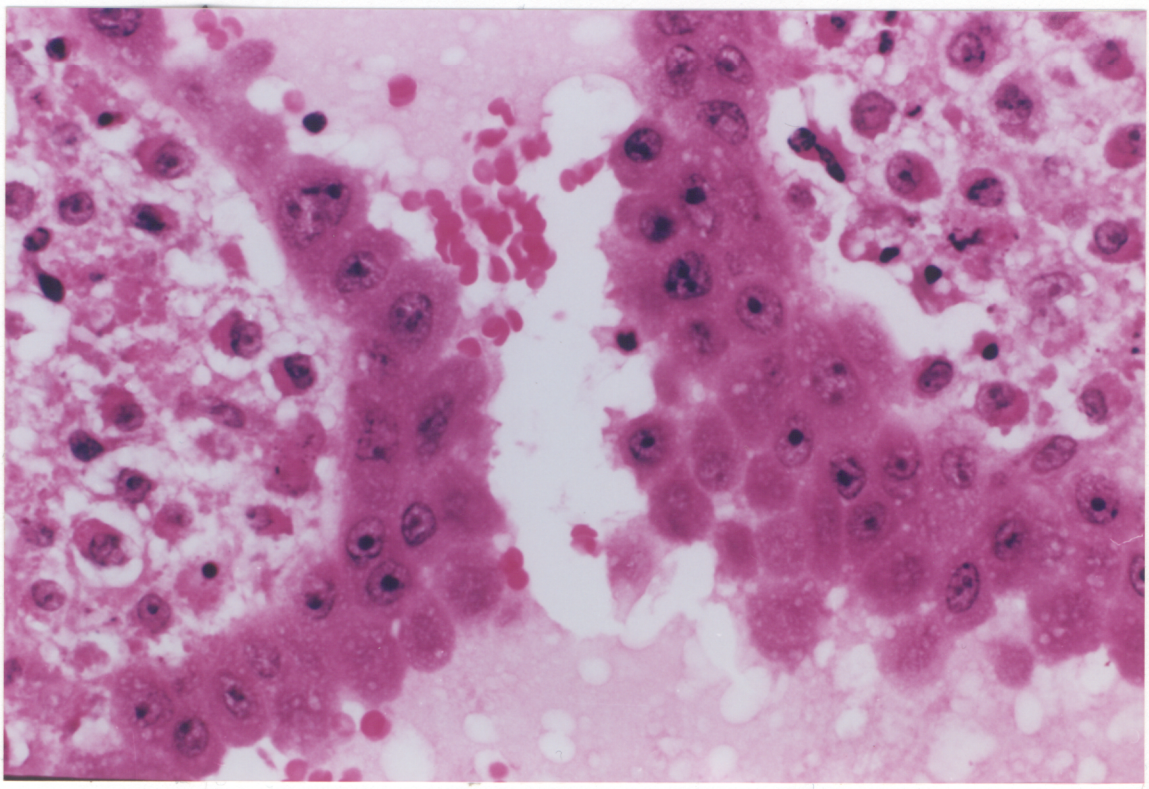

Figure 3-2B. (x 1320)

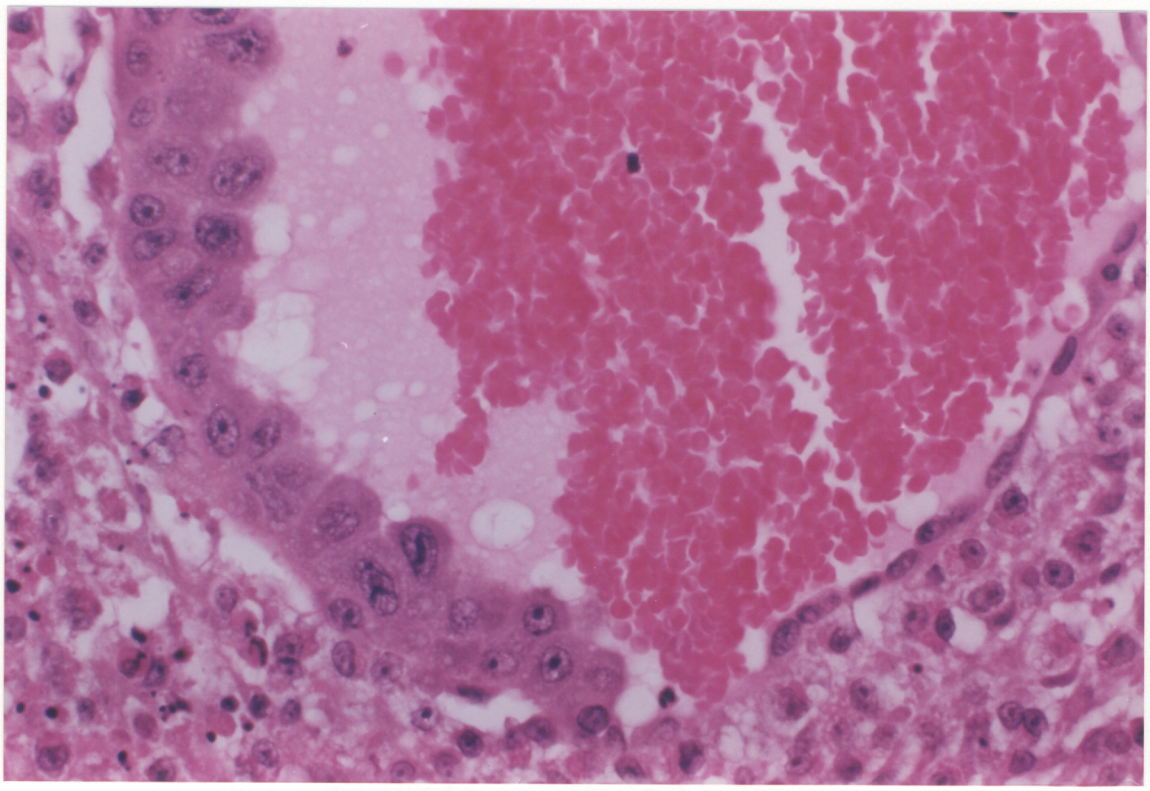

Figure 3-2C. (x 1000) HE staining.

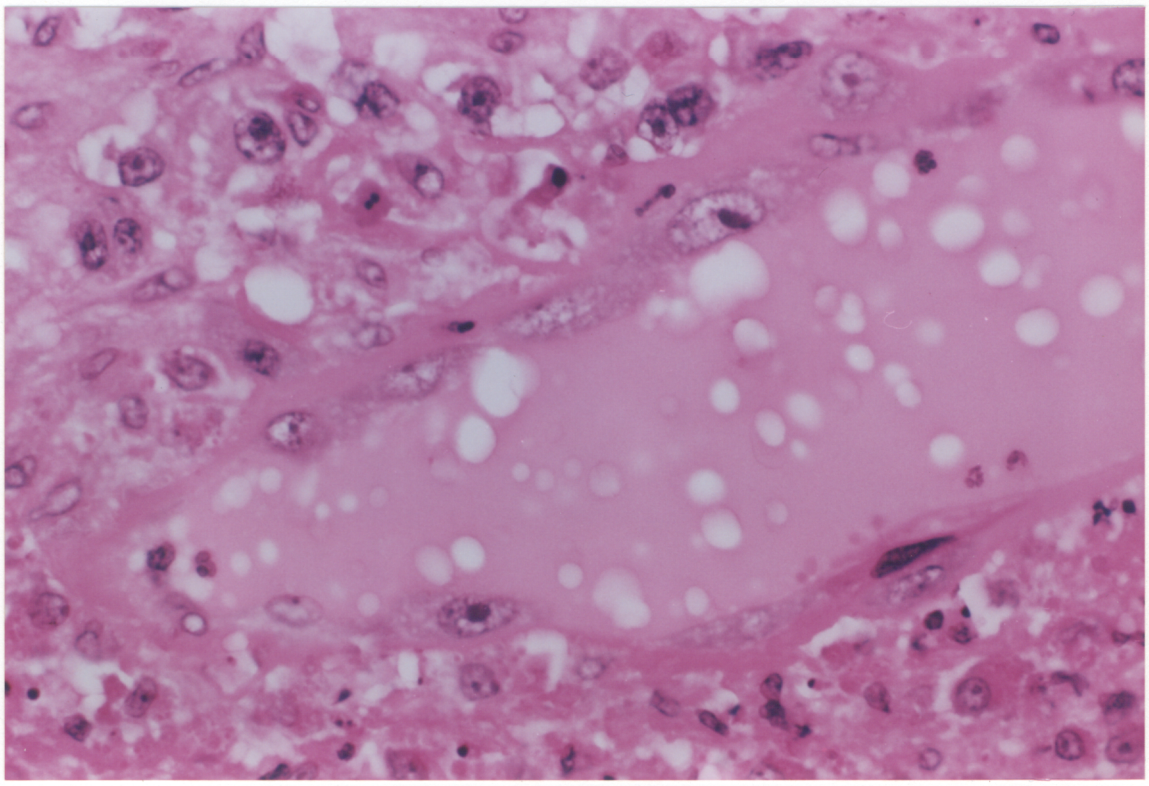

Figure 3-2D. (x 1320) HE staining.

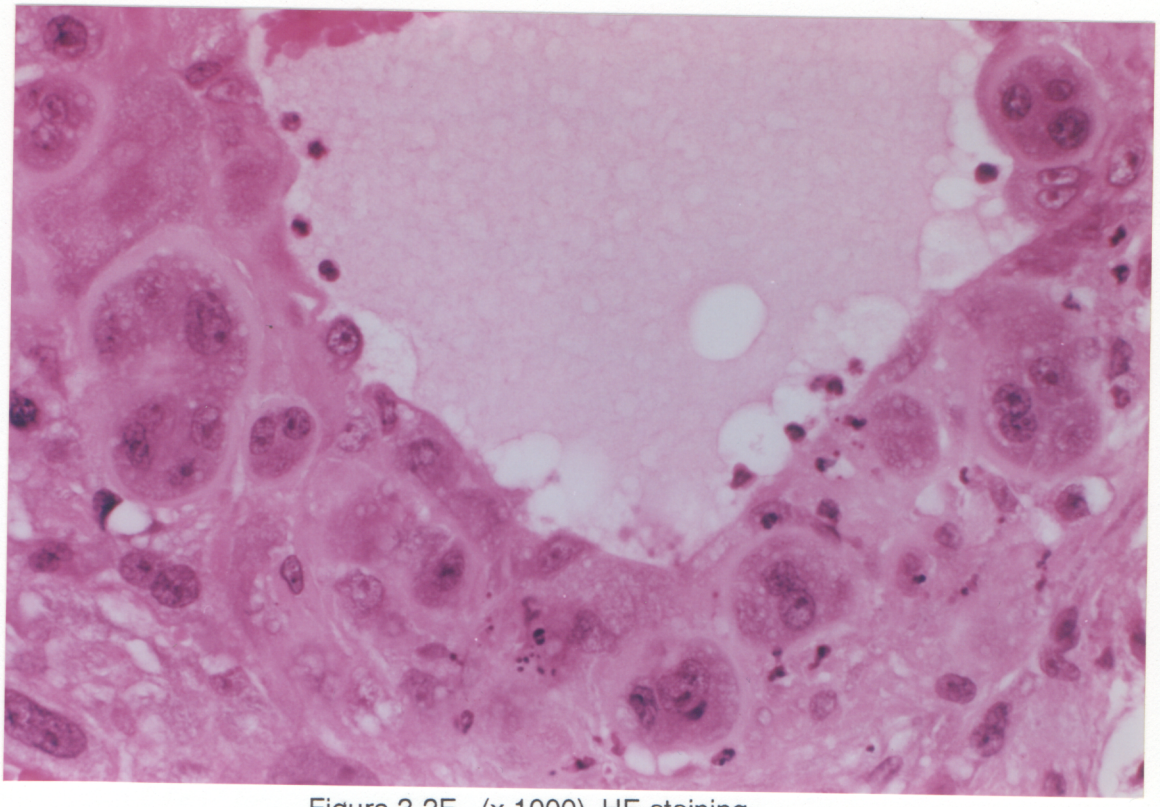

Figure 3-2E. (x 1000) HE staining.

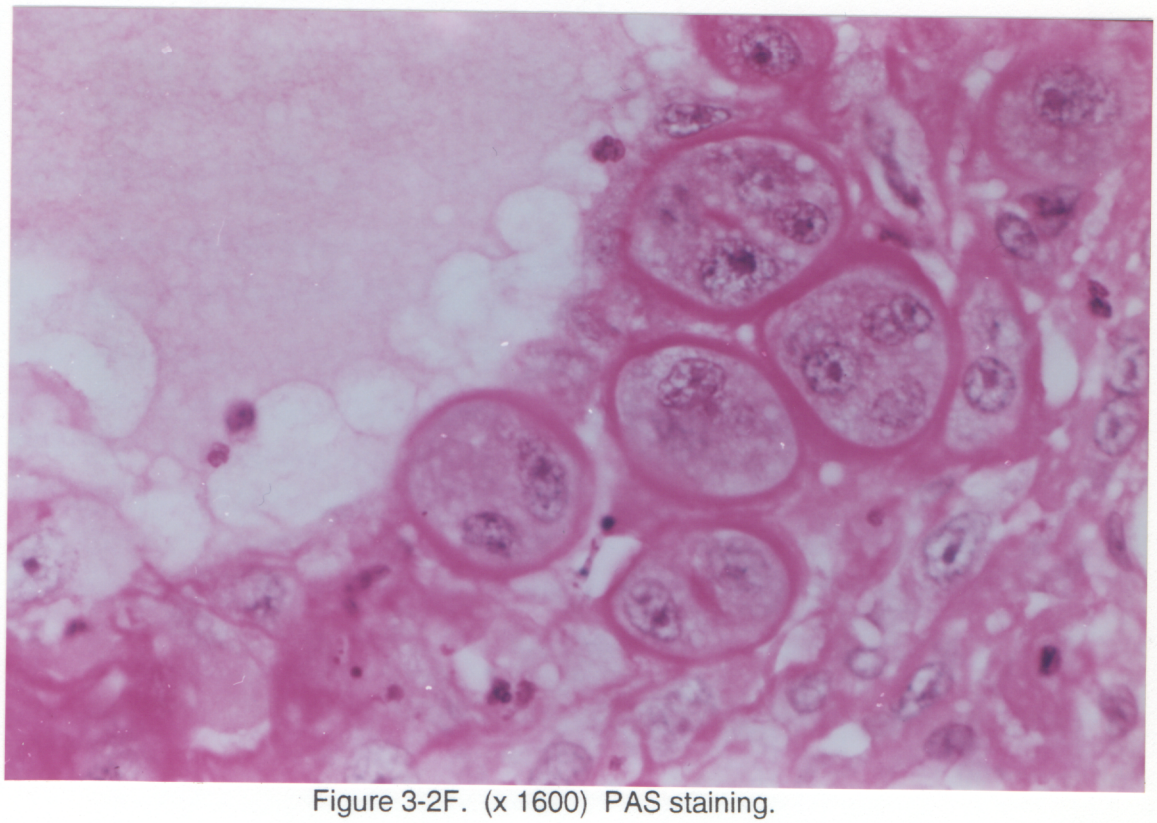

Figure 3-2F. (x 1600) PAS staining.

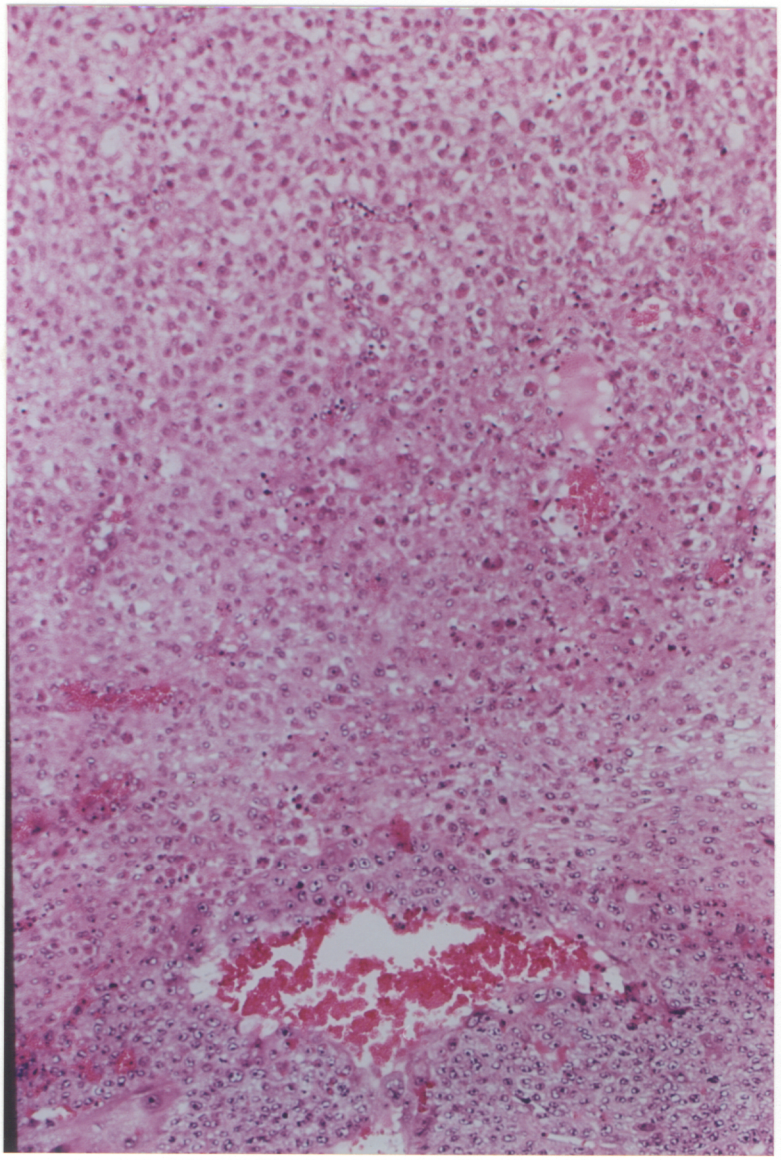

Figure 3-2G. (x 250) HE staining.

Figure 3-3. Endovascular trophoblast cell preferentially distributed to the inside of each turn in the mesomestrial triangle area (A and B). Venous invasion of trophoblast cells was observed only at day 12 (C). A-B - H&E staining.

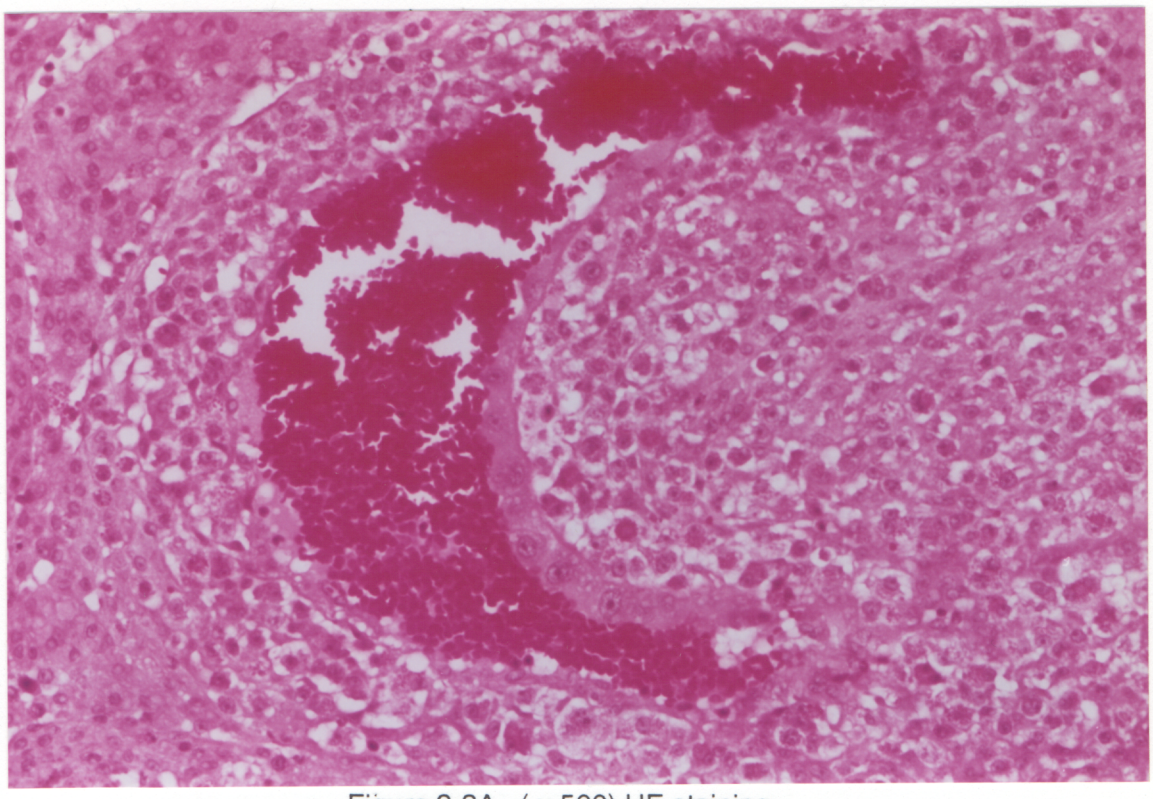

Figure 3-3A. (x 500) HE staining.

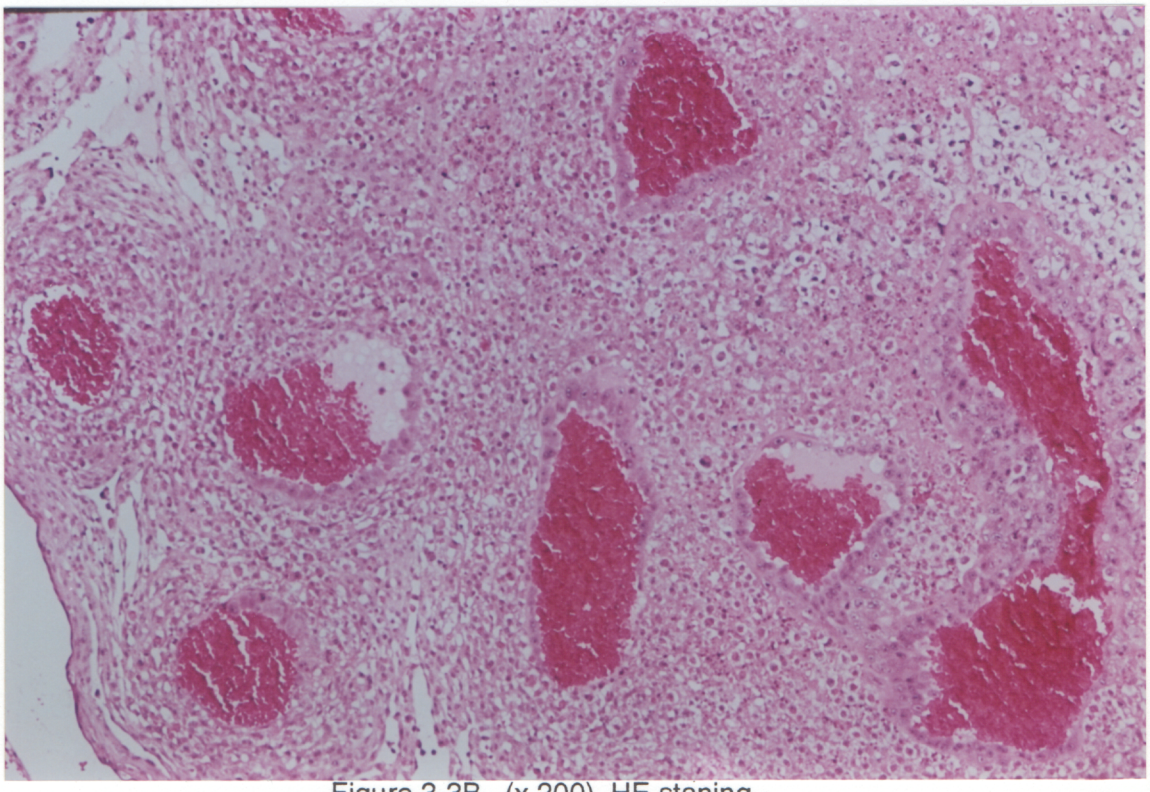

Figure 3-3B. (x 200) HE staning.

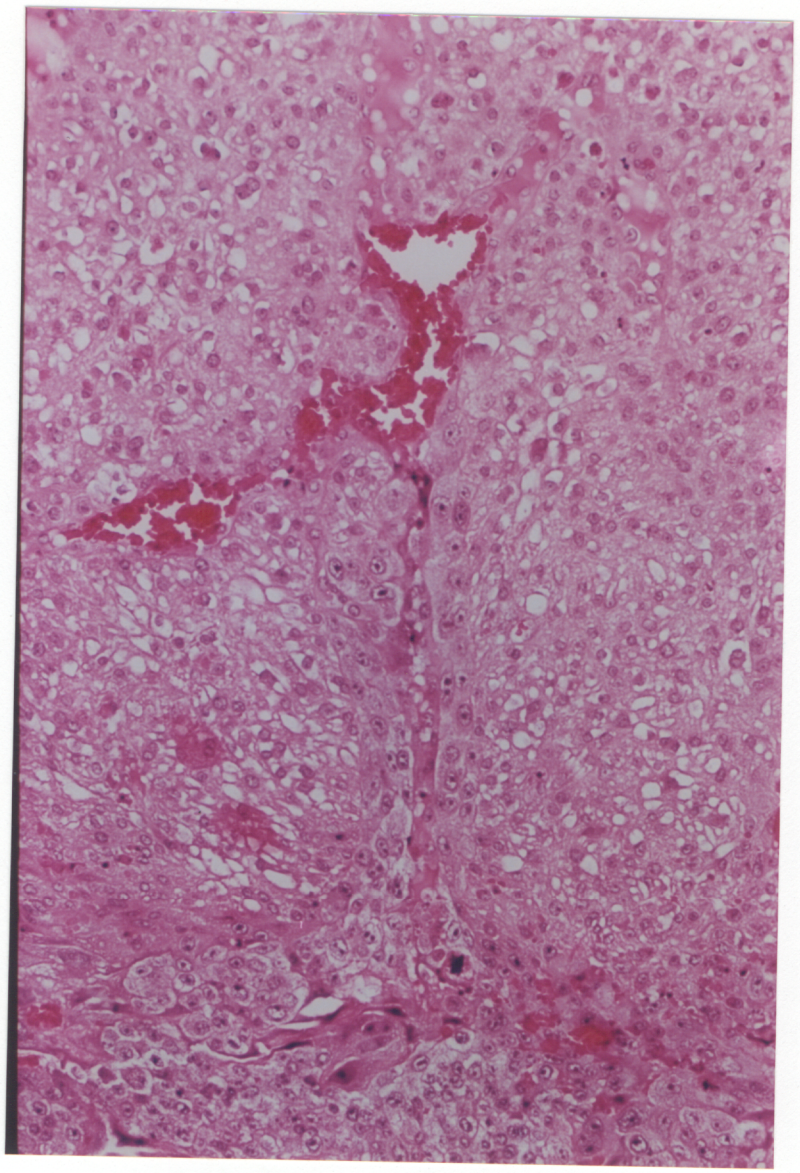

Figure 3-3C. (x 400) HE staining.

Figure 3-4. The entire lumen of the spiral artery had leukocytes attached - day 12 (A). Leukocyte attachment was sometimes observed even at day 20 (B). Leukocytes appeared to have preference to the vascular endothelium over endovascular trophoblast cells (C). Leukocyte attchment was not observed on the spiral arteries of non-pregnant animals (D). Also both an artery and a vein of the kidney of a pregnant rat had no leukocytes attached to the vessel wall (E). A-E - H&E staining.

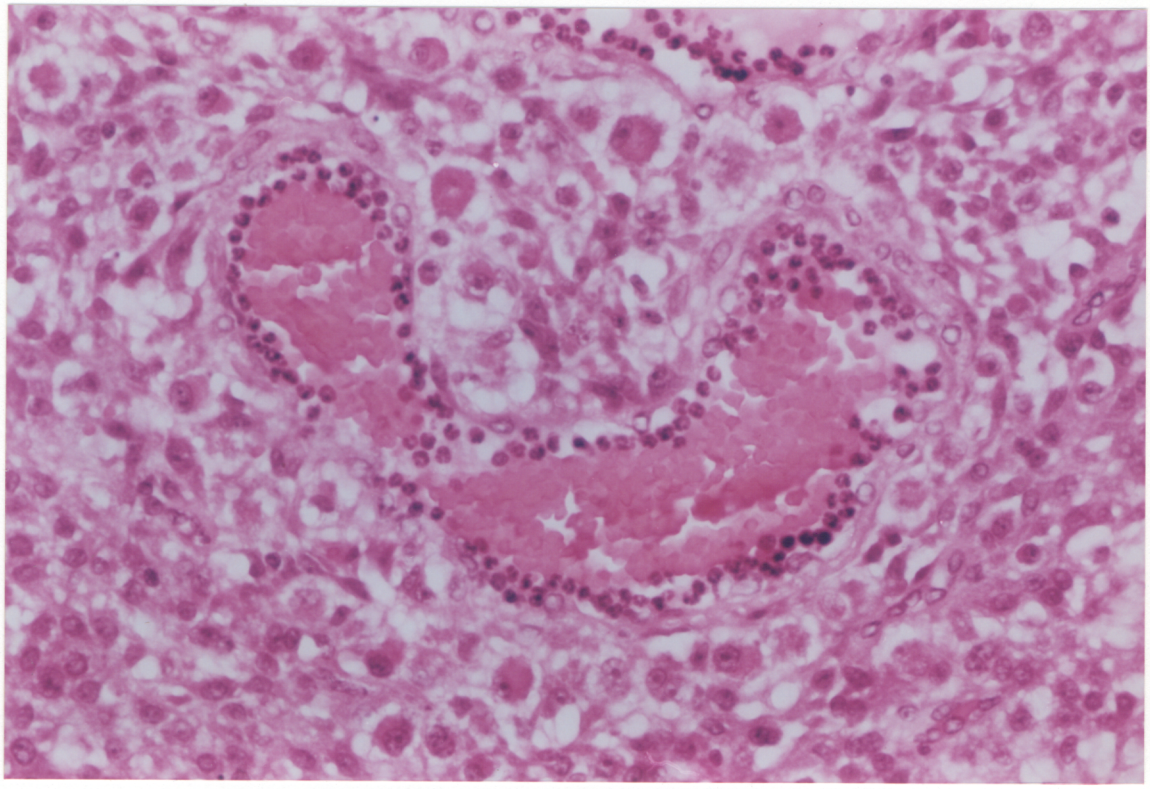

Figure 3-4A. (x 800) HE staining.

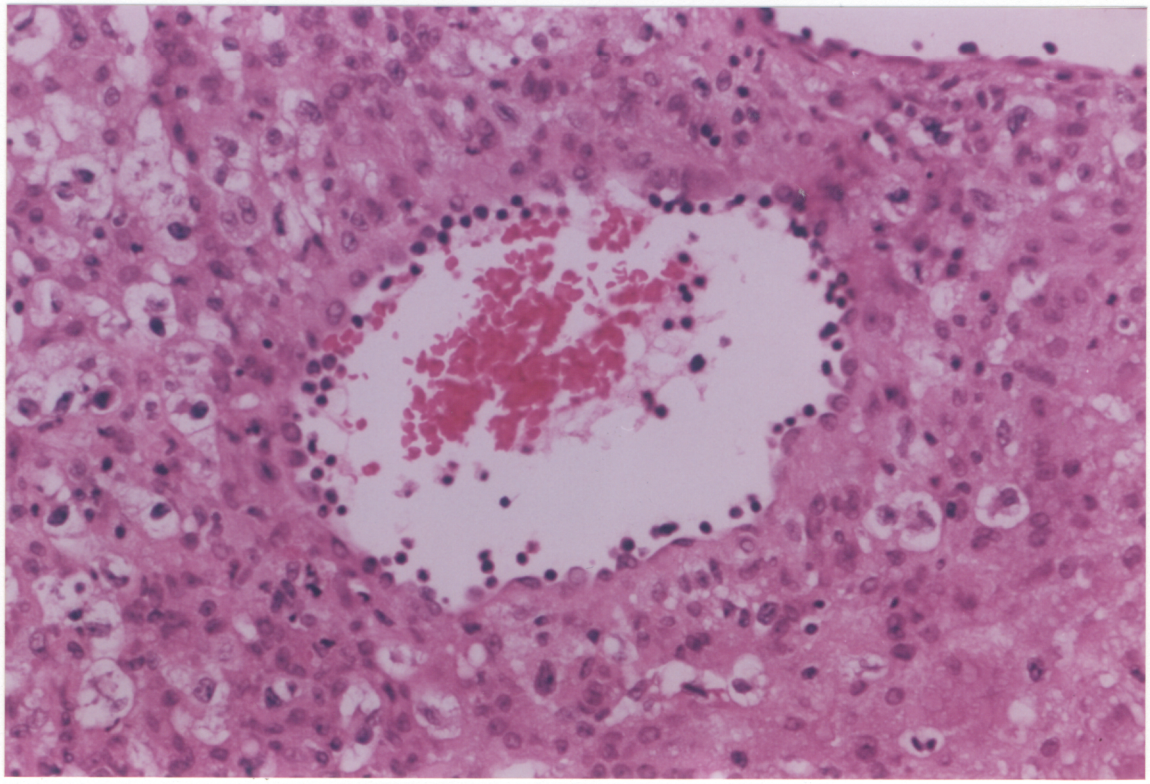

Figure 3-4B. (x 660) HE staning.

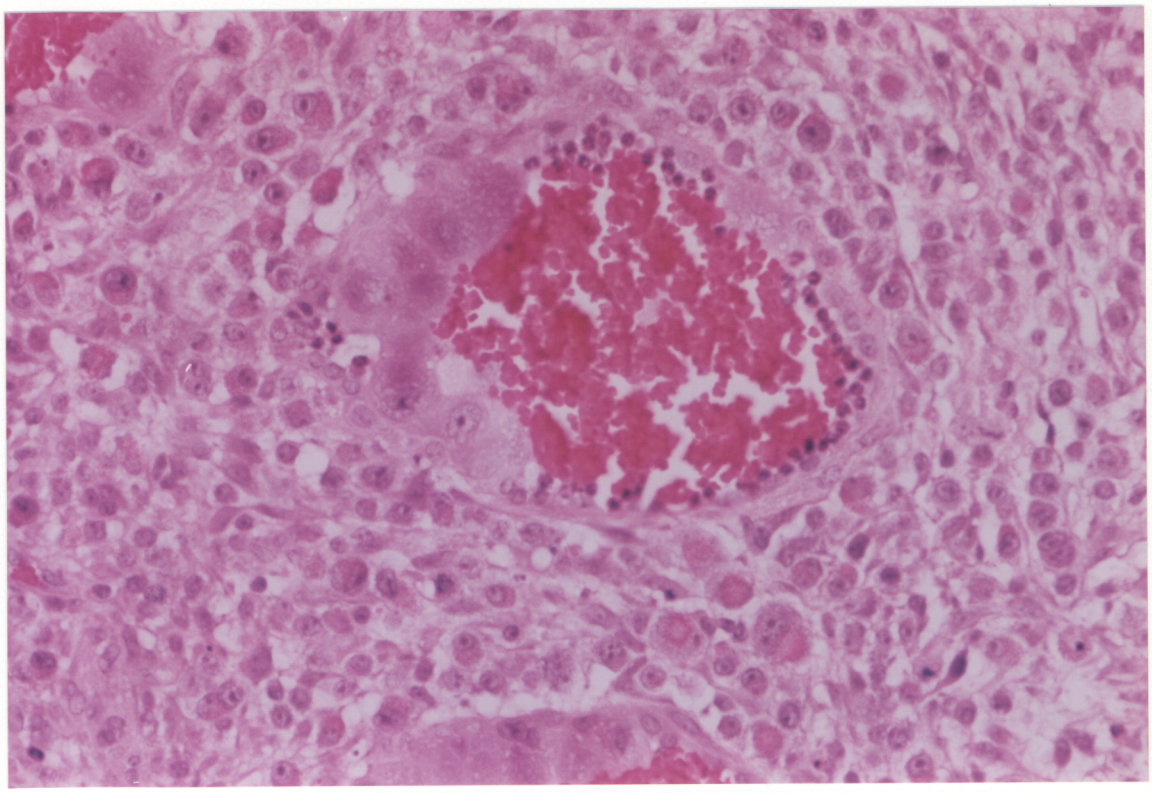

Figure 3-4C. (x 660) HE staining.

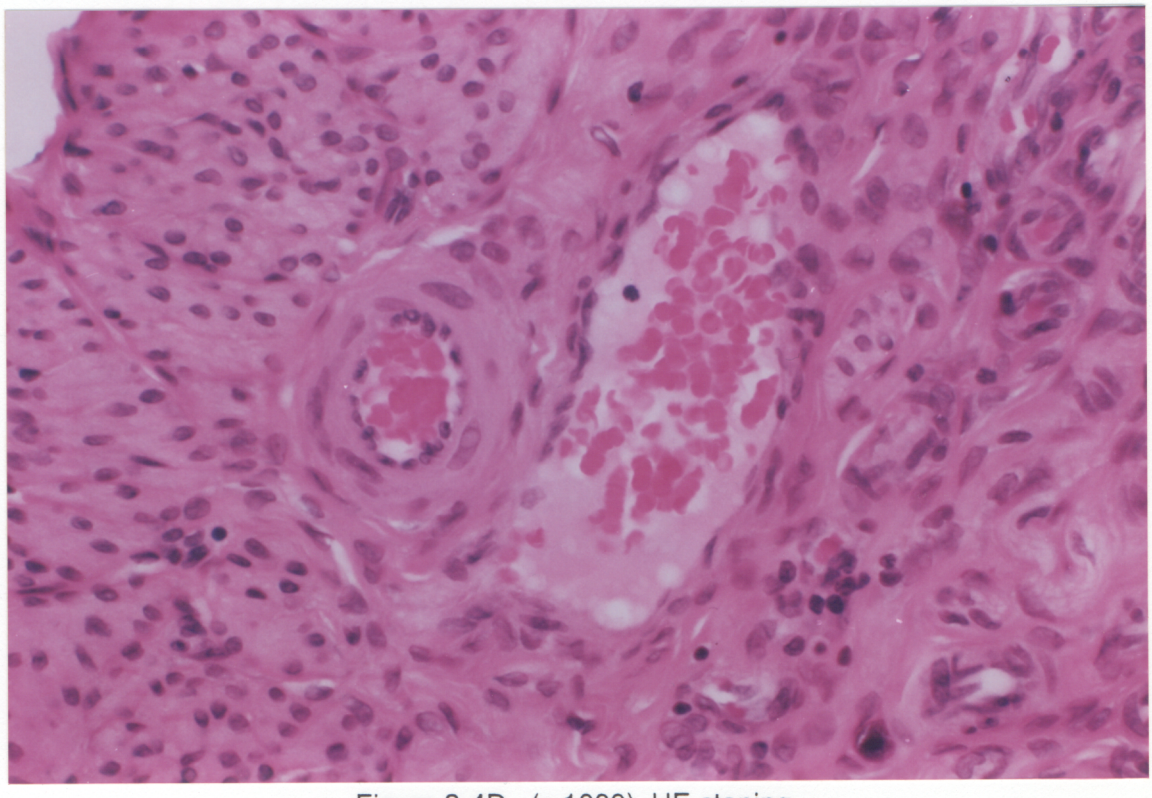

Figure 3-4D. (x 1000) HE staning.

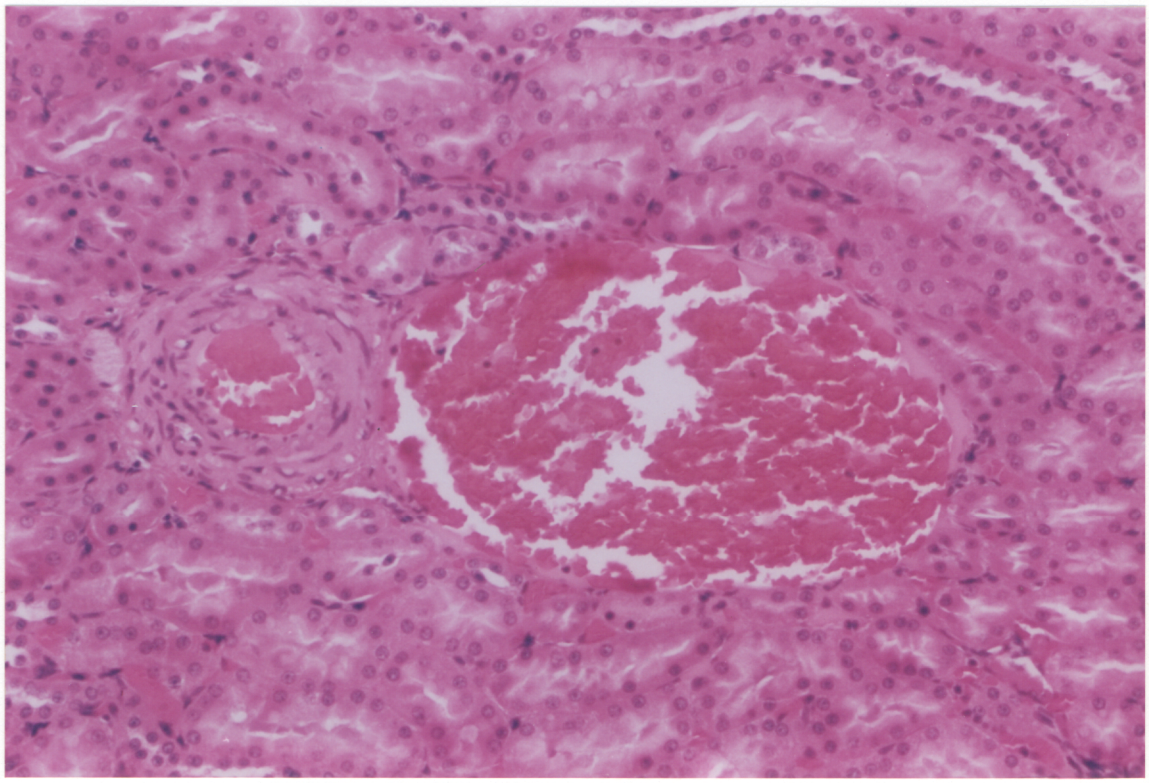

Figure 3-4E. (x 500) HE staining.

Figure 3-5. A placental spiral artery did show 'priming' effects at day 12 (A). The spiral arteries were surrounded by a large number of GMG cells at day 12 (B). GMG cells were frequently found within the arteries (C). The size of GMG cells increased as gestation proceeds (D = day 12, E = day 16, F = day 20). A-F - H&E staining.

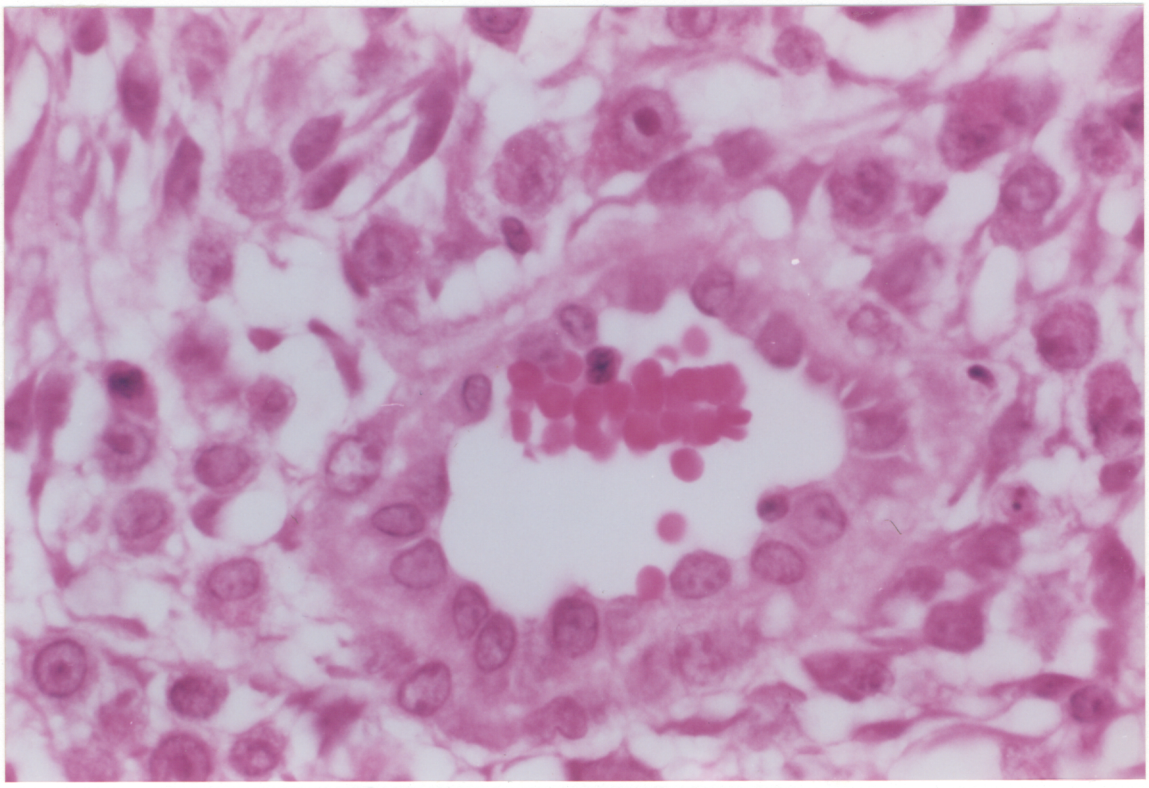

Figure 3-5A. (x 2000) HE staining.

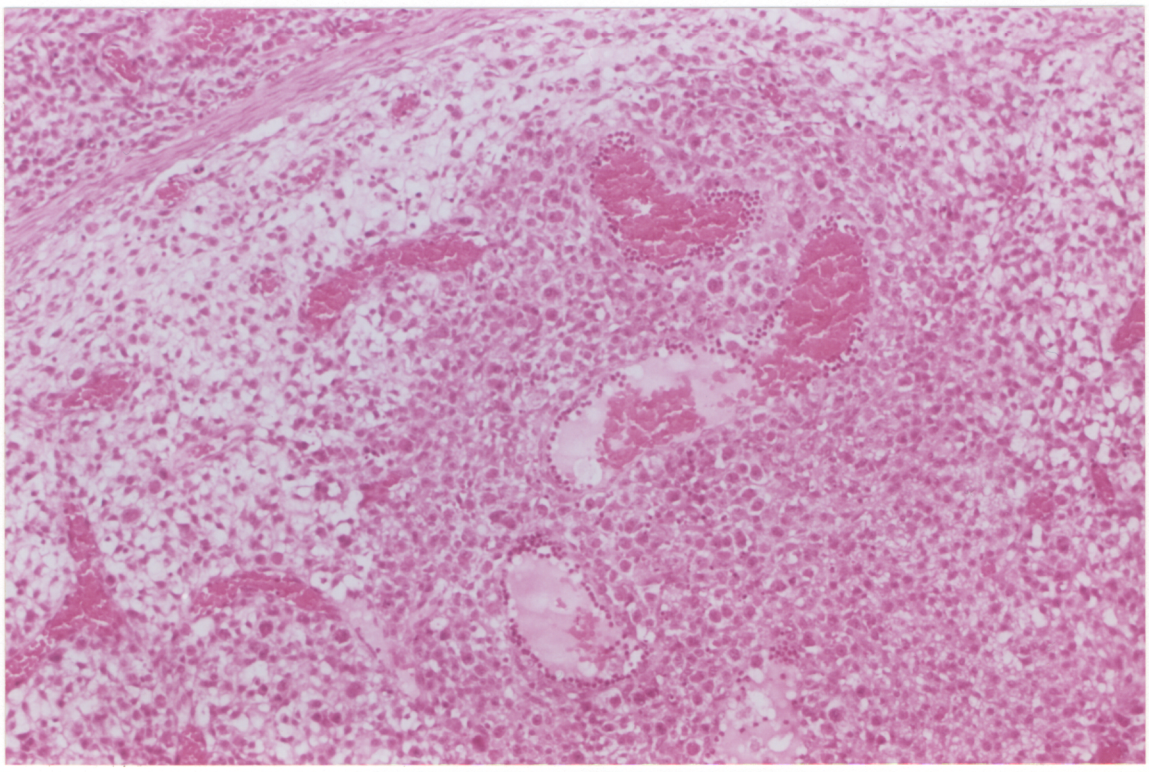

Figure 3-5B. (x 250) HE staning.

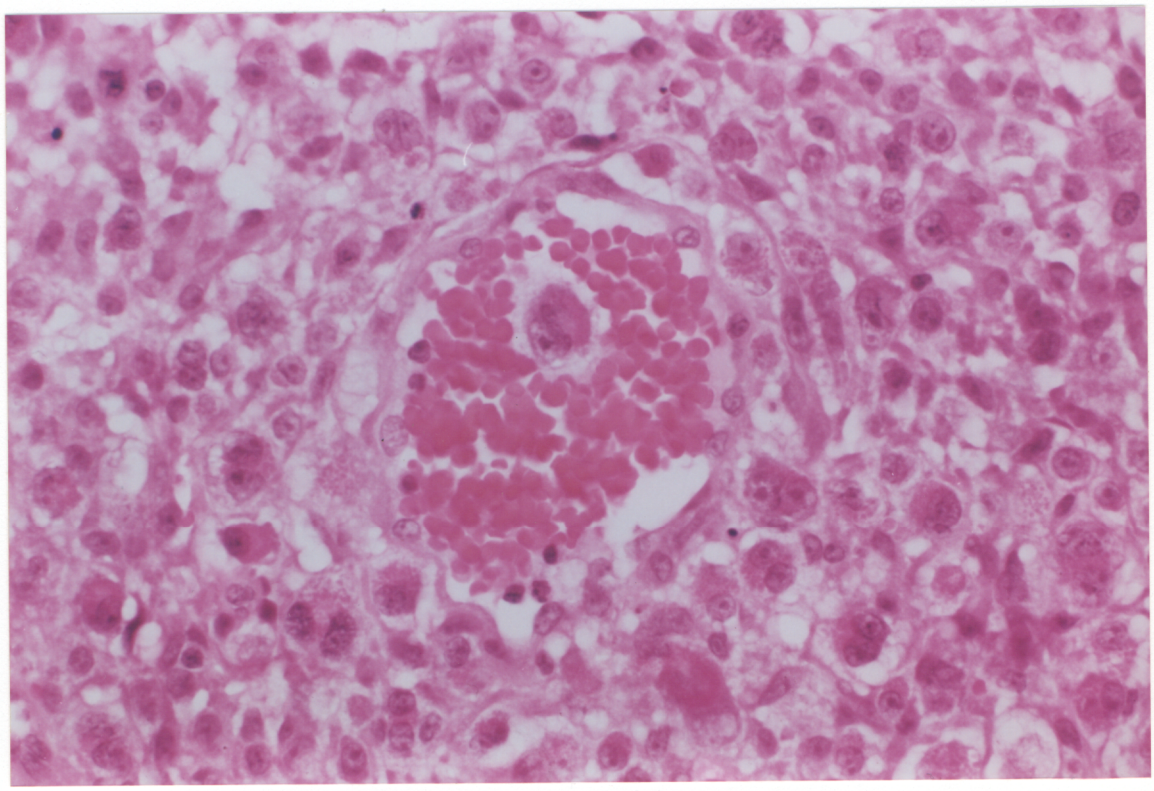

Figure 3-5C. (x 1000) HE staining.

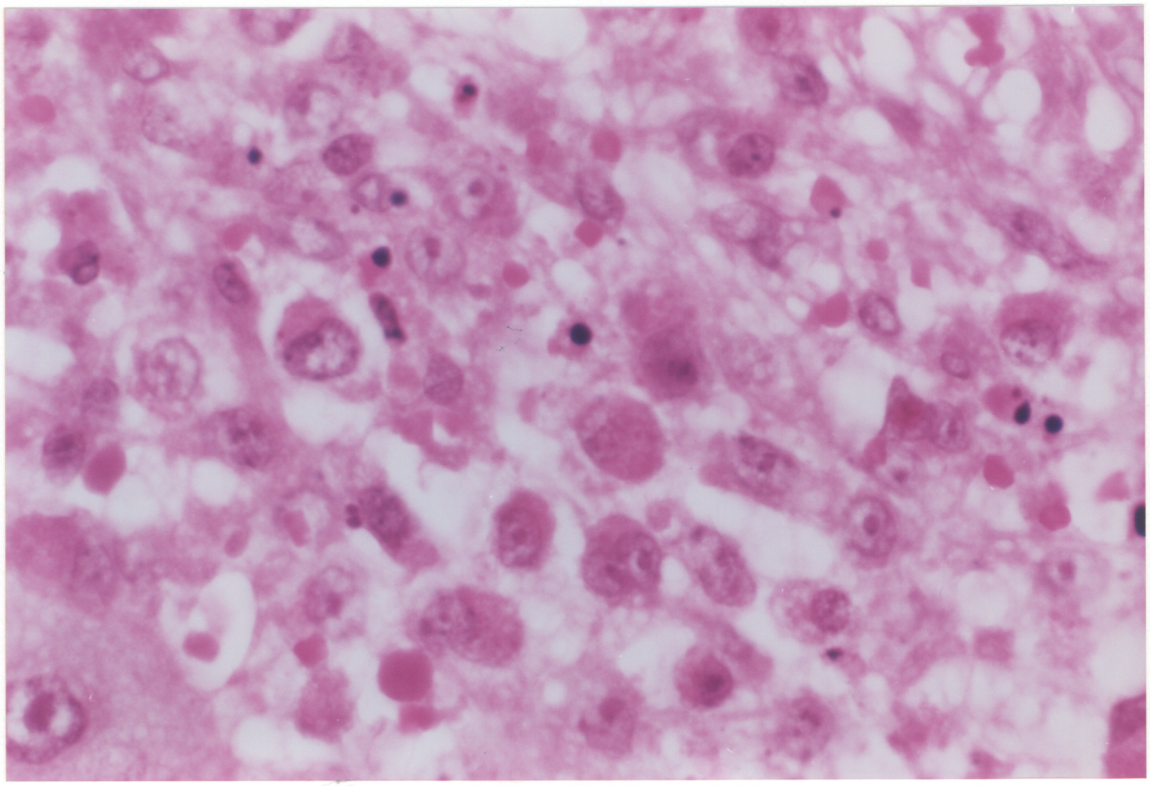

Figure 3-5D. (x 2000) HE staining.

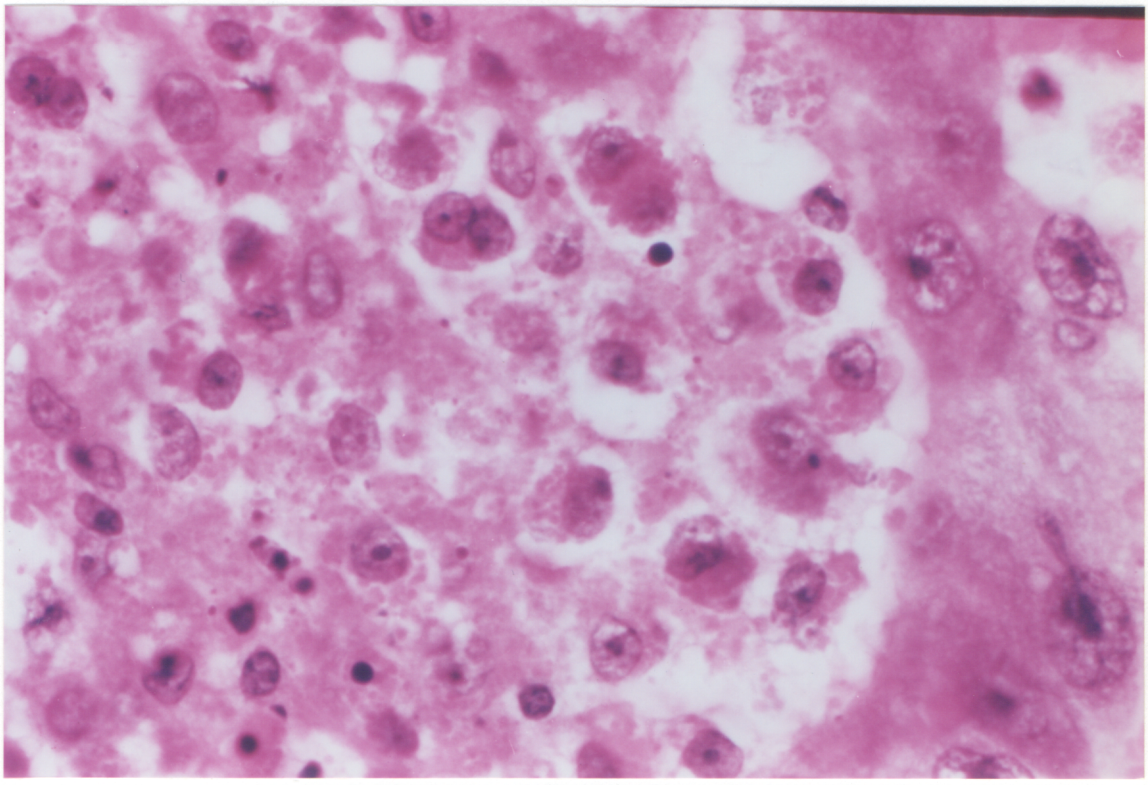

Figure 3-5E. (x 2000) HE staning.

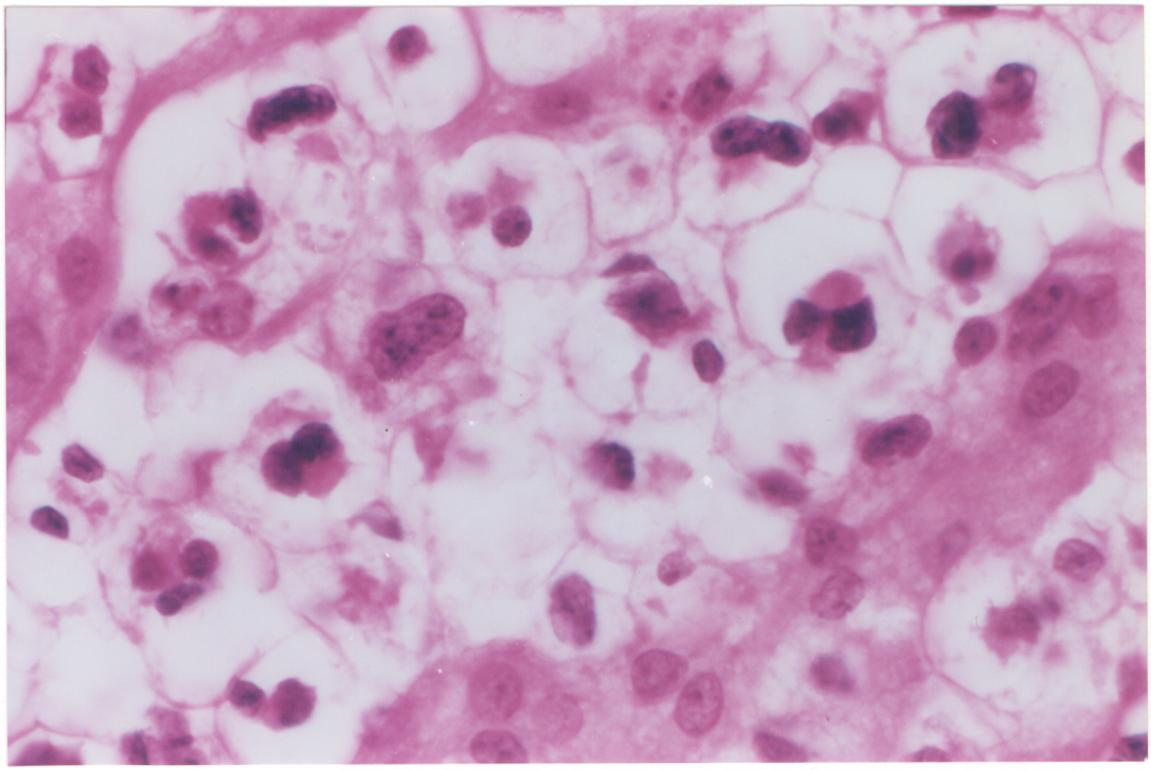

Figure 3-5F. (x 2000) HE staining.

REFERENCES

[1] Brosens I, Robertson WB, Dixon HG. The physiological response of the vessels of the placental bed to normal pregnancy. J Path Bact. 1967;93: 569-79.

[2] Pijnenborg R, Robertson WB, Brosens I, Dixon G. Review article: Trophoblast invasion and the establishment of hemochorial placentation in man and laboratory animals. Placenta. 1981;2:71-92.

[3] Alberts B et al. (ed). The cytoskeleton. In: Molecular biology of the cell. New York, Garland Publishing. 1994. p787-861.

[4] Bousquet PF, Paulsen LA, Fondy C, Lipski KM, Loucy KJ, Fondy TP. Effects of cytochalasin B in culture and in vivo on murine Madison 109 lung carcinoma and on B16 melanoma. Cancer Res. 1990;50:1431-9.

[5] Watanabe N, Tsukada N, Smith CR, Phillips MJ. Motility of bile canaliculi in the living animal: implications for bile flow. J Cell Biol. 1991 Jun; 113(5): 1069-80.

[6] Shimizu Y, Newman W, Tanaka Y, Shaw S. Lymphocyte interactions with endothelial cells. Immunol Today. 1992;13:106-12.

[7] Khong TY, De Wolf F, Robertson WB, Brosens I. Inadequate maternal vascular response to placentation in pregnancies complicated by preeclampsia and by small-for-gestational age infants. Br J Obstet Gynaecol. 1986;93:1049-59.

[8] Berkowitz RS, Goldstein DP. Gestational trophoblastic disease. In: Moosa AR et. al. (ed). Comprehensive textbook of oncology. Baltimore, Williams & Wilkins Co. 1989.

[9] Holmes RP, Davies DV. The vascular pattern of the placenta and its development in the rat. J Obstet Gyn Br Emp. 1948;55:583-607.

[10] Bridgeman J. A morphological study of the development of the placenta of the rat. I. An outline of the development of the placenta of the white rat. J Morphol. 1948;83:61-85.

[11] Bridgeman J. A morphological study of the development of the placenta of the rat. II. An histoplogical and cytological study of the development of the chorioallantoic placenta of the white rat. J Morphol. 1948;83:195-223.

[12] Young A. The vascular architecture of the rat uterus during pregnancy. Trans Roy Soc Edinb. 1956;63:167-83.

[13] Lipski KM, McQuiggan JD, Loucy KJ, Fondy TP. Cytochalasin B: Preparation, analysis in tissue extracts, and pharmacokinetics after intraperitoneal bolus administration in mice. Analytical Biochemistry. 1987;161: 332-40.

[14] Orsini MW. The trophoblastic giant cells and endovascular cell associated with pregnancy in the hamster *Cricetus auratus*. Am J Anat. 1954:94:272-331.

15 Carpenter SJ. Trophoblast invasion and alteration of mesometrial arteries in the pregnant hamster: Light and electron microscopic observations. Placenta 1982;3:219-242.

16 Brettoner A. Zum Verhalten der Sekundaren Wand der Uteroplacentargefasse bei der decidualen Reaktion. Acta anatomica. 1964;57:367-76.

17 Stewart IJ. Granulated metrial gland cells: pregnancy specific leukocytes? J Leuk Biol. 1991;50:198-207.

18 Blankenship TN, Enders AC, King BF. Trophoblastic invasion and the development of uteroplacental arteries in the macaque: immunohistochemical localization of cytokeratins, desmin, type IV collagen, laminin, and fibronectin. Cell Tissue Res. 1993;272:227-36.

19 Burrows TD, King A, Loke YW. Expression of adhesion molecules by endovascular trophoblast and decidual endothelial cells: Implications for vascular invasion during implantation. Placenta. 1994;15: 21-33.

20 Mossman HW. Comparative morphogenesis of the foetal membranes and accessory uterine structures. Contrib Embriol Carneg Instn. 1937;26: 129-246.

21 De Bruyn PPH, Cho Y. Structure and function of high endothelial postcapillary venules in lymphocyte circulation. In;Current topics in pathology. 84/1.

22 Springer TA. Adhesion receptors of the immune system. Nature 1990;346:425-33.

23 De Wolf F, De Wolf-Peeters C, Brosens I, Robertson WB. The human placental bed: electronmicroscopic study of trophoblastic invasion of spiral arterie. Am J Obstet Gynecol. 1980;137:58-70.

24 Pijnenborg R, Bland JM, Robertson WB, Brosens I. Uteroplacental arterial changes related to interstitial trophoblast migration in early human pregnancy. Placenta. 1983;4:397-414.

25 Blankenship TN, Enders AC, King BF. Trophoblastic invasion and modification of uterine veins during plecental development in macaques. Cell Tissue Res. 1993;274:135-44.

26 Linnemeyer PA, Pollack SB. Murine granulated metrial gland cells at uterine implantation sites are natural killer lineage cells. J Immunol. 1991;147:2530-5.

27 Croy BA, Kiso Y. Granulated metrial gland cells: a natural killer cell subset of the pregnant murine uterus. Microsc Res Tech. 1993;25:189-200.

28 Stewart IJ. Granulated metrial gland cells - not part of the natural killer cell lineage? J Reprod Immunol. 1994;26:1-15.

29 King A Loke YW. Differential expression of blood-group related carbohydrate antigens by trophoblast subpopulations. Placenta 1988;9: 513-21.

[30] Boyd JD, Hamilton WJ. The human placenta. Heifer and Sons. Cambridge. 1970. p182.

[31] Blankenship TN, Enders AC, King BF. Trophoblastic invasion and modification of uterine veins during placental development in macaques. Cell Tissue Res. 1993;274;135-44.

[32] Fuller EG, Highison GJ, Tibbitts FD, Fuller BD. Migration of intravascular trophoblast cells in uterine arteries of the Golden hamster: A scanning electron microscopic study. J Morphol. 1994;220:307-13.

[33] Goldman RD, Knipe DM. Functions of cytoplasmic fibers in non-muscle cell motility. Cold Spring Harbor Symp Quant Biol. 1973;37:523-34.

[34] Spooner BS, Yamada KM, Wessels NK. Microfilaments and cell locomotion. J Cell Biol. 1971;49:595-613.

[35] Marais WD. Human decidual spiral arterial studies. Part II. A universal thesis on the pathogenesis of intraplacental fibrin deposits, layered thrombosis, red and white infarcts and toxic and non-toxic abruptio placentae. A microscopic study. J Obstet Gynaecol Br Commomwealth. 1962;69:213-24.

[36] Enders AC, King BF. Early stages of trophoblastic invasion of the maternal vascular system during implantation in the Macaque and Baboon. Am J Anat. 1991;192:329-46.

[37] Ramsey EM, Houston ML, Harris JWS. Interactions of the trophoblast and maternal tissues in three closely related primate species. Am J Obstet Gynecol. 1976;124:646-52.

[38] Hamilton WJ, Boyd JD. Development of the human placenta in the first three months of gestation. J Anat. 1960;94:297.

CHAPTER 4

ABNORMAL BEHAVIOR OF ENDOVASCULAR TROPHOBLAST CELLS IN PLACENTAS OF SPONTANEOUS FETAL RESORPTION IN RATS

ABSTRACT

Endovascular trophoblast cell behavior in spontaneous fetal resorption in rats was evaluated. Fetal resorption was divided into three types: (1) that which occurs prior to or around implantation, (2) that with normal endovascular trophoblast cell behavior, and (3) that with abnormal endovascular trophoblast cell behavior. In the latter two, invasion of endovascular trophoblast cells into the maternal placental arteries was shallow compared to normal placentas of the same gestational age. In type 2, however, endovascular trophoblast cells completed all normal processes and survived better than other types of trophoblast cells. In contrast, in type 3, trophoblast cells remained on the endothelium even at term. Also, neither embedding nor giant cell formation was observed. Moreover, there was no accumulation of PAS-positive materials. Morphological findings of type 3 are similar to those reported in preeclamptic pregnancy, in which endovascular trophoblast cells fail to invade deep enough and remain within the vessel lumen.

Results of this study suggest that rats may provide some clues regarding the underlying mechanisms of abnormal endovascular trophoblast cell behavior observed in preeclamptic pregnancy.

INTRODUCTION

One of the most important maternal adaptations during pregnancy is the transformation of spiral arteries into distended uteroplacental arteries, a process known as

'*physiological changes.*'[1] This appears critical for proper '*physiological exchange*'[2] of nutrients and gases between the mother and fetus particularly at the time fetuses grow rapidly later in pregnancy.

For successful conversion of spiral arteries, trophoblast cells are considered to play a major role. The significance of endovascular trophoblast cells is underscored by the fact that inappropriately shallow invasion of endovascular trophoblast cells is the earliest and the most characteristic morphological alteration in preeclamptic pregnancy.[3] Resulting placental hypoxia due to failure of physiological changes has been suggested as a key element leading to clinical manifestation of preeclampsia through putative cytotoxic factors.[4,5] Accordingly, elucidation of factors responsible for controlling endovascular trophoblast cell invasion will significantly add to our knowledge regarding defective placentation in preeclamptic pregnancy. Furthermore, it may identify potential targets for therapeutic intervention.

At present, factors which control trophoblast cell behavior on spiral arteries are poorly elucidated. This is partly due to the fact that appropriate human placental bed specimens are difficult to obtain because of the ongoing nature of pregnancy and our inability to predict preeclampsia early in pregnancy at the time endovascular trophoblast cells fail to invade.

Several attempts have been made to establish animal models for the study of preeclampsia with varying degrees of success. However, most of them were developed to investigate pathophysiological mechanisms of the syndrome. For example, our laboratory has developed an ovine model of preeclampsia and has documented beneficial effects of a thromboxane synthase inhibitor in sheep with ovine pregnancy-induced hypertension.[6,7] This model appeared effective in the study of the pathogenesis of preeclampsia and in the evaluation of treatment efficacy, but because of fundamental

differences in placentation, was not suitable for the study of more fundamental abnormalities of preeclampsia, failure of endovascular trophoblast cell invasion and lack of physiological changes. Until now, no animal model has been presented to investigate abnormal behavior of endovascular trophoblast cells in preeclamptic pregnancy.

In this study, we examined behavior of endovascular trophoblast cells in spontaneous fetal resorption in rats and encountered trophoblast cell defective behavior similar to that reported in preeclamptic pregnancy.

MATERIALS AND METHODS

Sprague-Dawley rats (Harlan SD, Dublin, VA) weighing 225-250 gram were housed in the Animal Care Facility of our institution. The day of mating was identified by vaginal washes and sperm plug formation, and designated as day 1 pregnancy. Two animals were killed at days 8, 10, 12, 14, 16, 18 and 20 of pregnancy under a protocol approved by the Institutional Animal Care and Use Committee. The uterus and other tissues including liver, kidney and spleen were removed and fixed in 4 % paraformaldehyde-PBS buffered solution. The weight of fetuses and fetal resorption rate were assessed. Whole thickness of placentas including mesometrial triangle areas was cut and placed in freshly prepared fixative for a week. Thereafter, specimens were dehydrated and paraffin-embedded according to a standard technique. Hematoxylin and eosin staining was performed using an automatic staining machine (Sakura stainer, Japan) to obtain homogeneous staining results. Selected sections were stained with periodic acid-shiff (PAS). For proper evaluation of endovascular trophoblast cells, all tissue blocks were serially (5 μm) or step-serially cut (every 50 μm). Stained sections were examined under light microscope.

RESULT

Morphological changes of placentas of spontaneous fetal resorption.

Based on endovascular trophoblast cell behavior, spontaneous fetal resorption was divided into following three types:

Type 1. This type of fetal resorption apparently occurred prior to or around implantation based on their small size of placentas. This group was not suitable for morphological evaluation of trophoblast cell invasiveness since trophoblast cells do not yet invade the maternal arteries during this time period. Therefore, this group was excluded from further observation.

Type 2. This type appeared to occur from implantation through mid-pregnancy, and accompanied normal endovascular trophoblast cell behavior. Placentas of this group were infiltrated with a large number of leukocytes and blood, particularly in the decidua where the mother and fetus appose (Figure 4-1A) (page 114). Because of strong inflammatory reactions, placental structures such as the labyrinth and the trophospongium were difficult to recognize. However, in occasional good specimens, we could identify spiral arteries and observe endovascular trophoblast cells. Their depth of invasion was not as deep as in normal placentas of comparable gestational days. However, embedding of and giant cell formation by endovascular trophoblast cells were observed and appeared normal (Figure 4-1B) (page 114). Moreover, eosinophilic PAS-positive materials were accumulated around embedded giant cells and the walls of the spiral arteries (Figure 4-1C and D) (page 115). Leukocyte attachment to the spiral arteries which we observed in normal pregnancy in rats,[8] was not prominent in this group. Interestingly, endovascular trophoblast cells in this group survived better than other types of trophoblast cells even under strong resorption processes.

Type 3. In this group, endovascular trophoblast cells behaved abnormally. This type of fetal resorption was observed in only 2 out of 240 placentas examined in our

series of studies.[8] Both of them were found in placentas of day 20. Considering the size of resorpted fetuses, fetal death appeared to occurr between days 12 - 14. In this group, placental structures were intact and clearly identified. However, the fetus was completely resorpted. Placentas of this group accompanied no trace of inflammatory reactions even at day 20 (Figure 4-2A) (page 117). The overall size of placentas was significantly smaller than that of comparable gestational days. Placental development appeared as if simply arrested at the time of fetal death. Endovascular trophoblast cells were found in the very shallow portion of decidual spiral arteries but not in the mesometrial area. Also the number of endovascular trophoblast cells was very small. They remained present on the luminal surface of the spiral arteries even at day 20 (Figure 4-2B) (page 117). Endothelial cells contacting trophoblast cells disappeared as seen in normal pregnancy. Neither embedding nor giant cell formation was observed, however. As a result, invaded arteries did not undergo "physiological changes" and remained narrow and tortuous. We could not find any evidence of maternal immune reactions against endovascular trophoblast cells. Granulated metrial gland (GMG) cells were observed surrounding the spiral arteries. Some of them still contained characteristic large granules even at day 20, which is unusual in normal placentas. Similar to type 2, little leukocyte attachment was observed in the spiral arteries.

DISCUSSION

Although the mechanisms of spontaneous fetal resorption are still poorly understood and considered to be complex, our observations suggest the existence of at least three mechanisms in rats; (1) developmental abnormalities in peri-implantation periods; (2) possible maternal-fetal misalliance at placentas; and (3) post-implantation developmental abnormalities and defective endovascular trophoblast cell behavior. In type 2 fetal resorption, the behavior of endovascular trophoblast cells appeared normal.

Although the depth of invasion was slightly shallow compared to normal, this might be due to the termination of pregnancy rather than defects in trophoblast cells. The fact that endovascular trophoblast cells survived better than other types of trophoblast cells do not support the idea that endovascular trophoblast cells are a target of maternal rejection or served as a 'fetal allograft.' Since the invasion of endovascular trophoblast cells is much deeper than that of other types of trophoblast cells in rats, and because of its topology, the former are exposed to maternal blood continuously.[8] They are very likely to have the most intimate contact with the maternal immune system, both humoral and cellular. Therefore, endovascular trophoblast cells must be the cell population that is the most resistant to maternal rejection.[9]

In contrast, in type 3, endovascular trophoblast cell behavior was abnormal in both the depth of invasion and embedding. On the other hand, other types of trophoblast cells formed normal placental structures. From day 12 onward, well-being of the fetus depends on blood supply from the central spiral arteries. Therefore, because of shallow invasion of endovascular trophoblast cells and failure of 'physiological changes,' placentas might become hypoxic, which might cause fetal death and termination of pregnancy. Alternatively, for unknown reasons, fetal death and pregnancy loss occurred first, which might have affected endovascular trophoblast cell behavior subsequently.

Hence the invasive activity of endovascular trophoblast cells were impaired in placentas of both types 2 and 3 fetal resorption in rats, then it appears that migratory activity of endovascular trophoblast cells is not a 'default' mechanism once they entered into the arteries. Rather, for endovascular trophoblast cells to migrate on the endothelium, proper signals appear necessary, which may present only during successful pregnancy. Such putative factors, tentatively termed 'invasion regulatory factors' here are considered to coordinate endovascular trophoblast cell invasiveness in pregnant rats. They may be serum factors or cell surface molecules on the endothelium of the spiral arteries since the

only tissues endovascular trophoblast cells contact with the mother are blood and the spiral arteries in rats. If such factors prove to exist, they will be an exciting target for therapeutic intervention to modulate trophoblast cell invasiveness in the future.

In preeclamptic placentas, endovascular trophoblast cells invade the spiral arteries less than adequately[3,10,11] and have been documented to persist within the luminal surface of the spiral arteries even at term.[10,12] In contrast, few endovascular trophoblast cells were found within the spiral arteries of normal pregnancy at term. Therefore, preeclamptic trophoblast cells are considered to have the ability to attach to the endothelium but may not properly navigate along the lumen of the vessels and embed into the vessel walls. These multiple defects of endovascular trophoblast cells in preeclamptic women are quite similar to those observed in type 3 spontaneous fetal resorption in this study, suggesting common abnormalities in both species. However, despite these striking similarities between the human and rat, clinical signs of preeclampsia have not been reported in rats. This may be due to the difference of arterial supply in these two species. Since there are 100-150 uteroplacental arteries in humans,[13] failure of "physiological changes" in some of them may not cause catastrophic results or abortion. Instead, the mother may offset the defects through various compensatory mechanisms in the latter half of pregnancy. Accordingly, preeclampsia may be a result of maternal compensatory mechanisms which occur gradually over many weeks.[14] In rats however, there are single or only a few decidual spiral arteries. Later in pregnancy, they form a single 'maternal arterial space' providing blood to the developing fetus.[15] Therefore, failure of the single lifeline will immediately lead to fetal death or resorption. The mother cannot compensate, and rats do not have preeclampsia. Also, the short gestational period of rats may be insufficient for compensatory mechanisms to develop. Therefore, the outcome of rat pregnancy is likely to be either normal pregnancy or fetal resorption rather than preeclampsia.

In summary, we have documented defects in endovascular trophoblast cell behavior in spontaneous fetal resoprtion in rats, which is similar to those reported in human preeclamptic pregnancy. Although many questions regarding the validity of this whole animal model remain to be addressed, these observations may nevertheless provide an important new approach for the study of the etiology of preeclampsia.

Figure 4-1. Type 2 fetal resorption. Inflammatory reactions were apparent in the decidual area (A). However, endovascular and embedded trophoblast cells appeared intact with no inflammatory cells in their immediate areas (B). The spiral artery underwent "physiological changes" with deposition of PAS materials, as seen in normal pregnancy (C and D).

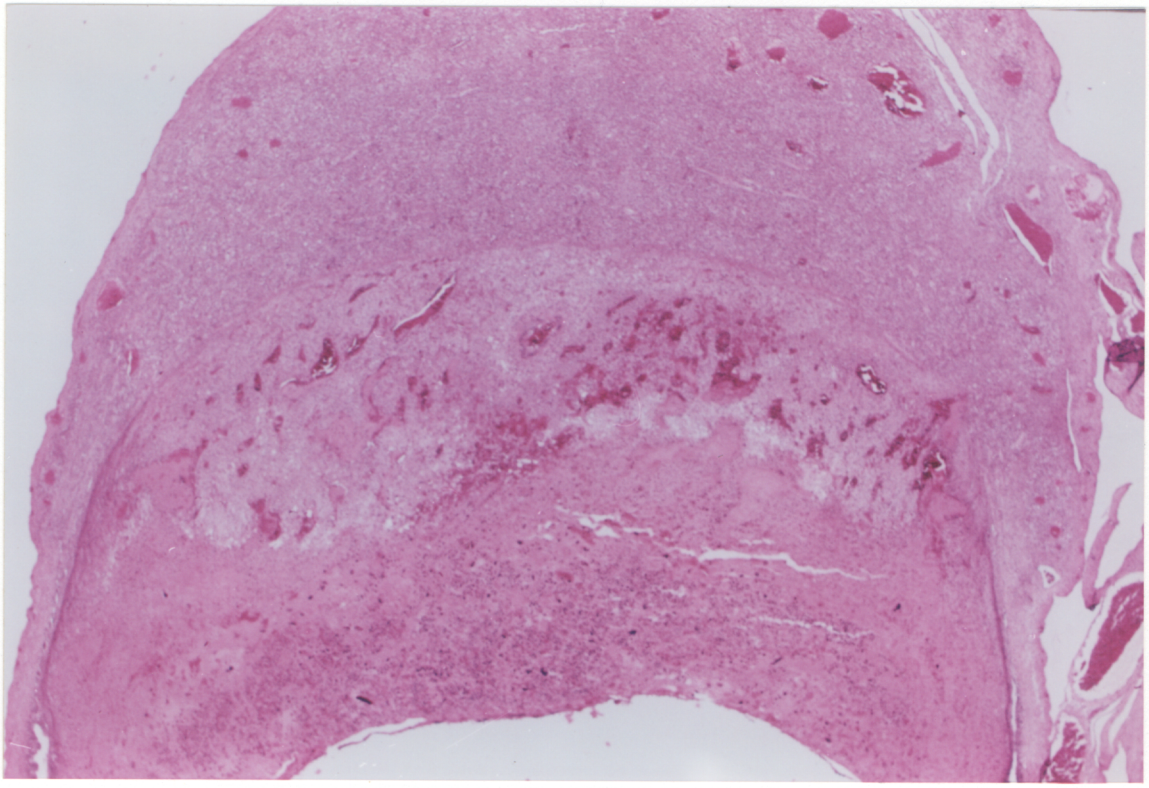

Figure 4-1A. (x 50) HE staining.

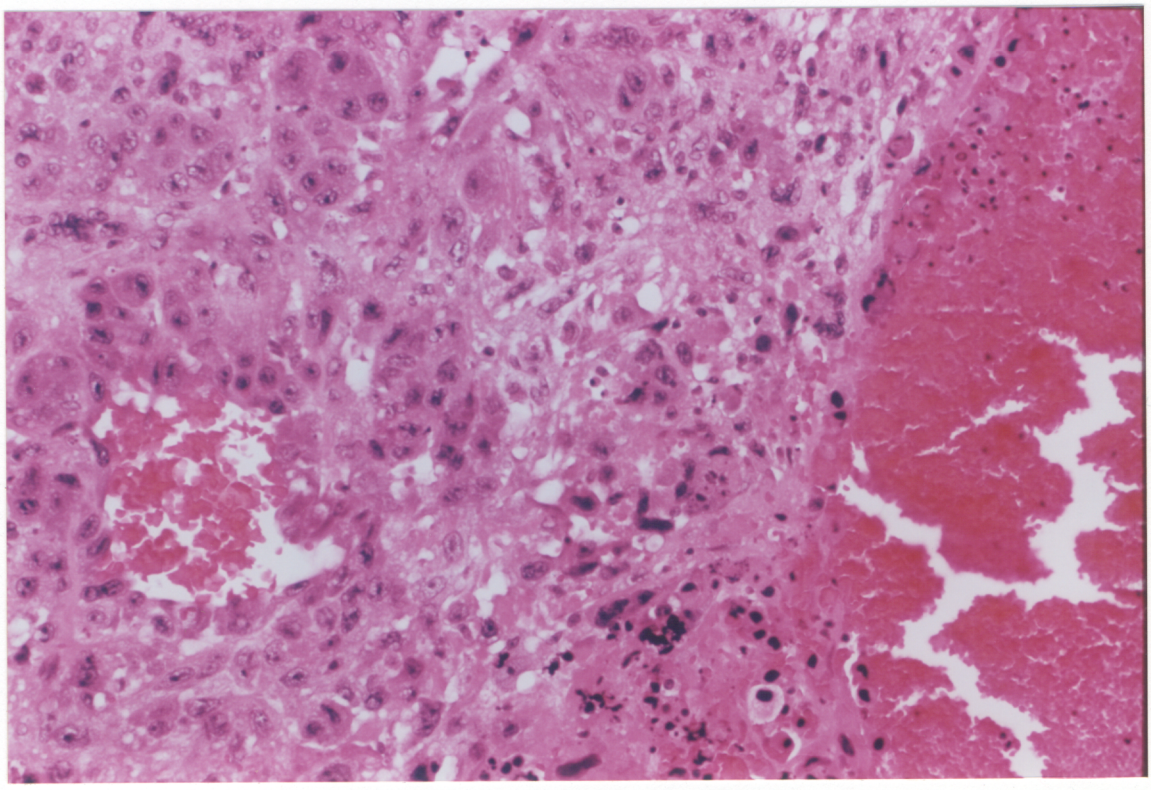

Figure 4-1B. (x 500) HE staning.

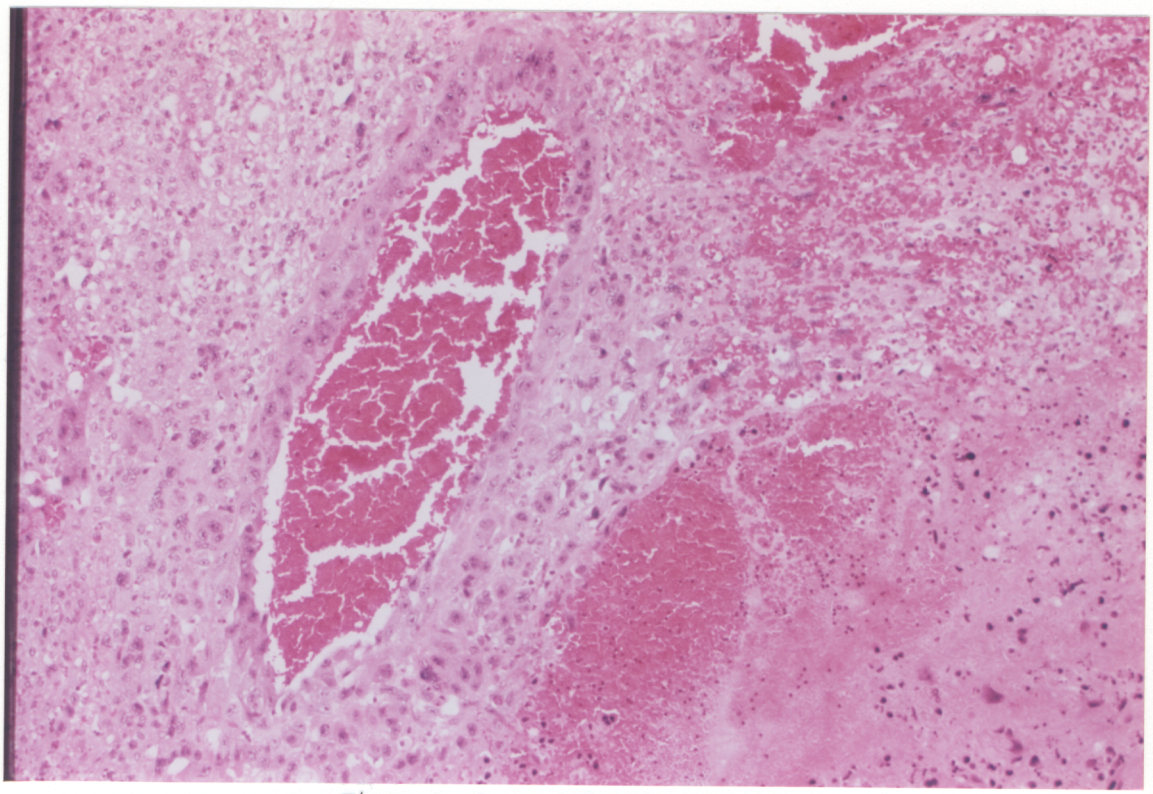

Figure 4-1C. (x 250) HE staining.

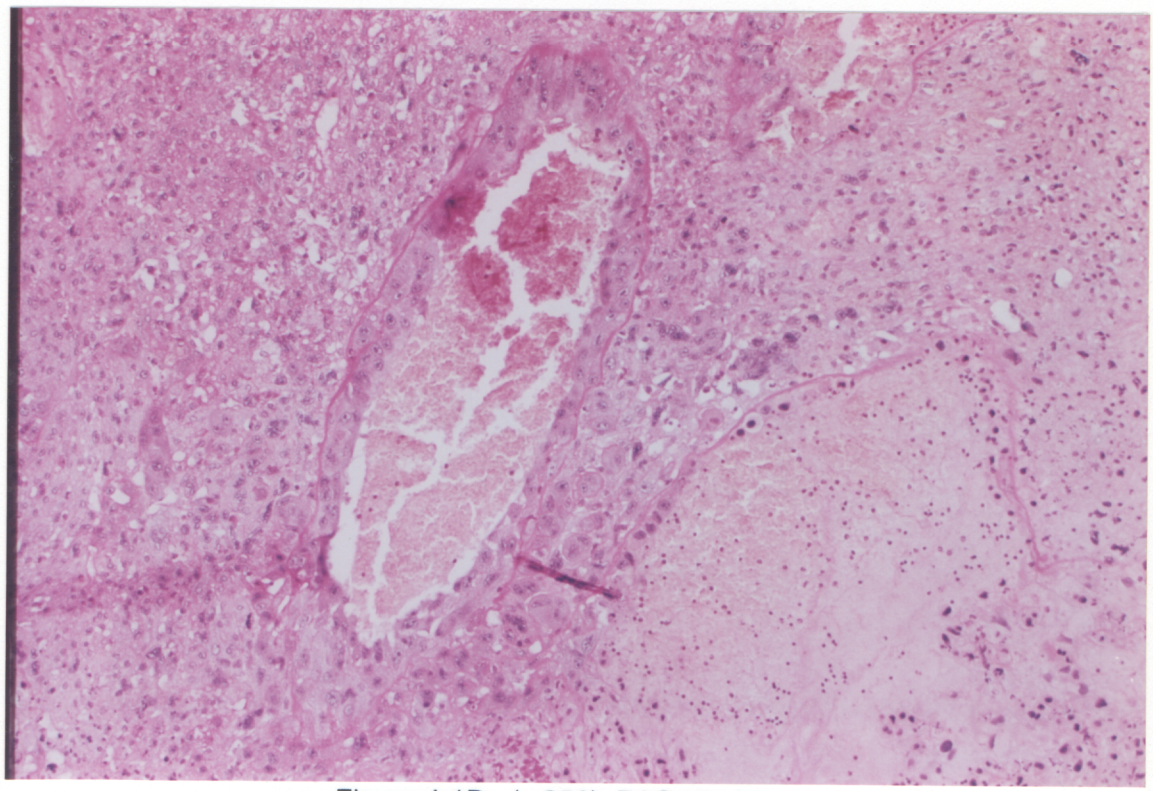

Figure 4-1D. (x 250) PAS staning.

Figure 4-2. Type 3 fetal resorption. The placenta had little evidence of immune/inflammatory reactions (A). The central spiral arteries contained some trophoblast cells but the number was smaller compared to normal. Moreover, no "physiological changes" were observed even at day 20 (B).

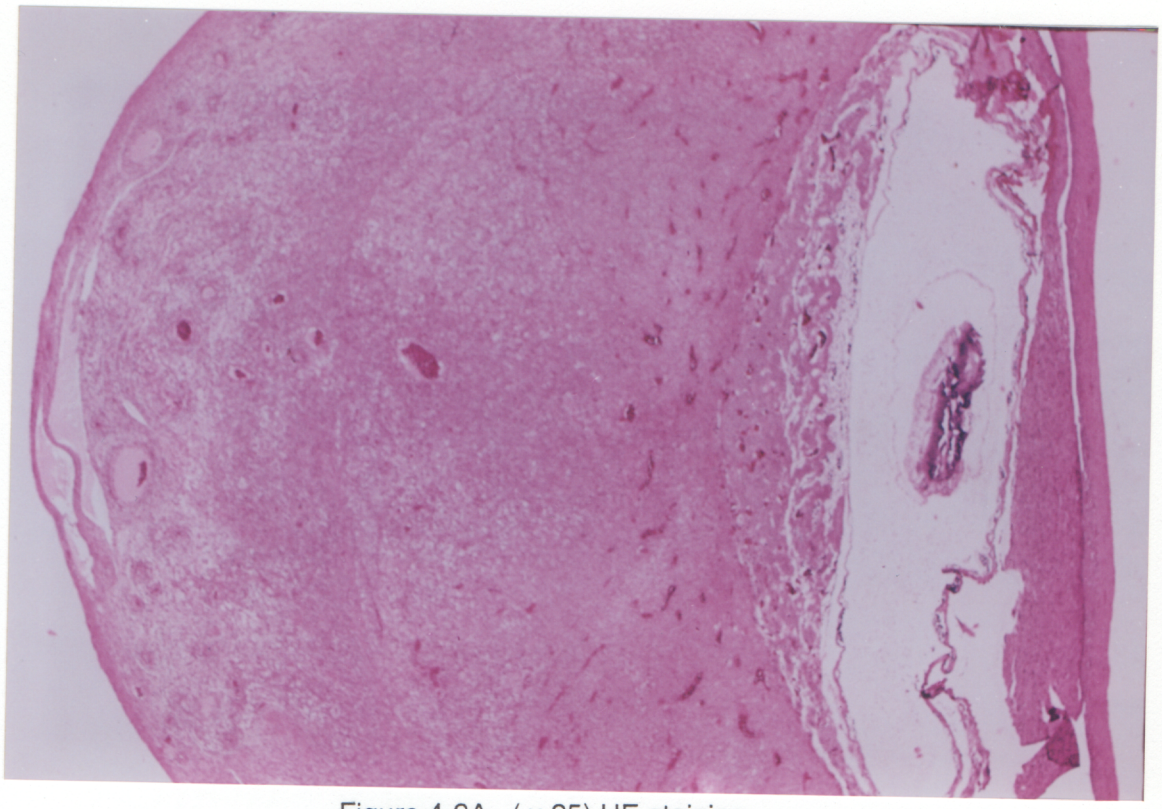

Figure 4-2A. (x 25) HE staining.

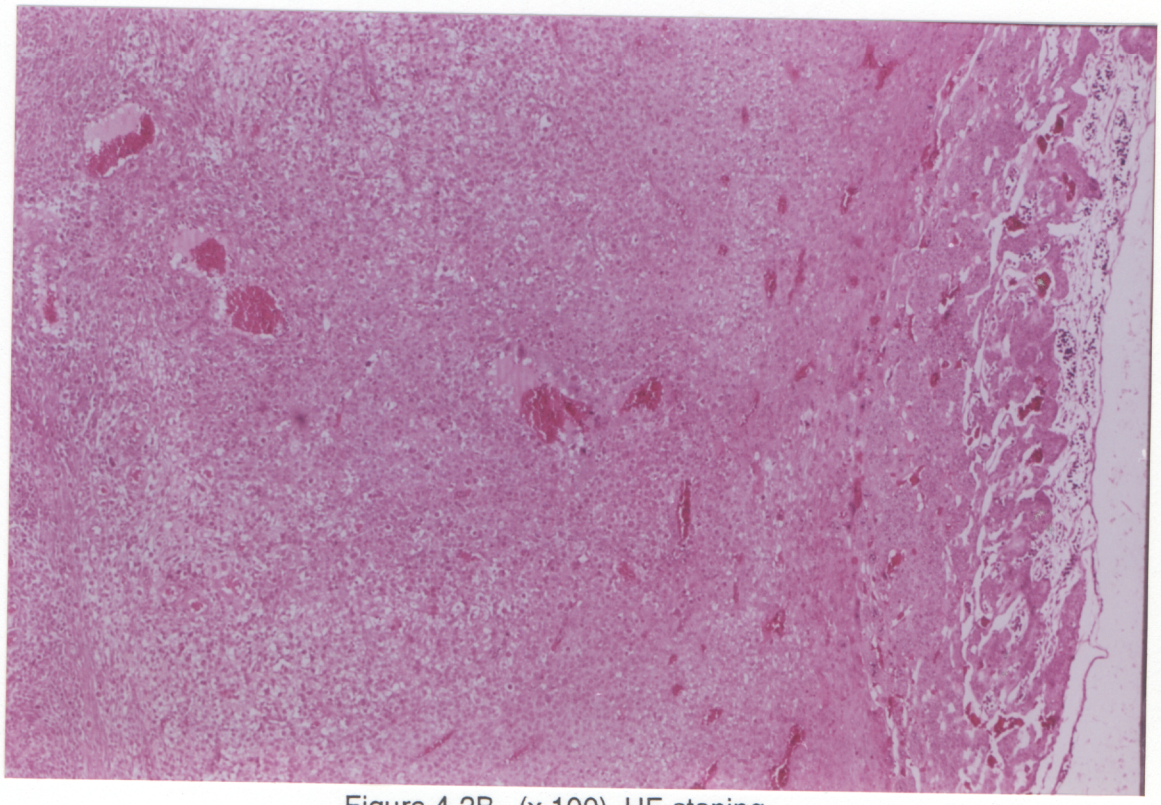

Figure 4-2B. (x 100) HE staning.

REFERENCES

[1] Brosens I, Robertson WB, Dixon HG. The physiological response of the vessels of the placental bed to normal pregnancy. J Path Bact. 1967;93: 569-79.

[2] Mossman HW. Comparative morphogenesis of the foetal membranes and accessory uterine structures. Contrib Embriol Carneg Instn. 1937;26: 129-246.

[3] Brosens I, Robertson WB, Dixon HG. The role of the spiral arteries in the pathogenesis of preeclampsia. In: *Obstet Gynecol Annual*, (ed) R. Wynn, New York: Appleton-Centrury-Crofts, pp177-91. 1972

[4] Roberts JM, Taylor RN, Musci TJ, Rodgers GM, Hubel CA, McLaughlin MK. Preeclampsia: An endothelial cell disorder. Am J Obstet Gynecol. 1989;161:1200-4.

[5] Roberts JM, Redman CWG. Pre-eclampsia: more than pregnancy-induced hypertension. N Eng J Med. 1993;341:1447-51.

[6] Keith, Jr, JC , Thatcher CD, Schaub RG. Beneficial effects of U-63,557A, a thromboxane synthetase inhibitor, in an ovine model of pregnancy-induced hypertension. Am J Obstet Gynecol 1987; 157:199-203.

[7] Keith Jr. JC, Endo Y, Warwick K, Keith KE, Brugh S, Rowles TK. Ridogrel improves maternal / fetal homeostasis in an ovine model of pregnancy-induced hypertension. Prostaglandins. 1994;47(3):247-63

[8] Endo Y, Eng LA. Underlying mechanisms of endovascular trophoblast cell invasion in pregnant rats. Ph.D thesis. 1995.

[9] Hunt JS, Hsi B. Evasive strategies of trophoblast cells: selective expression of membrane antigens. Am J Reprod Immunol. 1990;23:57-63.

[10] Khong TY, De Wolf F, Robertson WB, Brosens I. Inadequate maternal vascular response to placentation in pregnancies complicated by preeclampsia and by small-for-gestational age infants. Br J Obstet.Gynaecol. 1986;93:1049-59.

[11] Pijnenborg R, Anthony J, Davey DA, Rees A, Tiltman A, Verscuysse L, Van Assche A. Placental bed spiral arteries in the hypertensive disorders of pregnancy. Br J Obstet Gynaecol. 1991;98:648-55.

[12] Khong TY, Sawyer IH, Heryet AR. An immunohistologic study of endothelialization of uteroplacental vessels in human pregnancy - Evidence that endothleium is focally disrupted by trophoblast in preeclampsia. 1992;167:751-6.

[13] Boyd J, Hamilton WJ. *In* The human plancenta. Heffer and Sons Co. Cambridge. 1970.

[14] Redman CWG. The definition of pre-eclampsia. In: *Hypertension in pregnancy*. Sharp E and Symonds EM (eds). 1986. Perinatology Press. p3-13.

[15] Young A. The vascular architecure of the rat uterus during pregnancy. Trans Roy Soc Edinburgh. 1956;63:167-183.

CHAPTER 5

ASSOCIATION OF MACROPHAGE-COLONY STIMULATING FACTOR TREATMENT WITH ADVERSE PREGNANCY OUTCOMES IN RATS

ABSTRACT

The effects of recombinant human macrophage-colony stimulating factor (rhM-CSF) and interleukin-12 (IL-12) treatment on pregnancy outcomes and endovascular trophoblast cell behavior was evaluated in rats. Animals treated with a high dose of rhM-CSF (20,000U/kg/day) from day 8 through 11 had a significantly increased fetal resorption rate which was associated with poor development of the placenta at day 12. Endovascular trophoblast cell invasiveness was, however, only slightly impaired compared to gestational age matched controls, despite minimal growth of other types of trophoblast cells. Anti-M-CSF antibodies had no effect on pregnancy outcomes. These data suggest that M-CSF adversely affected a selected population of trophoblast cells *in vivo*. On the other hand, rats treated with IL-12 (10mg/kg/day) from day 8 through day 11 had normal growth of the placenta and endovascular trophoblast cell invasion was not affected. However, treated dams had smaller fetuses at day 20. Therefore, IL-12 might have affected fetal development rather than placental growth. The results of this study suggest the involvement of cytokines during pregnancy and warrant further investigation.

INTRODUCTION

Cytokines were once considered to be specific to the immune system. However, recent evidence suggest that they are pleiotropic and distribute to other than immune systems. Indeed, a cytokine network is proposed in female reproductive system based on the localization of many cytokines at placentas and their effects on pregnancy

outcomes and trophoblast cells *in vitro*.[1,2] Among various cytokines, the beneficial effects of cytokine growth factors on placental development are demonstrated in rodents and man[3] However, there are reports of increased fetal resorption rate in mice treated with M-CSF.[4] More recently, Drake et al. critically re-examined the *in vitro* growth-promoting effects of M-CSF and could not duplicate such an effect in trophoblast cells isolated from pregnant mice.[5] Accordingly, the exact roles of M-CSF in pregnancy remain to be elucidated.

In addition, almost all *in vivo* studies were conducted using mice, which placentation is very complex among rodents. Therefore, the end points evaluated were fetal resorption rates, weight of fetuses or placentas, and/or a gross size of placentas. Accordingly, detailed morphological information is not available, particularly regarding endovascular trophoblast cell invasiveness. To remedy a lack of morphological data, the present investigation was undertaken to determine if pregnant animals treated with M-CSF is associated with abnormal placentation, particularly defective invasion of endovascular trophoblast cells.

In addition to growth factors, NK cell activators have recently received intense attention since the decidua is rich in bone-marrow derived cells, particularly large granular lymphocytes (LGL) in humans or granulated endometrial gland (GMG) cells in rodents. These cell types are considered to belong to NK cells based on their cell surface phenotypes.[6] There is evidence that pregnant mice experienced a high incidence of fetal resorption as a result of enhanced NK cell activity by IL-2[7] or double stranded RNA, poly-IC treatment.[8] However, these treatments might have affected cells other than NK cells because of their multiple effects on other types of cells. Accordingly, the observed effects might not be ascribed exclusively to cytotoxic effects of NK lineage cells. In the present study, I administered IL-12, a more specific NK cell activator to pregnant rats to determine

if the activation of NK cells affects pregnancy outcome and trophoblast cell behavior *in vivo*.

METHODS

Sprague-Dawley rats (Harlan SD, Dublin, VA) weighing 225-250 gram were housed in the Animal Care Facility of this institution. The day of mating was identified by vaginal washes and sperm plug formation, and designated as day 1 pregnancy. At days 8, 9, 10 and 11, rats received either 0.1 ml of recombinant human (rh) M-CSF (20,000 CFU/animal/day) (Genetics Institute, Andover, MA), rhIL-12 (10 mg/animal/day) (Genetics Institute), anti-M-CSF antibody (Genetics Institute), or non-immune mouse antibody (Dako) intraperitoneally as a bolus. Two animals from each treatment group were killed at days 12 and 20. The uterus and other tissues including liver, kidney and spleen were removed and fixed in 4 % paraformaldehyde-PBS buffered solution. The weight of fetuses and fetal resorption rate were assessed. Whole thickness of placentas including mesometrial triangle areas were cut and placed in freshly prepared fixative for a week. Thereafter, specimens were dehydrated and paraffin-embedded according to standard technique. Hematoxylin and eosin staining was performed using an automatic staining machine (Sakura stainer, Japan) to obtain consistent staining results. For proper evaluation of endovascular trophoblast cells, all tissue blocks were serially (5 μm) or step-serially cut (every 50 μm).

The significance of differences between mean values of each group was evaluated by student's t-test. A p value ≤ 0.05 was considered significant.

RESULTS

Rats treated with M-CSF had an increased fetal resorption rate (33% at day 12 and 100% at day 20) (Table 5-1). There were two major morphological changes in

placentas of M-CSF treated rats. The overall size of placentas was much smaller than non-treatment groups at day 12 (Figures 5-1A and B) (page 128). Development of the future area of the labyrinth and trophospongium was much poorer than control groups: the labyrinth was thin and occupied a smaller area (Figure 5-1A) (page 128). Despite these poor placentation, endovascular trophoblast cells invaded the spiral arteries normally and the depth of invasion was only slightly shallow compared to normal pregnancy (Figures 5-1C and D) (page 129). Accumulation of GMG cells were normal at day 12. Also, swelling of endothelial cells of the placental spiral arteries was noted. At day 20, placentas were fully resorpted and no placental structure could be identified because of strong inflammatory reactions. Both anti-M-CSF and non-immune mouse antibodies had no effect on fetal growth and placental morphology.

Rats treated with IL-12 had few morphological changes both at days 12 and 20. GMG cells accumulated normally around the spiral arteries at day 12. Also, normal endovascular trophoblast cell invasion was observed at that day. At day 20, GMG cells had already degranulated cytoplasmic granules and swelled significantly, as in normal pregnancy. Similarly, 'physiological changes' of the spiral arteries was normal with embedded trophoblast cells forming giant cells. A fetal resorption rate was normal at both days. The weight of fetuses was, however, significantly lower than control groups at day 20 (2.35 ± 0.07 v.s. 2.76 ± 0.04. $p < 0.02$).

Table 5-1. Fetal resorption rate at days 12 and 20, and the weight of the fetuses at day 20

	rhM-CSF	rhIL-12	Control (no treatment)	Anti-M-CSF antibodies	Control antibodies
Fetal resorption rate at day 12	33.3 %[a]	13.3 %	6.25 %	12.5 %	0 %
Fetal resorption rate at day 20	100 %[b]	3.44 %	10.34 %	3.22 %	6.67 %
The weight of fetuses (gram) at day 20	N/A	2.35±0.07[c]	2.76±0.04	2.73±0.02	2.70±0.03

Each treatment group consisted of two animals at each day 12 and 20.

[a] $p < 0.01$, [b] $p < 0.00001$, [c] $P < 0.02$ (compared to control - no treatment)

DISCUSSION

In chorio-allantoic placentas, the development of placentas and conceptuses is initially dependent on the blood supply from the circumferential arteries.[9] As gestation proceeds, the blood supply shifts to the central decidual spiral arteries which dilate markedly latter in pregnancy[9] (Figure 5-2). Therefore, for successful pregnancy, transformation of the spiral arteries is considered to be crucial to satisfy the increased demand of blood from the developing fetuses later in pregnancy. In the current study, despite the increased incidence of fetal resorption, endovascular trophoblast cell invasiveness was not severely impaired in rats treated with M-CSF. Therefore, the observed adverse effect on pregnancy outcomes might not be associated with the potential effects of M-CSF on endovascular trophoblast cell invasion. Since the future area of the labyrinth and trophospongium layers were extremely thin in the treated rats at day 12, this might have resulted in poor exchanges of nutrients and gases between the mother and fetus laterr in pregnancy. Since the development of the fetus is mostly

dependent on the quality and quantity of blood to be supplied, this might have led to the increased fetal resorption at day 20. At present, the mechanisms by which M-CSF affected placentation are unknown.

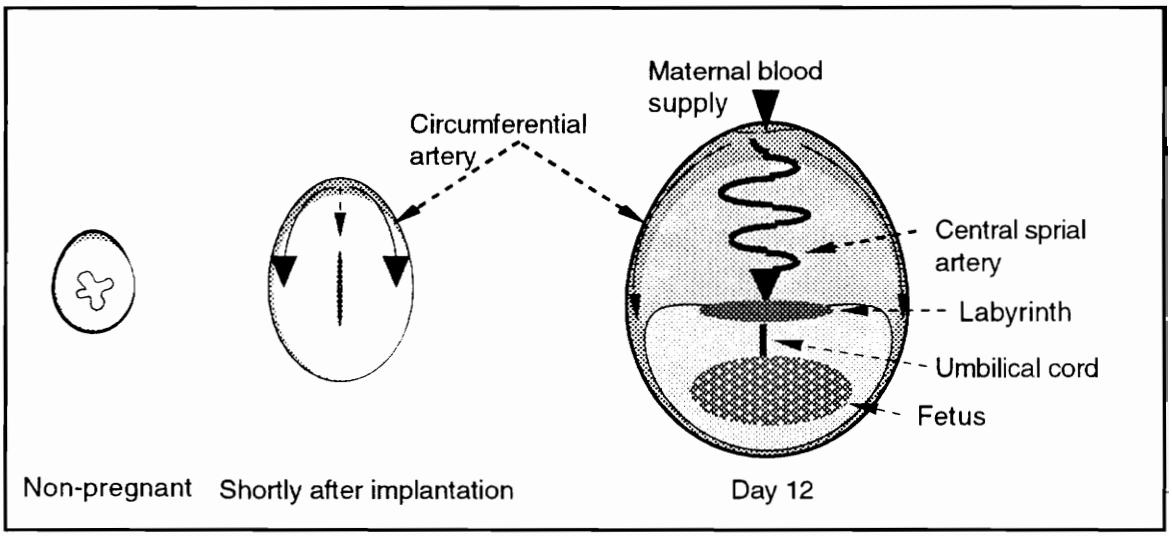

Figure 5-2. This illustrates the shift of maternal blood supply to the conceptus during the course of pregnancy. The blood supply shift from cicumferential arteries early in pregnancy (center) to the central spiral arteries in the latter half of pregnancy (right). The outer ones are circumferential arteries, which is important before the formation of the definitive placenta. The inner artery represents central spiral arteries where endovascular trophoblast cells invade and migrate. This arterial supply becomes important in the latter half of pregnancy to satisfy the increasing demand of blood from the fetus. (Modified from Pinenborg R. et al.[10])

Thus far, M-CSF has been reported to have growth-promoting effects on trophoblast cells *in vitro*[11] and *in vivo*.[12] However, there were reports of abortifacient effects of M-CSF in mice.[13] The results of this study are in agreement with this respect and suggest that too much of M-CSF may be detrimental to the development of placentas, resulting in poor pregnancy outcomes.

At present, it is unknown if successful pregnancy reguires maternal M-CSF. In

this sense, Pollard et al. reported interesting results: *op/op* mice which lack M-CSF are infertile.[14] However, mating of *op* female and non-*op* male can reproduce and have normal placental weights. They speculated that a paternal source of M-CSF such as seminal fluids may be more important than maternal M-CSF. The results of anti-M-CSF antibody treatment in this study support their speculation.

There are three types of trophoblast cells in rat placentas; (1) labyrinth trophoblast cells which serve as a physical barrier between maternal and fetal circulation; (2) trophospongium and giant cell layer trophoblast cells which digest the superficial part of the uterine endometrium and serve as an intermediate zone between the mother and fetus; and (3) endovascular trophoblast cells which modify the vasculature physically to create the vascular infrastructures for providing nutrition and O_2 to the growing fetus. The results of this study demonstrated that the effects of M-CSF were selective and different trophoblast cell population responded to M-CSF differently *in vivo*.

IL-12 treatment did not cause any morphological abnormalities in the placenta, nor activation of GMG cells, which have been considered to be an NK cell lineage.[15] Therefore, GMG cells may not be an NK cell origin or activation of NK cells may have few adverse effects on placental growth. Alternatively, there may not be a species cross reactivity of rhIL-12 between humans and rats. Despite the normal development of placentas, the fetus of IL-12 treated group was significantly smaller than control. Therefore, the observed effects of IL-12 might have been related to the direct effects on fetal development rather than on placental growth or GMG cells. Accordingly, further experiments are necessary to investigate the effects of IL-12 on fetal development in rats.

In conclusion, a high dose of M-CSF was associated with an increased fetal resorption rate in rats. On the other hand, IL-12 treatment was not associated with activation of GMG cells but nevertheless induced smaller fetuses. The exact mechanisms of both cytokines in pregnancy remain to be elucidated.

Figure 5-1. M-CSF treated rats had smaller placentas (A) compared to normal (B). However, endovascular trophoblast cell invasion was noted (C), and the depth of invasion was slightly shallow compared to normal (D). H&E staining.

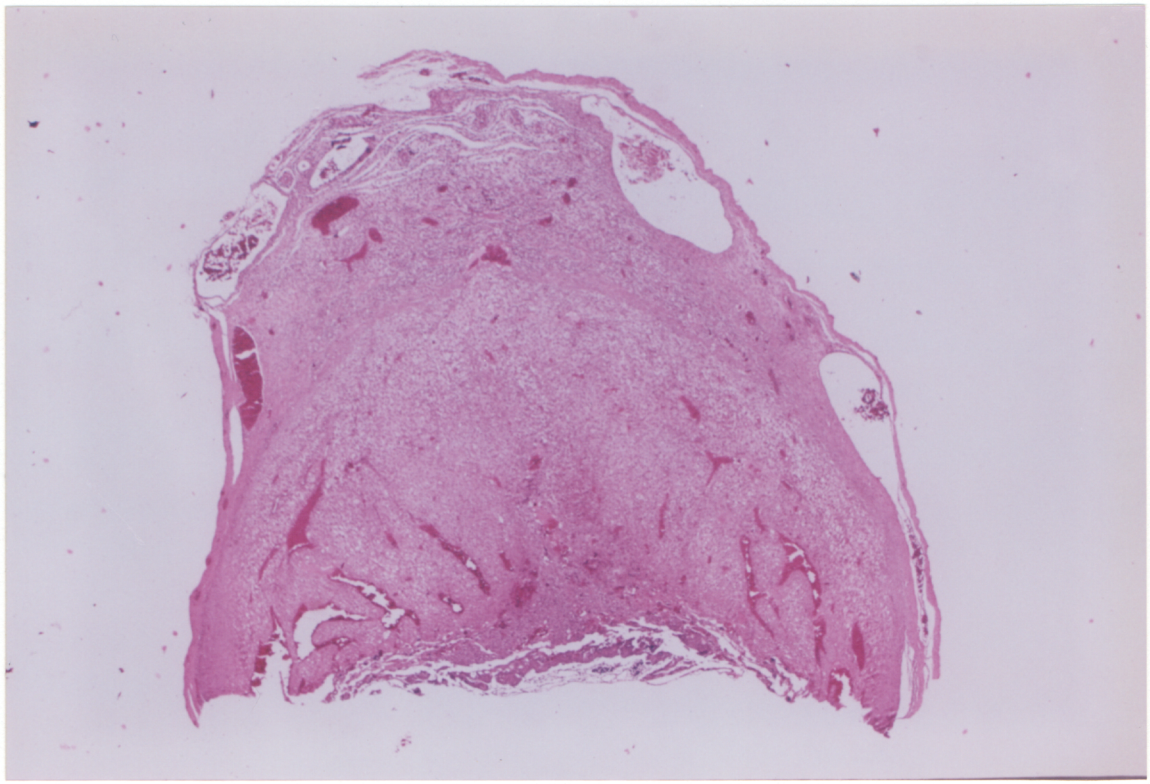

Figure 5-1A. (x 50) HE staining.

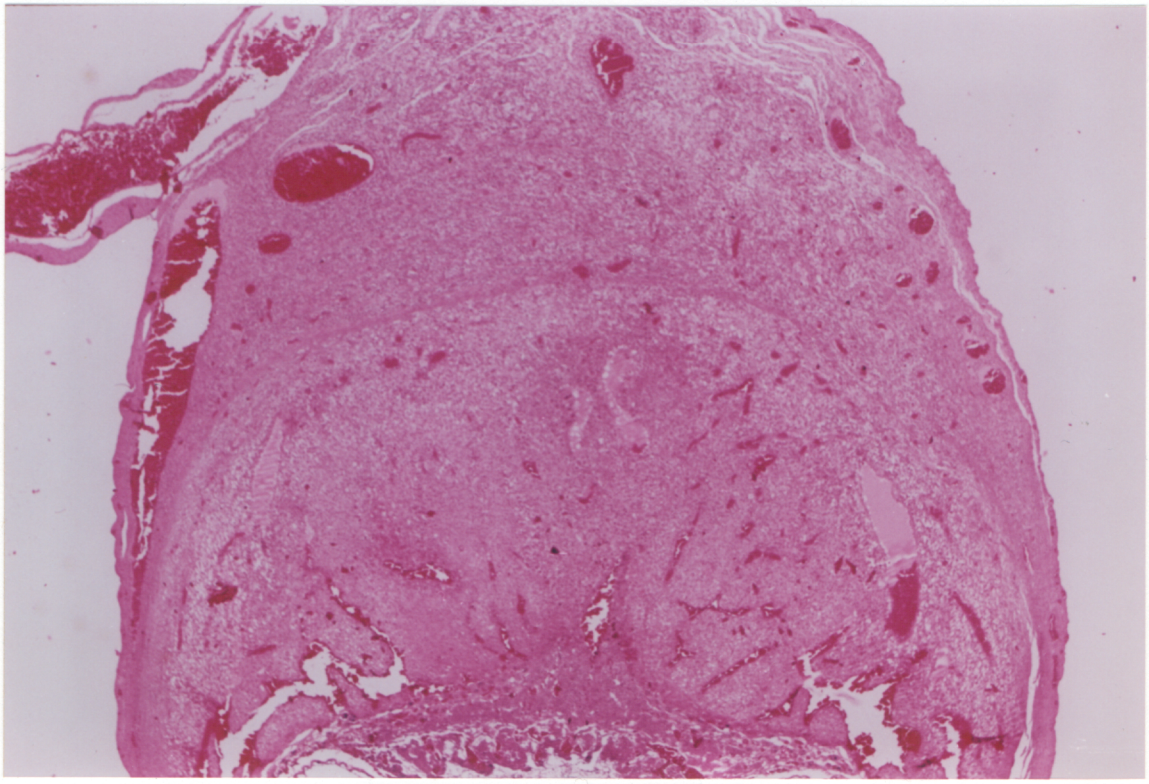

Figure 5-1B. (x 20) HE staning.

REFERENCES

[1] Mitchell MD, Trautman MS, Dudley DJ. Cytokine networking in the placentas. Placenta. 1993;14:249-75.

[2] Wegmann TG, Athanassakis L, Gilbert L, Branch D, Dy M, Menu E, Chaouat G. The role of M-CSF and GM-CSF in fostering placental growth, fetal growth survival. Trans Proc. 1989;21:566-8.

[3] Arceci R, Shanahan JF, Stanley ER, Pollard JW. Temporal expression and location of colony-stimulating factor 1 (CSF-1) and its receptor in the female reproductive tract development. Proc Natl Acad Sci. 1989;86:8818-22.

[4] Tartakovsky B, Goldstain O, Brosh N. Colony-stimulating factor-1 blocks early pregnancy in mice. Biol Reprod. 1991;44:906-12.

[5] Drake BL, Head JR. GM-CSF and CSF-1 stimulate DNA synthesis but not cell proliferation in short-term cultures of mid-gestation murine trophoblast. J Reprod Immunol. 1994;26:41-56.

[6] King A, Balendran N, Wooding P, Carter NP, Loke YW. Phenotypic and morphologic characterization of novel $CD3^-$, $CD56^{bright+}$ lymphocytes in the pregnant human uterus. Dev Immunol 1991;1:169-190.

[7] Gendron RL, Farookhi R, Baines MG. Resorption of CBA/J x DBA/2 mouse conceptuses in CBA/J uteri correlates with failure of the feto-maternal unit to suppress natural killer cell activity. J Reprod Fertil. 1990;89:277-84.

[8] Kinsky R, Delage G, Rosin N, Thang MN, Hoffman M, Chaouat G. A murine model of NK cell mediated resorption. Am J Reprod Immunol. 1990;23:73-7.

[9] Pijnenborg R, Robertson WB, Brosens I. The arterial migration of trophoblast in the uterus of the golden hamster, *Mesocricetus auratus*. J Reprod Fertil. 1974;40:269-80.

[10] Pijnenborg R, Robertson WB, Brosens I, Dixon G. Review article: Trophoblast invasion and the establishment of hemochorial placentation in man and laboratory animals. Placenta. 1981;2:71-92.

[11] Armstrong DT, Chaouat G. Effects of lymphokines and immune complexes on murine placental cell growth in vitro. Biol Reprod. 1989;40:466-74.

[12] Chaouat G, Menu E, Clark DA, Dy M, Minkowski M, Wegmann TG. Control of fetal survival in CBA x DBA/2 mice by lymphokine therapy. J Reprod Fert. 1990;89:447-58.

[13] Brosh N, Lotan M, Eisenbach L, Brocke S, Tartakovsky B. Fertility impairment and improved fetal survival induced by a tumor cell line in mice. Am J Reprod Immunol. 1991;26:47-51.

[14] Pollard JW, Hunt JS, Wiktor-Jedrzejczak W, Stanley ER. A pregnancy defect in the osteopetrotic (*op/op*) mouse demonstrates the requirement for CSF-1 in female fertility. Dev Biol. 1991;148:273-83.

[15] Croy BA, Kiso Y. Granulated metrial gland cells: a natural killer subset of the pregnant murine uterus. Microsc Res Tech. 1993;25:189-200.

CHAPTER 6

USE OF LOG CONCENTRATIONS OF NEGATIVE CONTROL ANTIBODIES AS A PART OF CONTROL STUDIES IN IMMUNOHISTOCHEMISTRY

ABSTRACT

Cross reactivity of antibodies to epitopes other than their intended ligands is the most annoying false positive staining in immunohistochemistry. However, there is no perfect solution to address this problem. In general, control studies consist of staining tissues with non-immune antibodies, antibodies preincubated with their ligands (blocking studies), and buffer. Among them, non-immune antibodies are generally used at protein concentrations similar to those of test antibodies. Negative staining at those concentrations is considered to be satisfactory.

In this study, I experienced a specific staining of tissues by increasing the concentrations and incubation time of nonimmune negative control antibodies, that was indistinguishable from those of test monoclonal antibodies, but remained different from results of other three types of primary antibodies of the same species. The results suggest a possibility of background staining of test antibodies, and indicate a necessity of use of log concentrations of nonimmune negative antibodies as a critical part of control studies in immunohistochemistry.

INTRODUCTION

Recently, various cytokines have been demonstrated to distribute in placentas immunohistochemically and their functional roles have been actively investigated in experimental animals.[1] Among them, growth-promoting cytokines such as M-CSF

received intense attention since they appear to stimulate trophoblast cell proliferation and to accelerate fetal and placental growth.[2] Therefore, M-CSF may be crucial for trophoblast cells to differentiate and function properly. If this is correct, aberrant distribution of M-CSF may be associated with poor pregnancy outcomes, e.g., preeclampsia.

Another interesting cytokine is interleukin-12 (IL-12), a specific NK cell activator as the decidua is rich in NK cell lineage cells; large granular lymphocytes (LGL) in human[3] and granulated metrial gland (GMG) cells in rodents.[4] Indeed, NK cell activators such as IL-2 have been reported to increase fetal resorption rate in mice.[5] Therefore IL-12 may participate in a putative placental cytokine network. If so, aberrant distribution of IL-12 may also be associated with pathological states.

METHODS

Human placental bed biopsy specimens were obtained during cesarean sections by participating obstetricians. Placental bed collection was conducted between 1986 and 1992. Tissues were fixed with buffered neutral formalin and embedded with paraffin according to standard procedures. After heating sections at 55°C in an oven for an hour, sections were deparaffinized with 2x toluene and circled with a PAP pen (Dako, Denmark). Then, they were dehydrated with 2x ethanol and rinsed with tap water.

Endogenous peroxidase was quenched by incubating sections with 0.5 % hydrogen peroxide (Sigma, MO) and 0.1 % of NaN_3 for 15 min. After washing with Tris buffered saline (TBS) pH 7.8 (3 x 5 minutes each), non-specific binding was inhibited by incubating sections three times with 2% bovine serum albumin (Sigma) in TBS for a minimum of 15 min. Then, sections were incubated with anti-M-CSF antibodies (1/2000) (Genetics Institute, Cambridge, MA) for 2 h, anti-IL-12 antibodies (1/25 or 1/50) (Genetics Institute) for 4 hours, anti-cytokeratin (1/400) (Dako), anti-vimentin (1/500) (Dako), or

macrophage marker antibodies (1/500) (Dako) for 30 minutes. Only anti-vimentin antibodies required 0.01 % pepsin (Sigma) treatment for 10 min at 37 °C prior to first antibodies. Non-immune negative antibodies (Dako) were incubated at the concentrations of 1/25, 1/50, 1/100, and 1/2000 for 2-4 hours. As a buffer control, TBS was incubated for 2-4 hours. Incubation conditions of the first antibodies were optimized for each antibody by varying concentrations and incubation time and trying enzyme treatment (both pepsin and trypsin [Sigma]). All primary antibodies were mouse antibodies. After three times washing with TBS for 5 min each, 2% bovine serum albumin was again applied to sections for 15 min. Then, secondary biotinylated rabbit anti-mouse immunoglobulins (1/400) preincubated with 4 % whole human serum (Organon Teknika) 30 min in advance were incubated for 30 min followed by three times washing with TBS for 5 min each. Thereafter, streptavidin-peroxidase (1/800) (Jackson Immunoresearch Laboratory,) for 30 min was used to bind peroxidase to the secondary antibodies. Finally, peroxidase was developed by DAB (Sigma) and sections were counter-stained with Harris hematoxylin (Sigma) for microscopic observation. A blocking study was performed by incubating anti-M-CSF antibodies with rhM-CSF (Genetics Institute) or anti-IL-12 antibodies with rhIL-12 (Genetics Institute).

All staining procedures were conducted at room temperature except incubation of primary antibodies with antigens at 4°C.

Table 6-1. List of Reagents Used

Products	Catalog #	Vendor
Whole human serum	55979	Organon Teknika Corporation
Biotinylated rabbit anti-mouse Ig	#354 (Lot #120)	Dako
Peroxidase conjugated Streptavidin	016-030-084 (Lot # 26638)	Jackson Immunoresearch Laboratory
Anti-cytokeratin	MNF116	Dako
Anti-vimentin V9	M 725 (Lot #052)	Dako

Mouse IgG2a negative control	x 943 (Lot #012)	Dako
Anti-M-CSF	HM7/7.7.10 Version #2	Genetics Institute Inc.
Anti-IL-12	12H1/8.2.1 Version #1	Genetics Institute Inc.
DAB	D-5905	Sigma Immunochemicals
Anti-human macrophage CD68	M876 (Lot #101)	Dako
Bovine serum albumin		Sigma

RESULTS AND DISCUSSION

Distribution of M-CSF and IL-12 at placentas

[M-CSF] The most intense staining was observed in decidual cells in all sections examined. Staining was homogeneous in cytoplasm and observed in both decidua basalis and vera. Glandular cells were positive or negative for M-CSF in even the same section. However, the apical part of the cells were more likely to be stained for M-CSF than the basal part. Vascular smooth muscle cells were consistently negative for M-CSF even when surrounding decidual cells were strongly positive. Interstitial and giant trophoblast cells were positive or negative even in the same sections. Endovascular trophoblast cells were in general negative. When stained positively, staining intensity was faint compared to other cells. Syncytiotrophoblast cells were in general negative although observation was made in a few sections. Myometrium was positive or negative for M-CSF. They were often stained patchy. However, the intensity of M-CSF staining on myometrium was also sometimes heavy.

[IL-12] Overall staining intensity of IL-12 was faint compared to M-CSF. Similar to M-CSF, decidual cells were positive for IL-12. Also maternal glandular and epithelial cells and trophoblast cells were positive or negative for M-CSF. Syncytiotrophoblast cells were in general negative, as in M-CSF. Vascular smooth muscle cells were negative. Myometrium was positive or negative. Thus, staining patterns of IL-12 were similar to those of M-CSF though staining was less intense.

Overall, in both M-CSF and IL-12 staining, staining intensity was variable from sections to sections and even within the same sections. This may be due to technical problems, variability in specimens collections/preservation, and/or real differences.

Nuclear staining in both M-CSF and IL-12 was observed in glandular cells. However, it was confirmed as non-specific since this nuclear staining was found even when primary antibodies were bypassed. Therefore, nuclear staining was not associated with primary antibodies.

If a putative cytokine network exists at the maternal-fetal interface, distribution of M-CSF in placental beds should be different from that of the decidua vera (non-placental part) at some degrees. However, the distribution of M-CSF positive cells appeared similar in both the decidua basalis and vera. Distinction between the decidua basalis and parietalis was made based on the presence of interstitial trophoblast cells. In addition to M-CSF staining, IL-12 was also localized at both the decidua basalis and vera and staining patterns of IL-12 appeared quite similar to that of M-CSF although, as mentioned above, staining intensity of the former was faint. Moreover, many cells and tissues, e.g. myometrium, were positive for both M-CSF and IL-12.

Control studies

Initially, non-immune negative antibodies (mouse IgG2α), which are exactly the same IgG isotype as anti-M-CSF antibody, were incubated under the same incubation conditions as anti-M-CSF antibodies (1/2000 for 2 hours). Under these conditions, sections were stained completely negative. Then, the concentration was increased to a level equivalent to that of anti-IL-12 antibodies (1/50 for 2 hours). Not only did non-immune antibodies stain sections neatly, but also staining patterns were similar to those of anti-M-CSF and anti-IL-12 antibodies. Since at this incubation condition, staining intensity

of non-immune antibodies was still faint compared to that of anti-M-CSF, I increased concentration and prolonged incubation time further. Surprisingly, staining patterns of these three antibodies became very similar. Along with puzzling distribution of M-CSF and IL-12, we reached the tentative conclusion that what we were looking at were no more than background staining. Supporting this conclusion, sections incubated with anti-cytokeratin, anti-vimentin or macrophage marker antibodies had quite different staining patterns from each other and background staining was minimum. Their staining patterns were easily distinguishable from those of anti-M-CSF, anti-IL-12 and non-immune antibodies. Sources of primary antibodies I utilized in this study were all of mouse origin, this fact reduces the possibility that the blocking of Fc receptors with 2 % bovine serum albumin was insufficient, thereby causing non-specific staining. Finally, sections were incubated with buffer instead of the primary antibody. Buffer control did not stain sections in any conditions.

Since any antibody has a potential to cross-react with other epitopes depending on incubation conditions, important is how strong cross-reaction is. For example, X antibody may attach to target epitopes at the concentration of 1/2000 and to irrelevant sites (hence false positive) at the concentration of 1/50 or higher. On the other hand, Y antibody may attach to both irrelevant and target epitopes at 1/100. In this case, we will see both true and false positive staining and one cannot discriminate positive staining from false positive. Needless to say, X is a good antibody which has large differences between the concentration picking up irrelevant epitopes and the concentration binding only to target epitopes. Of course, in the above example, Y antibody is not appropriate for immunohistochemistry, and results are uninterpretable.

A big question is how do we know when we have an antibody which attaches to both irrelevant and target antigenic sites at similar incubation conditions (hence Y antibodies). At present, there is no golden rule to eliminate a possibility of cross-

reactivity. One commonly used procedure is to stain tissues with non-immune antibodies to see the specificity of test antibodies. In general, the protein concentration of control antibodies is adjusted to concentrations similar to that of test antibodies. If at that concentration, non-immune antibody did not bind to tissues, we consider binding of immune antibodies was specific. Even when control antibody attach to sections but staining patterns were much different from those of immune antibodies, we are still able to tell positive staining from false. However, if both test and control antibodies have very similar staining patterns but the concentration of both antibodies are different, it is difficult to interpret results. The difference may be the affinity of each antibody but not the specificity. This is the case I faced in this study. Similarly, if test antibodies have high background staining, it is also difficult to draw a line between positive and false-positive (background) staining.

CONCLUSION

Because of the similarity of staining patterns of anti-M-CSF, anti-IL-12 and negative control antibodies, and puzzling distribution of M-CSF and IL-12 in decidual tissues, the incubation conditions or materials used in this study might not be suitable for these antibodies. Therefore, it must be concluded that the results of immunohistochemistry of anti-M-CSF and anti-IL-12 were uninterpretable. It should be noted that this conclusion must be limited strictly to the systems and materials employed in this study and does not mean that these antibodies are not appropriate for immunohistochemistry in general. In this instance however, the differences in antibody concentration between positive and false-positive staining, particularly of anti-IL-12 antibodies, is small.

In summary, the results of this study confirm that positive or negative staining results are partly dependent on detection systems and should not be ascribed

exclusively to the specificity of test antibodies without extensive validation of the specificity of antibodies. To address this problem, use of log concentrations of negative control antibodies are desirable in immunohistochemistry.

Figure 6-1. The staining results of sections stained with anti-M-CSF, anti-IL-12 and non-immune antibodies were very similar each other. Non-specifc staining of negative control atnibodies was not observed at the incubation conditions similar to those of anti-M-CSF antibodies. However, at the conditions similar to those of anti-IL-12 antibodies, very specific "false positive" staining was obtained. In contrast, anti-cytokeratin, anti-vimentin, and anti macrophage marker antibodies had totally different staining patterns. Also, non-specific staining was minimum. Throughout these studies, the same concentration of bovine serum albumin was used to quench non-specific staining. Also, all antibodies used in this studies were of mouse origin although the suppliers were different. A: anti-M-CSF, B: non-immune, C: anti-IL-12, D: anti-macrophage marker, E: anti-cytokeratin, and F: anti-vimentin antibodies.

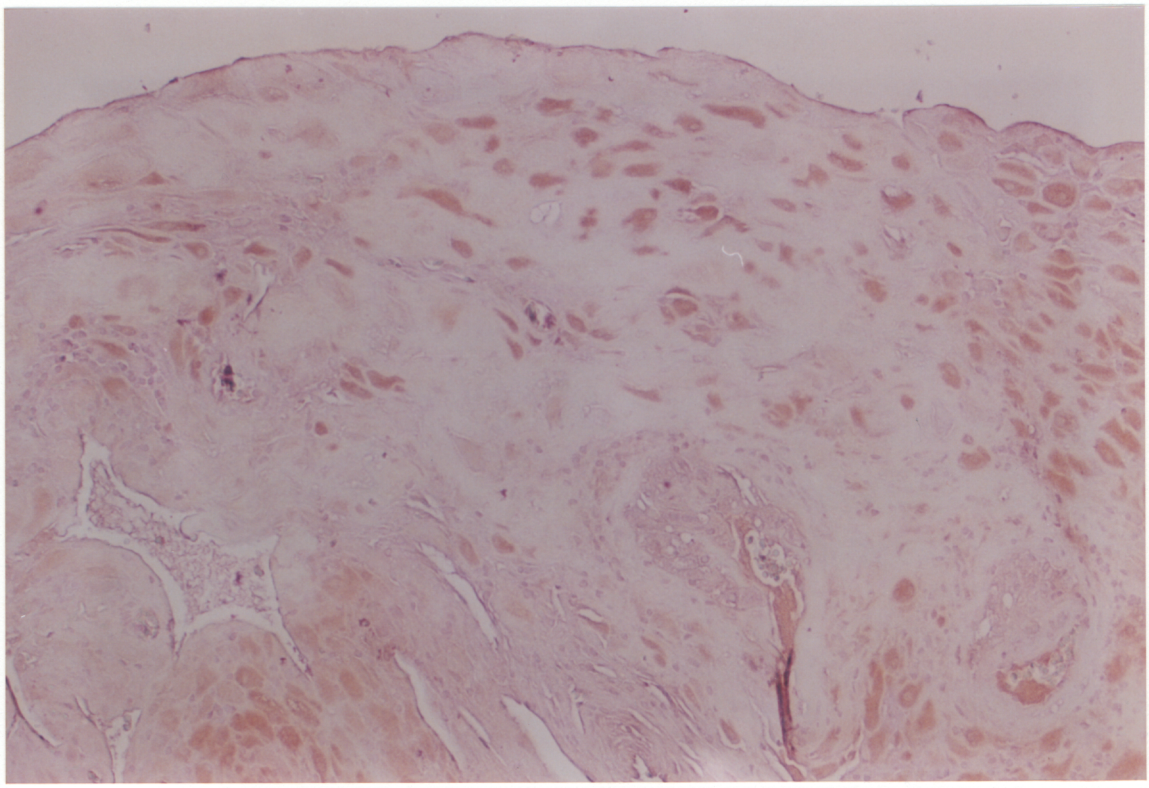

Figure 6-1A. (x 250) Anti-M-CSF antibody staining.

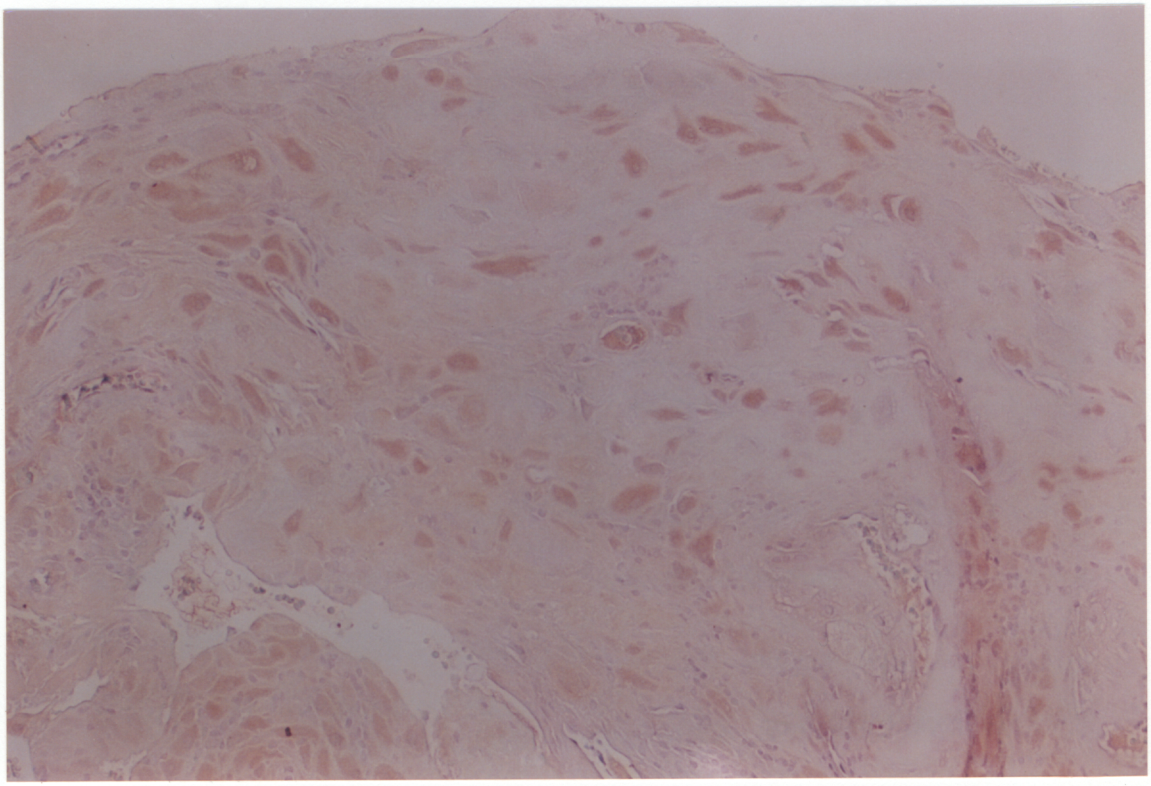

Figure 6-1B. (x 250) Non-immune antibody staining (negative control).

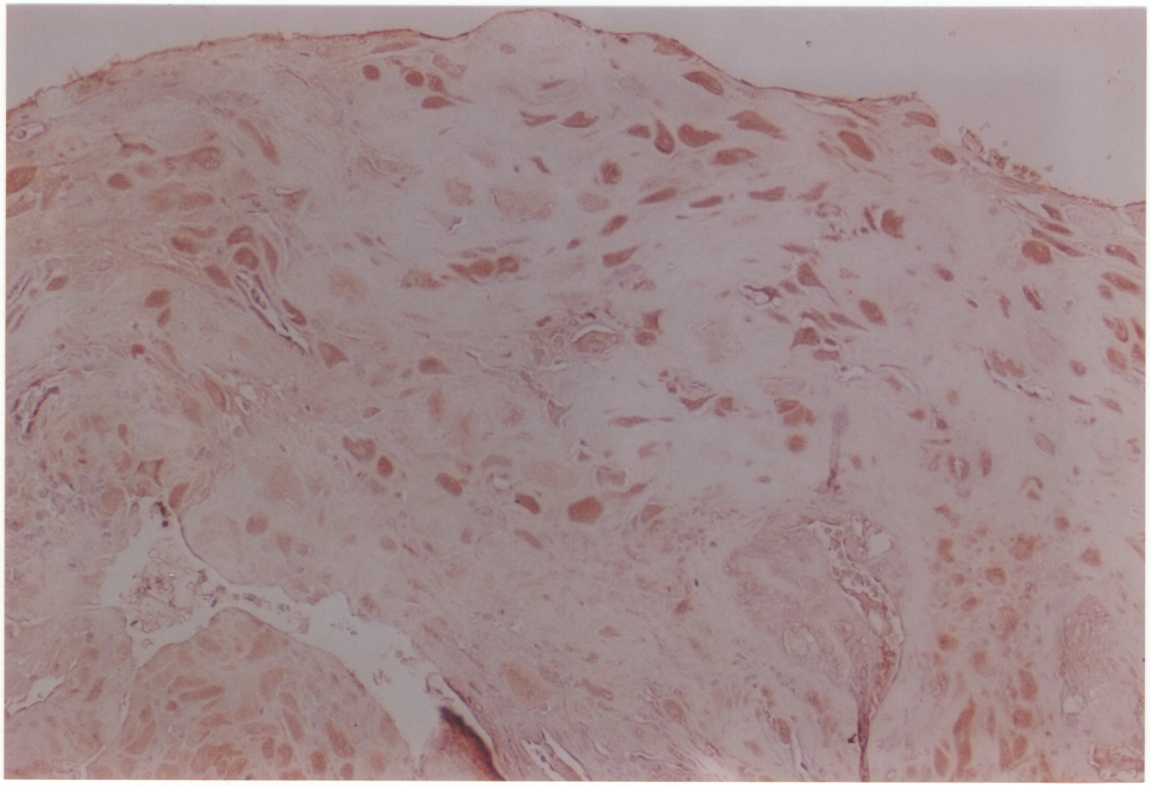

Figure 6-1C. (x 250) Anti-IL-12 antibody staining.

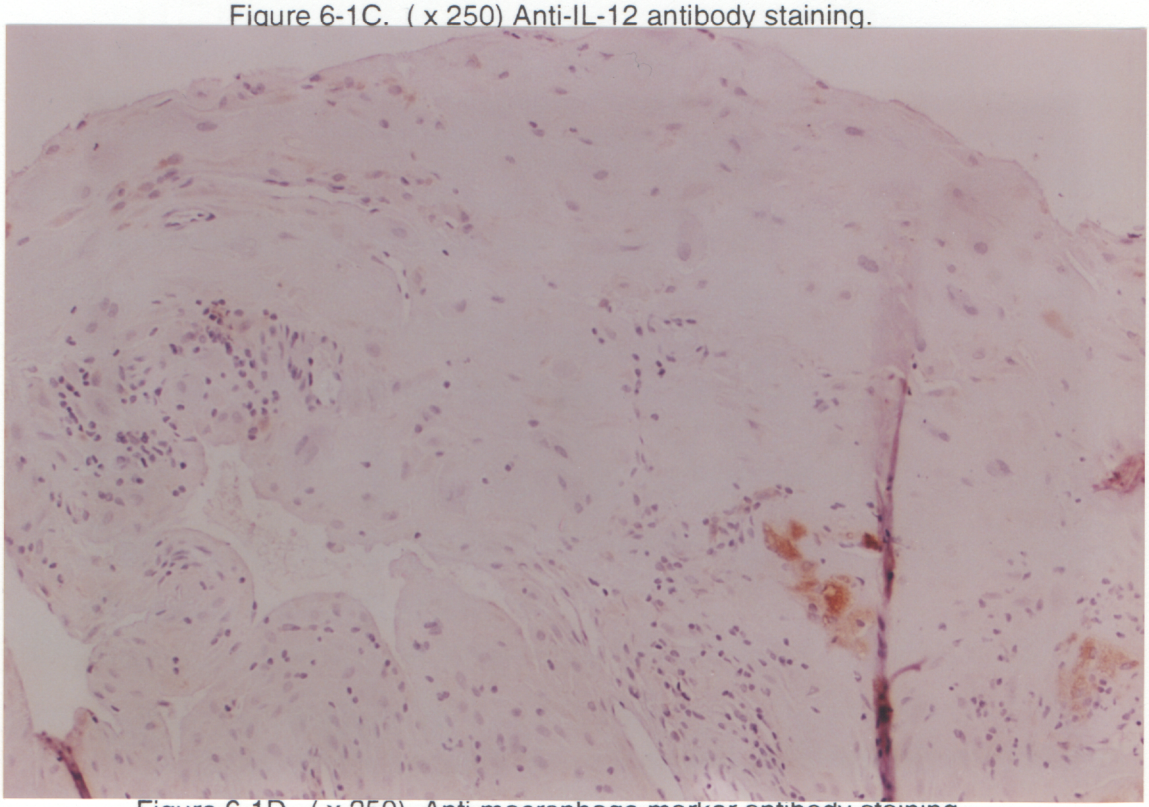

Figure 6-1D. (x 250) Anti-macrophage marker antibody staining.

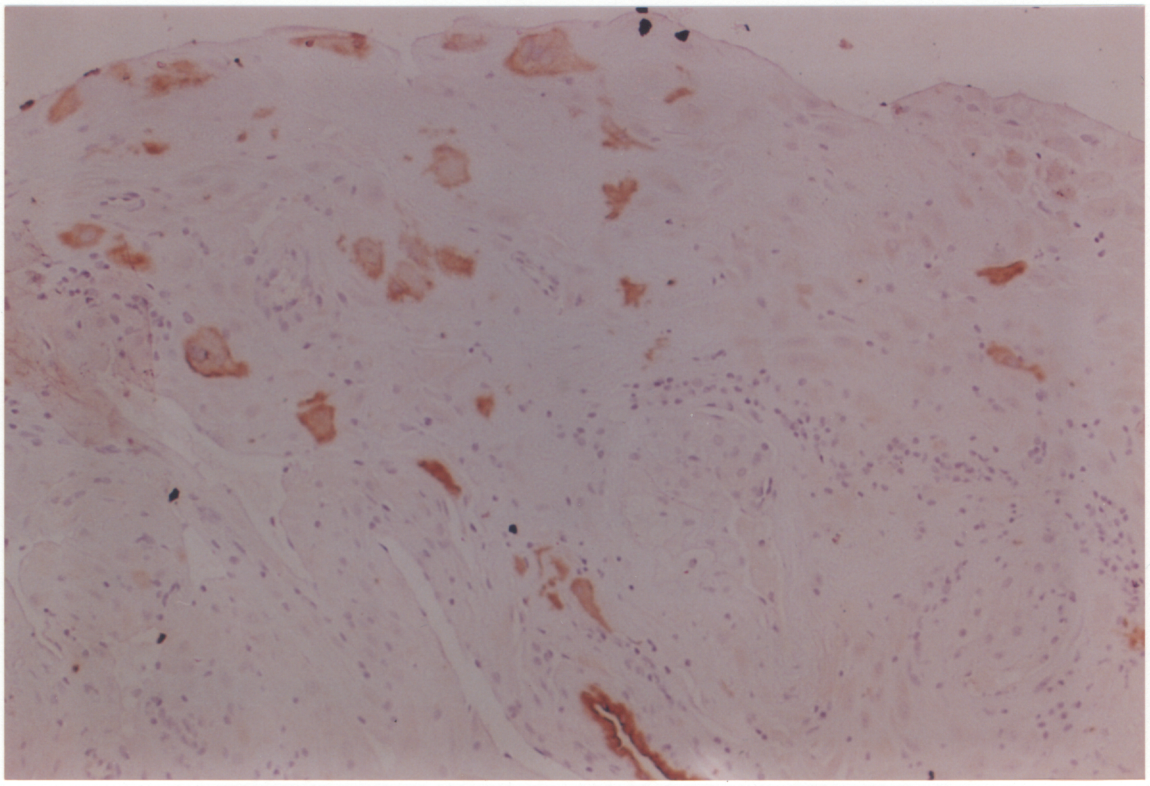

Figure 6-1E. (x 250) Anti-cytokeratin antibody staining.

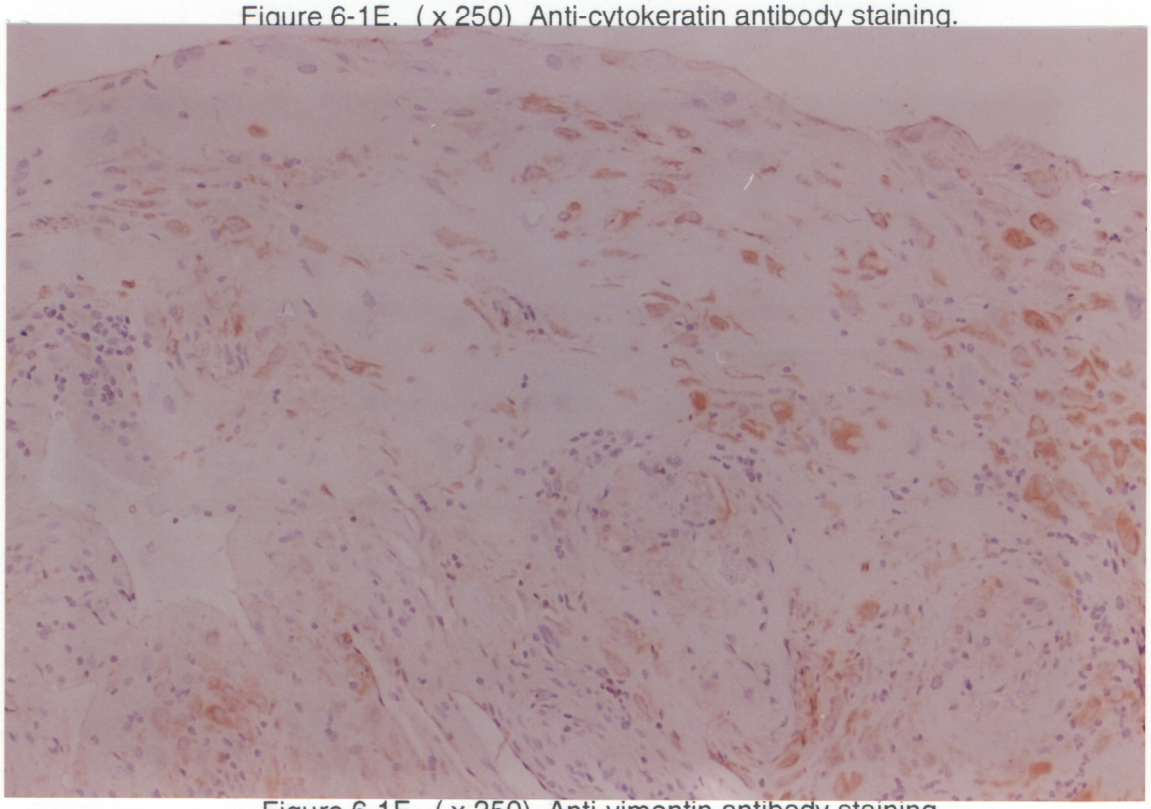

Figure 6-1F. (x 250) Anti-vimentin antibody staining.

REFERENCES

[1] Mitchell MD, Trautman MS, Duddley DJ. Cytokine networking in the placenta. Placenta. 1993;14:249-75.

[2] Daiter E, Pollard JW. Colony stimulating factor-1 (CSF-1) in pregnancy. Reprod Med Rev. 1992;1:83-97.

[3] King A, Loke YW. Human uterine large granular lymphocytes: what are they and what is their function? Immunol Today. 1991;12:432-5.

[4] Croy BA, Kiso Y. Granulated metrial gland cells: a natural killer subset of the pregnant murine uterus. Microsc Res Tech. 1993;25:189-200.

[5] Chaouat G, Menu E, Clark DA, Dy M, Minkowski M, Wegmann TG. Control of fetal survival in CBA x DBA/2 mice by lymphokine therapy. J Reprod Fert. 1990;89:447-58.

PART III

DISCUSSION

DISCUSSION

1. The role of M-CSF in normal and hypertensive pregnancy

To examine possible roles of cytokine growth factors in normal and hypertensive pregnancy, the effects of M-CSF and GM-CSF were investigated using trophoblast cells isolated from term placentas (Chapter 1) and serum M-CSF levels at 16th week of gestation were measured (Chapter 2). Also, M-CSF was administered to pregnant rats, and the effects were evaluated based on histopathology of placentas and pregnancy outcomes (Chapter 5). In addition, the immunohistochemical localization of M-CSF and IL-12 in placental bed specimens was attempted (Chapter 6).

1-1. *In vitro* studies (Chapter 1)

According to previous reports, M-CSF and GM-CSF increase proliferation of trophoblast cells and accelerate giant cell formation.[1,2] Therefore, growth rates of, and giant cell formation by, normal and preeclamptic trophoblast cells after the addition of either M-CSF or GM-CSF were measured. In summary, the reported effects of these cytokines were not observed. Although the exact reason for this is unknown, it may be speculated that these *in vitro* studies might have been hampered by the nature of the specimens which were disaggregated syncytiotrophoblast cells obtained from term pregnant women. These trophoblast cells might have already passed a critical differentiation point. Indeed, growth promoting effects of M-CSF are all reported using trophoblast cells isolated from the first trimester placentas.[1] In contrast to term trophoblast cells, choriocarcinoma cells, which are considered to simulate trophoblast cells early in gestation, did show increased proliferation after M-CSF and GM-CSF treatment. Therefore, it appears that the use of specimens from early trimesters would be critical. However, since preeclampsia is not

predictable prior to clinical manifestation, those early trimester specimens are impossible to obtain at present. Accordingly, term trophoblast cells were used simply because they were the only trophoblast cells available to us.

1-2. Serum M-CSF levels (Chapter 2)

In contrast to placental bed specimens, blood samples are readily available, particularly at the 16th week of gestation when pregnant women are screened for fetal abnormalities. Therefore, serum levels of M-CSF were measured at the time placentas are rapidly growing and trophoblast cells are invading.

Pregnant women who later developed preeclampsia had the lowest concentration of M-CSF although the difference was not statistically significant partly due to the small number of specimens. Also, the serum levels of M-CSF in pregnant women with gestational hypertension were significantly lower than normotensive pregnant women. Although the result does not provide any distinct roles of M-CSF in hypertensive disorders of pregnancy, it warrants further studies.

1-3. The effects of M-CSF in pregnant rats (Chapter 5)

The difference of M-CSF levels was observed at the 16th week of gestation. This is the time period during which trophoblast cells fail to invade maternal spiral arteries in preeclamptic pregnancy. Therefore, the *in vivo* effects of M-CSF on endovascular trophoblast cell invasiveness in pregnant rats were examined.

M-CSF induced several adverse effects on placental development in rats: the growth of trophoblast cells in the future area of the labyrinth and the trophospongium was poor at day 12. In addition, the overall size of placentas was much smaller than control. However, few adverse effects were observed in endovascular trophoblast cells and their invasiveness. Thus far, M-CSF has been considered to have beneficial effects on pregnancy outcomes in mice.[2,3] However, M-CSF also is shown to increase fetal

resorption rates in mice.[4,5] Our results confirmed the latter effects and is the first report in rats. Although the exact cause of M-CSF-induced fetal resorption is unknown, it may be due to poor development of the labyrinth where physiological exchange of nutrients and gases between the mother and fetus occur.

In contrast to the results of M-CSF treatment, anti-M-CSF antibodies had little effect on placental development and pregnancy outcomes. Similar relevant findings are observed by Pollard et al., in which they showed normal placental growth in *op/op* female mice that lack M-CSF, mated with heterozygote males.[6] According to them, seminal and/or fetal M-CSF may be important in female fertility, instead of maternal M-CSF. Alternatively, factors other than M-CSF may compensate the lack of M-CSF. Since pharmacokinetics of anti-M-CSF antibodies in pregnant rats and *in vivo* binding activities are also unknown, further experiments are necessary to conclude the effects of anti-M-CSF antibodies or the roles of M-CSF in rat pregnancy.

1-4. Immunohistochemical localization of M-CSF and IL-12 in human placental beds (Chapter 6)

As described in Chapter 6, immunohistochemical studies appeared to be hindered by non-specific bindings of both anti-M-CSF and anti-IL-12 antibodies. In this study, all primary antibodies were of mouse origin. In short, depending on concentration and incubation conditions, staining patterns of anti-M-CSF, anti-IL-12, and non-immune (control) antibodies became very similar. In contrast, anti-cytokeratin, anti-vimentin, and anti-macrophage marker antibodies showed distinctively different staining patterns. Therefore, the results of immunohistochemical staining of anti-M-CSF and anti-IL-12 antibodies were not suitable for interpretation.

2. Characterization of rat endovascular trophoblast cell behavior in normal and abnormal pregnancy

Since preeclampsia research has inherent difficulties associated with the nature of human pregnancy, research efforts for elucidation of the underlying mechanisms of trophoblast cell invasion must be developed indirectly through studies of experimental animal models. For this purpose, rats were chosen because of their low cost, short gestational periods, and a greater potential for in-depth studies, particularly for molecular approaches.

When using laboratory animals, one of the most important questions is how closely do these models simulate the human condition? In this case, how well do rats simulate particular aspects of human placentation, specifically endovascular trophoblast cell behavior? Therefore, as the first step, normal endovascular trophoblast cell behavior in pregnant rats was characterized morphologically from day 8 through near term (day 20) and divided into several steps. This approach had the advantage of allowing us to compare each step to a corresponding stage in human placentation, rather than extrapolating trophoblast cell behavior as a whole sequence directly to humans.

2-1. Similarity of endovascular trophoblast cell behavior between human and rats (Chapter 3)

Despite the large differences in placental anatomy and the length of gestation, a striking similarity of endovascular trophoblast cell behavior was observed between human and rats, including selective invasion into the spiral arteries, scrolling on the endothelium, embedding, secretion of PAS-positive materials, and "physiological changes." This is the first detailed description of a sequence of endovascular trophoblast cell invasion in rats. Although this characterization was based on morphological observation, the data are promising and warrant further studies. By taking advantage of

laboratory animals, the investigation of a molecular basis of endovascular trophoblast cell behavior *in vivo* will be facilitated.

2-2. Possible factors that govern selective invasion of endovascular trophoblast cell (Chapter 3)

Since selective interactions with the endothelium are extensively demonstrated in leukocyte homing/trafficking and tumor metastasis, the behavior of endovascular trophoblast cells was compared to that of these processes. For this purpose, trophoblast cell behavior was divided into three steps: attachment, scrolling, and embedding. Initially, attention was placed on the similarity of events between these cell types. However, with a closer analysis, the differences were more apparent than similarities. For example, leukocytes and tumor cells interact with the endothelium of venules, roll down, and diapede into the interstitial space, whereas endovascular trophoblast cells interact with arteries, scroll up against the flow of blood, and finally embed into the vessel walls after replacing endothelial cells. Among these events, only attachment to the endothelium may be fundamentally the same because (1) rat trophoblast cells *selectively* attach to the particular sites of the vasculature (placental spiral arteries), as in leukocyte trafficking, (2) morphological changes (*"priming effects"*) of the endothelial cells observed at the spiral arteries in pregnant rats were very similar to those at leukocyte trafficking sites, and (3) a large number of leukocytes attached to the placental spiral arteries when endovascular trophoblast cells did. All of these data suggest that during pregnancy, placental spiral arteries may express a set of cell adhesion molecules to provide a suitable environment for endovascular trophoblast cell attachment, as shown in leukocyte trafficking sites.

2-3. Modulation of endovascular trophoblast cell invasiveness (Chapter 3)

To investigate the underlying mechanisms of the scrolling activity unique to endovascular trophoblast cells, cytochalasin B, an actin filament disorganizing chemical

was administered to pregnant rats. This is one of the most widely used chemicals in cell locomotion studies, but the first in trophoblast cell research. Cytochalasin B blocked the migration of trophoblast cells into the spiral arteries at day 12. Therefore, actin filament appears important in trophoblast cell locomotion, as in other diverse cells. This is the first successful report demonstrating *in vivo* pharmacological modulation of endovascular trophoblast cell invasiveness without terminating pregnancy.

2-4. Priming effects of the spiral arteries (Chapter 3)

Before endovascular trophoblast cell invasion, the spiral arteries underwent various morphological changes, such as swelling of endothelial cells, disorganization/loss of smooth muscle cells, and accumulation of GMG cells. Since these alterations were observed only in arteries that receive endovascular trophoblast cell invasion and were completed before invasion, these 'priming' effects may be a prerequisite for endovascular trophoblast cell invasion. Similar 'priming' effects are also observed in humans. The significance of 'priming' effects will be discussed in detail later, with respect to the etiology of preeclampsia (see "3. Etiology of preeclampsia").

2-5. Topology of endovascular trophoblast cells (Chapter 3)

The topology of endovascular trophoblast cells in rat placentas was interesting. Trophoblast cells were frequently observed in the inside of each curve of the arteries in the mesometrial triangle area. Since the flow of blood in the 'spiral' arteries is expected to be asymmetrical (the fastest in the outside and the slowest in the inside), the unique structure of 'spiral' arteries might have been beneficial for endovascular trophoblast cell migration by providing better a hemodynamic milieu .

2-6. IL-12 treatment of pregnant rats (Chapter 5)

Since granulated metrial gland (GMG) cells around the spiral arteries in rats are suggested to be of NK cell origin, and administration of IL-2 or poly-IC (NK cell activators), to pregnant mice are associated with a high incidence of fetal resorption, I hypothesized the activation of GMG cells with its specific activator, IL-12, may cause adverse pregnancy outcomes. However, IL-12 treated rats had normal placental development at both days 12 and 20 although the fetuses were smaller. Accumulation of GMG cells around the spiral arteries and their morphological changes appeared normal. Therefore, if this cytokine (human recombinant IL-12) has species cross-reactivity with rats, the results suggest that GMG cells are not a NK cell origin or that activation of NK cells has few maternal effects in rats, but may have some effects on fetal development.

2-7. Characterization of endovascular trophoblast cell behavior in rats - abnormal pregnancy (Chapter 4)

Table D-1 summarizes spontaneous fetal resorption in rats. In type 2 resorption, endovascular trophoblast cells behaved normally and completed all processes. Also, despite severe inflammatory reactions, endovascular trophoblast cells but not other types of trophoblast cells could be observed. Therefore, endovascular trophoblast cells appear to be an unlikely cause of fetal resorption in type 2. In contrast, in type 3 resorption, invasion by endovascular trophoblast cells was inappropriately shallow and their number was much smaller than normal. In addition, no embedding nor secretion of PAS-positive materials by endovascular trophoblast cells was observed although endothelial cells contacting trophoblast cells disappeared. Interestingly, in both types of fetal resorption, there was no evidence of 'maternal rejection' to endovascular trophoblast cells since in type 2, they survived better than other types of trophoblast cells. Similarly, in type 3 resorption, endovascular trophoblast cells in the lumen appeared intact. Therefore,

putative maternal immune responses to endovascular trophoblast cells are an unlikely cause of fetal resorption in rats. Characteristics of endovascular trophoblast cells in type 3 fetal resorption are very similar to those observed in preeclamptic pregnancy.

Table D-1. Three types of spontaneous fetal resorption in rats.

		Type 1	Type 2	Type 3
Endovascular trophoblast cell behavior	Attachment & scrolling	N/A	Normal but arrested probably at the time of pregnancy loss	Shallow
	Embedding & secretion of PAS (+) materials	N/A	Normal	None
Other types of trophoblast cells		N/A	Difficult to identify	Normal
Inflammatory reactions		Strong	Strong	None

3. Etiology of preeclampsia - a hypothesis

3-1. Endovascular trophoblast cell behavior in preeclamptic pregnancy

In the past, based on defective transformation of the spiral arteries in preeclamptic pregnancy, endovascular trophoblast cells have been considered simply to fail to invade the spiral arteries deep enough.[7] However, in addition to restricted invasion, there appear other defects: endovascular trophoblast cells fail to embed into the vessel wall since they often remain present on the surface of the endothelium even at term,[8,9] a phenomena not usually observed in normal pregnancy. Endothelial cells contacting these luminal trophoblast cells are reported to disappear.[9] Thus, the defects in preeclamptic endovascular trophoblast cells are considered to be multiple, which has exciting similarities with endovascular trophoblast cell behavior observed in type 3 fetal resorption in rats (shallow invasion and failure of embedding). If so, what factors regulate these

trophoblast cell behaviors, in normal and abnormal pregnancies? Identification of such factors may become potential therapeutic targets in preeclamptic pregnancy in the future.

3-2. Transplantation study by Billington

With respect to endovascular trophoblast cell behavior in the arteries, Billington conducted a very insightful study in 1966,[10] in which he transplanted hamster trophoblast cells to ectopic sites, i.e., testis. Trophoblast cells not only found and preferentially invaded the arteries, but also moved against the flow of arterial blood. However, they remained present in the lumen and appeared not to induce "physiological changes" even 12 days after transplantation, a time period sufficient for "physiological changes" to develop in normal pregnancy in the hamster (Figure D-1).[11] Legrand et al. confirmed Billington's observation later.[12]

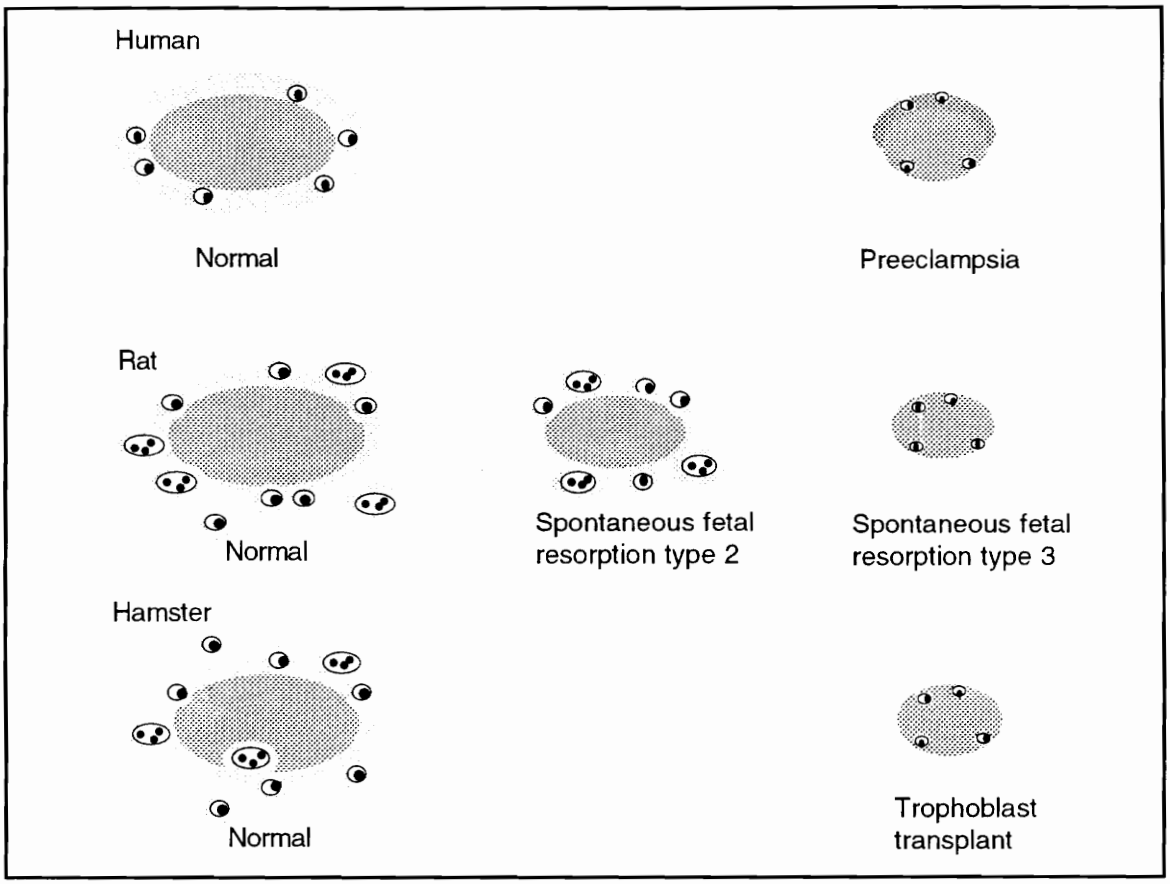

Figure D-1. Defective trophoblast cell behavior was observed in type 3 of spontaneous fetal resorption in rats (middle), which is similar to that in preeclamptic pregnancy (top) and in ectopic transplantation of trophoblast cells in hamsters reported by Billington (bottom). These similarities provide some clues regarding mechanisms controlling trophoblast cell behavior.

Results of Billington's study suggest that for endovascular trophoblast cells to complete normal processes, 'conditioning' of the arteries may be necessary since he used presumably normal trophoblast cells. In other words, embedding and subsequent "physiological changes" may be an event specific to the spiral arteries of placental beds, which may have unique milieu *in situ*.

3-3. Two parts of "physiological changes"

It is intriguing that the spiral arteries undergo various morphological changes prior to endovascular trophoblast cell invasion. As mentioned before, swelling of the endothelial cells, disorganization and loss of smooth muscle cells, and accumulation of GMG cells around the spiral arteries was observed (Chapter 3).[13] These changes are also reported in other species including hamster,[11,14] guinea pig,[15,16] macaque,[17] and man.[18] Electron microscopic study is in accordance with light microscopic observation in humans.[19] All of these alterations are pronounced in the placental spiral arteries where trophoblast cells invade. Similar to rats, in humans, the migration of endovascular trophoblast cells into the myometrial portion of the spiral arteries is found only when the morphological alterations described above were complete.[18]

Thus, although the exact cause-effect relationship is still unknown, based on histological observation, the purpose of these pre-invasion morphological changes of the spiral arteries may be to help endovascular trophoblast cells interact with the spiral arteries properly.[20] Proper endovascular trophoblast cell invasion induces adequate "physiological changes" later in pregnancy, resulting in better physiological exchange. Since they could be considered to be part of normal placentation, it may be proposed that the term "physiological changes" be expanded to include morphological alterations of the spiral arteries, both before and after endovascular trophoblast cell invasion. Thus far, most attention has been paid to the latter aspect. However, if 'priming' of the spiral arteries is a prerequisite for normal behavior of endovascular trophoblast cells, and its defects lead to shallow invasion, the first part of "physiological changes" should receive more attention.[21]

Thus, it is tempting to think that abnormal behavior of endovascular trophoblast cells observed in type 3 fetal resorption and preeclamptic pregnancy is due to defective

conditioning or 'priming' of the spiral arteries,[22] rather than as a result of abnormalities in trophoblast cells themselves. There are several lines of evidence that support this idea.

3-4. Preeclampsia superimposed on diabetes and previous hypertension

If the above hypothesis is correct, women with medical conditions that affect arterial vessels may have an increased incidence of preeclampsia because of potential adverse effects on the spiral arteries. Indeed, women with chronic hypertension whether essential or renal,[23,24] diabetes mellitus, and systemic vascular diseases,[25] all of these are known to be associated with structural and functional disturbances of blood vessels, and are shown to be at a higher risk for developing preeclampsia. Moreover, pregnant women with diabetes or hypertension sometimes have impaired endovascular trophoblast cell invasion, complete or partial, even without clinical manifestation of preeclampsia.[8,22,26,27] Accordingly, an increased incidence of preeclampsia in above medical conditions may be explained by a break in the normal interactions of endovascular trophoblast cells with the spiral arteries. Although the exact mechanisms by which the spiral arteries are affected is unknown, there is substantial evidence that both hypertension and diabetes mellitus induce morphological and functional alterations of arteries, in general.

For example, hypertension induces the proliferation of endothelial cells and increases the thickness of the vessel walls.[28] Adverse effects of hypertension are not limited to these structural changes but include functional disturbances of endothelial cells and smooth muscles.[29] More recently, hypertension is reported to affect the expression of cell adhesion molecules on the endothelium in rats,[30,31] and has been demonstrated to induce over-expression of tenascin by vascular smooth muscle cells in tunica media.[32] Tenascin is an important extracellular matrix in tissue remodeling.

Similarly, diabetes mellitus is associated with various morphological changes and dysfunction of vessels including hyperplasia of endothelial cells, thickening of basement membranes,[33] and altered expression of cell adhesion molecules.[34] Interestingly, the 'priming' effects of the spiral arteries (or the first part of "physiological changes") observed in streptozotocin-induced diabetic rats during pseudopregnancy were less marked compared to those of normal pregnant rats.[35] Diabetic pregnant rats are known to be associated with decreased placental blood flow, an increased fetal resorption rate, growth retardation and smaller fetuses.[36,37]

Thus, there is substantial evidence that underlying medical conditions, particularly hypertension and diabetes mellitus, affect both structures and functions of the arteries. Consequently, "priming" of the spiral arteries may be impaired, leading to abnormal interaction of endovascular trophoblast cells with the spiral arteries, e.g., shallow invasion.

3-5. Selective impairment of trophoblast cell invasion in preeclamptic pregnancy

Above hypothesis is also supported by behavior of extravillous trophoblast cells in preeclamptic pregnancy. Since the effects of previous hypertension and diabetes are considered to be much stronger on the vascular components than the interstitial space, it is expected that endovascular trophoblast cell behavior is primarily affected rather than that of interstitial trophoblast cells. Indeed, this is the topology of trophoblast cells in preeclamptic pregnancy, in which the depth of interstitial trophoblast cell invasion is normal, in the face of shallow invasion of endovascular trophoblast cells, whether preeclampsia is primary or superimposed.[38,39] In both normal and preeclamptic pregnancy, the presence of interstitial trophoblast cells is used as evidence that biopsy materials are indeed from placental beds.[40]

3-6. Conclusion

Since *all* preeclamptic women whether primary or superimposed have defective endovascular trophoblast cell invasion, factors that affect the trophoblast cell behavior on the spiral arteries are considered to be critical in understanding the etiology of this disorder. Although the defects may exist in both trophoblast cells and the spiral arteries, the latter appears more important. This is because of the fact that various maternal medical conditions known as a predisposing factor for the development of preeclampsia, are associated with vascular diseases as a common feature.

Behaviors of endovascular trophoblast cells in rats (type 3 fetal resorption), hamster (trophoblast cell transplantation), and preeclamptic women, also suggest that the defects exist on maternal arteries, specifically the spiral arteries. If the hypothesis that defective 'priming' of the spiral arteries is associated with shallow invasion, is proved to be correct, the spiral arteries may not be 'suitable soil' for endovascular trophoblast cell interaction.

So far, an increased incidence of preeclampsia has been explained by the adverse effects of underlying medical conditions on systemic endothelial cells, which may aggravate the effects of putative cytotoxic factors. However, this hypothesis cannot explain shallow invasion, which occurs much earlier than the production of putative cytotoxic factors. Therefore, if underlying medical conditions affect the spiral arteries as well as systemic arteries, we can explain abnormal endovascular trophoblast cell behavior in women who are destined to develop superimposed preeclampsia. Thus, this hypothesis has the advantage of explaining the etiology of preeclampsia.

REFERENCES

[1] Saito S, Ibaraki T, Enomoto M, Ichijo M, Motoyoshi K. Macrophage colony-stimulating factor induces the growth and differentiation of normal pregnancy human cytotrophoblast cells and hydatidiform moles but does not induce the growth and differentiation of choriocarcinoma cells. Jpn J Cancer Res. 1994;85:245-52.

[2] Armstrong DT, Chaouat G. Effects of lymphokines and immune complexes on murine placental cell growth in vitro. Biol Reprod. 1989;40:466-74.

[3] Athanassakis I, Bleackley RC, Paerktau V, Guilbert L, Barr P, Wegmann TG. The immunostimulatory effect of T cells and T cells lymphokines on murine fetally derived placental cells. J Immunol. 1987;138:37-44.

[4] Tartakovsky B. CSF-1 induces resorption of embryos in mice. Immunol Letters. 1989;23:65-70.

[5] Tartakovsky B, Goldstain O, Brosh N. Colony-stimulating factor-1 blocks early pregnancy in mice. Biol Reprod. 1991;44:906-12.

[6] Pollard JW, Hunt JS, Wiktor-Jedrzejczak W, Stanley ER. A pregnancy defect in the osteopetrotic (op/op) mouse demonstrate the requirement for CSF-1 in female fertility. Develop Biol. 1991;148:273-83.

[7] Brosens I, Robertson WB, Dixon HG. The role of the spiral arteries in the pathogenesis of pre-eclampsia. Obstet Gynecol Ann. 1972;1:177-91.

[8] Khong TY, De Wolf F, Robertson WB, Brosens I. Inadequate maternal vascular response to placentation in pregnancies complicated by preeclampsia and by small-for-gestational age infants. Br J Obstet Gynaecol. 1986;93:1049-59.

[9] Khong TY, Sawyer IH, Heryet AR. An immunohistologic study of endothelialization of uteroplacental vessels in human pregnancy - Evidence that endothelium is focally disrupted by trophoblast in preeclampsia. Am J Obstet Gynecol. 1992;167:751-6.

[10] Billington WD. Vascular migration of transplanted trophoblast in the Golden hamster. Nature 1966;211:988-9.

[11] Pijnenborg R, Robertson WB, Brosens I. The arterial migration of trophoblast in the uterus of the golden hamster, *Mesocricetus auratus*. J Reprod Fert. 1974;40:269-80.

[12] Legrand C, Hernadez-Verdun D. Donnees autoradiographiques sur la differenciation du trophoblaste, apres transplantation intra-testicular d'embryons, chez le hamster dore. Cytobiologie. 1974;8:457-67.

[13] Endo Y. Chapter 3. Endovascular trophoblast cell behavior in normal pregnant rats. Ph.D thesis. 1995.

[14] Ward Orsini M. The trophoblastic giant cells and endovascular cells associated with pregnancy in the hamster, *Cricetus auratus*. Am J Anat. 1954;94:273-331.

[15] Albert EN, Pease DC. An electron microscopic study of uterine arteries during pregnancy. Am J Anat. 1968;123:165-94.

[16] Albert EN. The effect of pregnancy on the elastic membranes of mesometrial arteries in the guinea pig. Am J Anat. 1967;120:611-26.

[17] Enders AC, King BF. Early stages of trophoblastic invasion of the maternal vascular system during implantation in the Macaque and Baboon. Am J Anat. 1991;192:329-46.

[18] Pijnenborg R, Bland JM, Robertson WB, Brosens I. Uteroplacental arterial changes related to interstitial trophoblast migration in early human pregnancy. Placenta. 1983;4:397-414.

[19] De Wolf F, De Wolf-Peeters C, Brosens I, Robertson WB. The human placental bed: electron microscopic study of trophoblastic invasion of spiral arteries. Am J Obstet Gynecol. 1980;137:58-70.

[20] Pijnenborg, R. Trophoblast invasion and placentation in the human: morphological aspects. In: Trophoblast research Vol. 4. Denker HW and Aplin JD (ed). Plenum Publishing. 1990. p.33-47.

[21] Formation of uteroplacental arteries during pregnancy may be best compared to making roads: when we build a satellite city (fetus) near a large city (mother), we need good infrastructure (placentas) including roads (uteroplacental arteries) to allow smooth transportation of people and goods (blood containing oxygen and nutrients) from the mother city to a growing one. To construct 12 lane roads (uteroplacental arteries), we have to first dig the ground and put stones (the first part of "physiological changes"), then pave it (the latter part of "physiological changes"). After completion of construction, underlying foundation/preparation is hardly seen. However, good roads always have it. Without it, roads may not be able to sustain heavy traffic and may soon be damaged (an increased frequency of vascular lesions in preeclamptic pregnancy). In that case, we have to repair it with decreased load (reduced blood supply to the intervillous space). At the same time, we attempt to accommodate the situation (development of compensatory mechanisms), and/or to slow down the growth of a satellite city (fetal growth retardation).

[22] Pijnenborg R, Anthony J, Davey DA, Rees A, Tiltman A, Vercruysse L, Van Assche A. Placental bed spiral arteries in the hypertensive disorders of pregnancy. Br J Obstet Gynaecol. 1991;98:648-55.

[23] Rey E, Couturier A. The prognosis of pregnancy in women with chronic hypertension. Am J Obstet Gynecol. 1994;171:410-6.

[24] Mabie WC, Pernoll ML, Biswas MK. Chronic hypertension in pregnancy. Obstet Gynecol. 1986;67:197-205.

[25] Chesley LC. Epidemiology of preeclampsia-eclampsia. In: Hypertensive disorders in pregnancy. Chesley LC (ed.) New Tork, Appleton-Century Crofts. 1978. p38-40.

[26] Sheppard BL, Bonnar J. An ultrastructural study of uteroplacental spiral arteries in hypertensive and normotensive pregnancy and fetal growth retardation. Br J Obstet Gynaecol. 1981;88:695-705.

[27] Robertson WB, Brosens I, Dixons G. Uteroplacental vascular pathology. Eur J Obstet Gynec Reprod Biol. 1975;5:47-65.

[28] Prewitt RL, Hashimoto H, Stacy DL. Structural and functional rarefaction of microvessels in hypertension. In: Blood vessel changes in hypertension: structure and function. Volume 2. Lee RMKW (ed). CRC Press, Boca Raton, Florida. 1988. p.71-89.

[29] Mulvany MJ, Hansen PK, Aalkjaer C. Direct evidence that the greater contractility of resistance vessels in spontaneously hypertensive rats is associated with a narrowed lumen, a thickened media, and an increased number of smooth muscle cell layers. Cir Res. 1978;43:854.

[30] Suzuki H, Schmid-Schonbein GW, Suematsu M, DeLano FA, Forrest MJ, Miyasaki M, Zweifach BW. Impaired leukocyte-endothelial cell interaction in spontaneously hypertensive rats. Hypertension 1994;24:719-27.

[31] McCarron RM, Wang L, Siren AL, Spatz M, Hallenbeck JM. Adhesion molecules on normotensive and hypertensive rat brain endothelial cells. P. S. E. B. M. 1994;205:257-62.

[32] Mackie EJ, Scott-burden T, Hahn AW, Kern F, Bernhardt J, Regenass S. Expression of tenascin by vascular smooth muscle cells. Alterations in hypertensive rats and stimulation by angiotensin II. Am J Pathol. 1992;141:377-88.

[33] Sank A, Wei D, Reid J, Ertl D, Nimni M, Weaver F, Yellin A, Tuan TL. Human endothelial cells are defective in diabetic vascular disease. J Surg Res 1994;57:647-53.

[34] Roth T, Podesta F, Stepp MA, Boeri D, Lorenzi M. Integrin overexpression induced by high glucose and by human diabetes: potential pathway to cell dysfunction in diabetic microangiopathy. Proc Natl Acad Sci USA. 1993;90:9640-4.

[35] Norambuena J, Pijnenborg R, Brosens I. Decidual changes in the endometrium and morphological adaptation of the associated supplying arteries in the normal and diabetic pseudopregnant rat. Placenta. 1984;5:249-60.

[36] Eriksson UJ, Jansson L. Diabetes in pregnancy: decreased placental blood flow and disturbed fetal development in the rat. Pediatr Res. 1984;18:735-8.

[37] Eriksson UJ. Diabetes in pregnancy: retarded fetal growth, congenital malformations and feto-maternal concentrations of zinc, copper and manganese in the rat. J Nutr. 1984;114:477-84.

[38] Pijnenborg R. Uteroplacental ischemia and hypertensive disorders of pregnancy. Issues in Nephrosciences 1.91. Milano, Italy. Wichtig Editore. 1991. p8-13.

[39] Gerretsen G, Huisjes HJ, Hardonk MJ, Elema JD. Trophoblast alterations in the placental bed in relation to physiological changes in spiral arteries. Br J Obstet Gynaecol. 1983;90:34-9.

[40] Robertson WB, Khong TY, Brosens I, De Wolf F, Sheppard BL, Bonnar J. The placental bed biopsy: Review from the European centers. Am J Obstet Gynecol. 1986;155:401-12.

CONCLUSIONS

1. Cultured term trophoblast cells obtained from normal and hypertensive pregnant women did not respond to either M-CSF and GM-CSF. However, choriocarcinoma cells showed increased proliferation after M-CSF and GM-CSF treatment.

2. Serum M-CSF levels of hypertensive pregnant women were significantly lower than those of normotensive pregnant women at 16th week of gestation. The result warrants further studies for possible involvement of M-CSF in preeclampsia. However, because of the nature of pregnancy, in-depth studies utilizing trophoblast cells from preeclamptic trophoblast cells are difficult to conduct.

3. Normal behavior of rat endovascular trophoblast cells were characterized morphologically. Striking similarities between human and rats were documented , including selective invasion into the spiral arteries, scrolling, embedding and secretion of PAS positive materials. Therefore, rats appear useful for the study of underlying mechanisms of endovascular trophoblast cell behavior.

In addition, endovascular trophoblast cell invasiveness was successively modulated pharmacologically *in vivo* without terminating pregnancy. Cytochalasin B, an actin filament disorganizing chemical was used in trophoblast cell research for the first time. The results suggest the importance of cytoskeleton in trophoblast cell locomotion.

4. Endovascular trophoblast cell behavior in abnormal pregnancy in rats was characterized. In a certain type of fetal resorption, defects in endovascular trophoblast behavior were similar to those reported in preeclamptic pregnancy, further supporting the

idea that a rat model is useful for the study of trophoblast cell behavior, with clinical relevance to preeclampsia.

5. rhM-CSF and rhIL-12 were administered to pregnant rats. M-CSF treatment was associated with an increased fetal resorption rate but endovascular trophoblast cell behavior appeared normal. IL-12 did not induce morphological abnormalities in placentas but was associated with smaller fetuses at day 20.

6. Interpretation of the results of immunohistochemical staining of anti-M-CSF and anti-IL-12 antibodies on placental bed specimens was hindered since non-specific binding of these antibodies was strongly suspected.

In summary, in the first part of the study, difficulties associated with the nature of pregnancy were realized when evaluating trophoblast cell responses *in vitro*. In contrast, a rat model appears promising by offering distinct advantages as being laboratory animals while simulating many aspects of endovascular trophoblast cell behavior in human.

Future Directions

The results and conclusion reported in this dissertation suggest a number of possibilities for future works.

1. Endovascular trophoblast cell behavior could be further characterized using molecular approaches, e.g., (1) identification of adhesive mechanisms between trophoblast cells and endothelial cells of the spiral arteries, (2) assessment of the functional roles of each adhesion molecule by administering antibodies against various cell adhesion molecules to pregnant rats and then evaluating endovascular trophoblast cell invasiveness *in situ*, and (3) evaluation of the degree of "priming" effects of the spiral arteries and endovascular trophoblast cell invasiveness in chronically induced streptozotocin diabetic and hypertensive pregnant rats (risk factors for the development of preeclampsia).

2. Serum levels of circulating CAMs could be measured in rats at different gestational days, and correlation with endovascular trophoblast cell invasiveness/behavior that was characterized in this study attempted. This may provide a non-invasive method to monitor endovascular trophoblast cell invasiveness. Similar approaches could then be made in normal and preeclamptic pregnant women. In many disease conditions, increased or decreased concentrations of CAMs are demonstrated in the sera of patients.

3. A new *in vitro* model could be developed: Endothelial cells could be seeded onto extracellular matrix (ECM) extracted from placentas of pregnant rats at different gestational days. This will allow evaluation of the effects of ECM on the "priming" effects of endothelial cells. Also, co-culture of trophoblast and GMG cells could be attempted with

similar endpoints. Furthermore, he effects of known-CAM inducers on trophoblast cell attachment could be attempted both *in vivo* and *in vitro*.

4. The results of the above studies could provide us with (1) molecular mechanisms of trophoblast cell attachment to the spiral arteries, (2) monitoring methods of CAM expression, hence endovascular trophoblast cell invasiveness (prediction of preeclampsia), and (3) pharmacological methods to modulate CAM expression on the spiral arteries (prevention of preeclampsia).

PART IV

LITERATURE

LITERATURE CITED

Albert EN. The effect of pregnancy on the elastic membranes of mesometrial arteries in the guinea pig. Am J Anat. 1967;120:611-26.

Albert EN, Pease DC. An electron microscopic study of uterine arteries during pregnancy. Am J Anat. 1968;123:165-94.

Alberts B et al. (ed). The cytoskeleton. In: Molecular biology of the cell. New York, Garland Publishing. 1994. p787-861.

Altchek A, Albright NL, Sommers SC. The renal pathology of toxemia of pregnancy. Obstet Gynecol. 1968;31:595-607

Aplin JD. Expression of integrin $\alpha 6\beta 4$ in human trophoblast and its loss from extravillous cells. Placenta. 1993;14:203-15.

Arceci R, Shanahan JF, Stanley ER, Pollard JW. Temporal expression and location of colony-stimulating factor 1 (CSF-1) and its receptor in the female reproductive tract development. Proc Natl Acad Sci. 1989;86:8818-22.

Armstrong DT, Chaouat G. Effects of lymphokines and immune complexes on murine placental cell growth in vitro. Biol Reprod. 1989;40:466-74.

Athanassakis I, Bleackley RC, Paetkau L, Barr PJ, Wegmann TG. The immunostimulatory effects of T cells and T cell lymphokines on murine fetally derived placental cells. J Immunol. 1987;138:37-44.

Bartocci A, Pollard JW, Stanley ER. Regulation of colony stimulating factor 1 during pregnancy. J Exp Med. 1986;164:956-61.

Berkowitz RS, Goldstein DP. Gestational trophoblastic disease. In: Moosa AR et. al. (ed). Comprehensive textbook of oncology. Baltimore, Williams & Wilkins Co. 1989.

Billington WD. Vascular migration of transplanted trophoblast in the Golden hamster. Nature 1966;211:988-9.

Blankenship TN, Enders AC, King BF. Trophoblastic invasion and the development of uteroplacental arteries in the macaque: immunohistochemical localization of cytokeratins, desmin, type IV collagen, laminin, and fibronectin. Cell Tissue Res. 1993;272:227-36.

Blankenship TN, Enders AC, King BF. Trophoblastic invasion and modification of uterine veins during placental development in macaques. Cell Tissue Res. 1993;274:135-44.

Bousquet PF, Paulsen LA, Fondy C, Lipski KM, Loucy KJ, Fondy TP. Effects of cytochalasin B in culture and *in vivo* on murine Madison 109 lung carcinoma and on B16 melanoma. Cancer Res. 1990;50:1431-9.

Boyd J, Hamilton WJ. The human plancenta. Heffer and Sons Co. Cambridge. 1970.

Brettoner A. Zum Verhalten der Sekundaren. Wand der Uteroplacentargefasse bei der decidualen Reaktion. Acta anatomica. 1964;57:367-76.

Bridgeman J. A morphological study of the development of the placenta of the rat. I. An outline of the development of the placenta of the white rat. J Morphol. 1948;83:61-85.

Bridgeman J. A morphological study of the development of the placenta of the rat. II. An histoplogical and cytological study of the development of the chorioallantoic placenta of the white rat. J Morphol. 1948;83:195-223.

Brosens I, Robertson WB, Dixon HG. The physiological response to the vessels of the placental bed to normal pregnancy. J Pathol Bacteriol. 1967;93:569-79.

Brosens I, Robertson WB, Dixon HG. The role of the spiral arteries in the pathogenesis of pre-eclampsia. Obstet Gynecol Ann. 1972;1:177-91.

Brosh N, Lotan M, Eisenbach L, Brocke S, Tartakovsky B. Fertility impairment and improved fetal survival induced by a tumor cell line in mice. Am J Reprod Immunol. 1991;26:47-51.

Bulmer JN, Sunderland CA. Immunohistochemical characterization of lymphoid cell populations in the early human placental bed. Immunology 1984; 52: 349-57.

Burrows TD, King A, Loke YW. Expression of adhesion molecules by endovascular trophoblast and decidual endothelial cells: Implications for vascular invasion during implantation. Placenta. 1994;15: 21-33.

Caro CG, Fitz-Gerald JM, Schroter RC. Atheroma and arterial wall shear: Observation, correlation and proposal of a shear dependent mass transfer mechanisms for atherogenesis. Proc R Soc London (Biol). 1971;177:109-59.

Carpenter SJ. Trophoblast invasion and alteration of mesometrial arteries in the pregnant hamster: Light and electron microscopic observations. Placenta 1982;3:219-242.

Chaouat G, Menu E, Clark DA, Dy M, Minkowski M, Wegmann TG. Control of fetal survival in CBA x DBA/2 mice by lymphokine therapy. J Reprod Fert. 1990;89:447-58.

Chesley LC. Epidemiology of preeclampsia-eclampsia. In: Hypertensive disorders in pregnancy. Chesley LC (ed.) New Tork, Appleton-Century Crofts. 1978. p38-40.

Chin YH, Sackstein R, Cai JP. Lymphocyte-homing receptors and preferential migration pathways. Proc Soc Exp Biol Med. 1991;196: 374-480.

Croy BA, Kiso Y. Granulated metrial gland cells: a natural killer cell subset of the pregnant murine uterus. Microsc Res Tech. 1993;25:189-200.

Daiter E, Pampfer S, Yeung YG, Barad D, Stanley ER, Pollard JW. CSF-1 in the human uterus and placenta. J Clin Endocrinol Metabol. 1992;74:850-8.

Daiter E, Pollard JW. Colony stimulating factor-1 (CSF-1) in pregnancy. Reprod Med Rev. 1992;1:83-97.

Damsky CH, Fitzgerald ML, Fisher SJ. Distribution patterns of extracellular matrix components and adhesion receptors are intricately modulated during first trimester

cytotrophoblast differentiation along the invasive pathway, *in vivo*. J Clin Invest. 1992;89:210-22.

Damsky CH, Librach C, Lim KH, Fitzgerald ML, Mcmaster MT, Janatpour M, Zhou Y, Logan SK, Fisher SJ. Integrin swithcing regulates normal trophoblast invasion. Development. 1994;120:3657-66.

Datta R, Imamura K, Goldman SJ, Dianoux AC, Kufe DW, Sherman ML. Functional expression of the macrophage colony-stimulating factor receptors in human THP-1 monocytic leukemia cells. Blood. 1992;79:904-12.

De Bruyn PPH, Cho Y. Structure and function of high endothelial postcapillary venules in lymphocyte circulation. In:Current topics in pathology. 84/1. p.85-101.

De Wolf F, De Wolf-Peeters C, Brosens I, Robertson WB. The human placental bed: electronmicroscopic study of trophoblastic invasion of spiral arteries. Am J Obstet Gynecol. 1980;137:58-70.

Drake BL, Head JR. GM-CSF and CSF-1 stimulate DNA synthesis but not cell proliferation in short-term cultures of mid-gestation murine trophoblast. J Reprod Immunol. 1994;26:41-56.

Duval M. Le placenta des rongeurs. III. Le placenta de la souris et du rat. J Anat. Physiol. (Paris) 1891;27:515-612.

Enders AC, King BF. Early stages of trophoblastic invasion of the maternal vascular system during implantation in the Macaque and Baboon. Am J Anat. 1991;192:329-46.

Eriksson UJ. Diabetes in pregnancy: retarded fetal growth, congenital malformations and feto-maternal concentrations of zinc, copper and manganese in the rat. J Nutr. 1984;114:477-84.

Eriksson UJ, Jansson L. Diabetes in pregnancy: decreased placental blood flow and disturbed fetal development in the rat. Pediatr Res. 1984;18:735-8.

Facts on Infant Mortality in *Death Before Life: The Tragedy of Infant Mortality*. The report of the national commission to prevent infant mortality. Senator Lawton Chiles, Chairman. Washington, DC, August 1988.

Ferry BL, Sargent LL, Starkey PM, Redman CWG. Cytotoxic activity against trophoblast and choriocarcinoma cells of large granular lymphocytes from human early pregnancy decidua. Cellular Immunol. 1991;132:140-9.

Fox H. The villous cytotrophoblast as an index of placental ischemia. J Obstet Gynaecol Br Cmwlth. 1964;71:885-93.

Fox H. Effect of hypoxia on trophoblast in organ culture. Am J Obstet Gynecol. 1970;107:1058-64.

Fox H. Pathology of placenta. W.B. Saunders, Philadelphia. 1978.

Friedman MH, Bargeron CB, Mark FF. Variability of genometry, hemodynamics and intimal response of human arteries. Monogr Atherocsler. 1990;15:109-16.

Friedman MH, Deters OJ, Mark FF, Bargeron CB, Hutchins GM. Geometric effects on the hemodynamic environment of the arterial wall: A basis for geometic risk factors? In: Fluid dynamics as a localizing factor for atherosclerosis. Schettler G, Nerem RM, Schmid-Sconbein H, Mori H, Dieh, C (ed). Springer-Verlag, Berlin, Germany. 1983. p.71-8.

Fuller EG, Highison GJ, Tibbitts FD, Fuller BD. Migration of intravascular trophoblast cells in uterine arteries of the Golden hamster: A scanning electron microscopic study. J Morphol. 1994;220:307-13.

Gendron RL, Farookhi R, Baines MG. Resorption of CBA/J x DBA/2 mouse conceptuses in CBA/J uteri correlates with failure of the feto-maternal unit to suppress natural killer cell activity. J Reprod Fertil. 1990;89:277-84.

Gerretsen G, Huisjes HJ, Elema JD. Morphological changes of the spiral arteries in the placental bed in relation to pre-eclampsia and fetal growth retardation. Br J Obstet Gynaecol. 1981;88:876-81.

Gerretsen G, Huisjes HJ, Hardonk MJ, Elema JD. Trophoblast alterations in the placental bed in relation to physiological changes in spiral arteries. Br J Obstet Gynaecol. 1983;90:34-9.

Ginsburg H, Coleman R, Davidson S, Khoury C, Mor R. Lymphokine activated killer (LAK) cells are identical to the uterine granulated metrial gland (GMG) cells. Transplant Proc. 1989;21:186-9.

Goldman RD, Knipe DM. Functions of cytoplasmic fibers in non-muscle cell motility. Cold Spring Harbor Symp Quant Biol. 1973;37:523-34.

Graham CH, Lala PK. Mechanisms of placental invasion of the uterus and their control. Biochem Cell Biol. 1992;70:867-74.

Greenhill NS, Stehbens WE. Haemodynamically induced intimal tears in U-shaped arteial loops as seen by scanning electron-microscopy. Br J Exp Pathol. 1985;66:577-84.

Hamilton WJ, Boyd JD. Development of the human placenta in the first three months of gestation. J Anat. 1960;94:297.

Hamilton WJ, Boyd JD. Trophoblast in human utero-placental arteries. Nature. 1966;212:906-9.

Harning R; Myers C; Merluzzi VJ. Monoclonal antibodies to lymphocyte function-associated antigen-1 inhibit invasion of human lymphoma and metastasis of murine lymphoma. Clin Exp Metastasis. 1993;11: 337-42.

Harris JWS, Ramsey EM. The morphology of human uteroplacental vasculature. Contrib Embryol Carneg Instn. 1966;38:43-58.

Hertig AT. Vascular pathology in the hypertensive albuminuric toxemias of pregnancy. Clinic. 1945;4:602-14.

Holmes RP, Davies DV. The vascular pattern of the placenta and its development in the rats. J Obstet Gyn Br Empire. 1948;55:583-607.

Hunt JS, Hsi B. Evasive strategies of trophoblast cells: selective expression of membrane antigens. Am J Reprod Immunol. 1990;23:57-63.

Hustin J, Foidart JM, Lambotte R. Maternal vascular lesions in pre-eclampsia and intrauterine growth retardation. Light microscopy and immunofluorescence. Placenta. 1983;4:489-98.

Ishikawa T, Imura A, Tanaka K, Shirane H, Okuma M, Uchiyama T. E-selectin and vascular cell adhesion molecule-1 mediate adult T-cell leukemia cell adhesion to endothelial cells. Blood. 1993;82(5): 1590-8.

Isobe M, Yagita H, Okumura K, Ihara A. Specific acceptance of cardiac allograft after treatment with antibodies to ICAM-1 and LFA-1. Science. 1992;255: 1125-7.

Jackson AM, Alexandrov AB, Gribben SC, Esuvamathan K, James K. Expression and shedding of ICAM-1 in bladder cancer and its immunotherapy. Int J Cancer. 1993;55(6): 921-5.

Jokhi PP, Chumbley G, King A, Gardner L, Loke YW. Expression of the colony stimulating factor-1 receptor (c-fms product) by cells at the human uteroplacental interface. Lab Invest. 1993;68:308-20.

Kabawat SE, Mostaufui-Zedeh M, Driscoll SG, Bhan AK. Implantation site in normal pregnancy: A study with monoclonal antibodies. Am J Pathol. 1985;118: 76-84.

Kauma SW. Interleukin-1 beta stimulates colony-stimulating factor-1 production in human term placenta. J Clin Endocrinol Metab. 1993;76:701-3.

Keith Jr. JC, Endo Y, Warwick K, Keith KE, Brugh S, Rowles TK. Ridogrel improves maternal / fetal homeostasis in an ovine model of pregnancy-induced hypertension. Prostaglandins. 1994;47:247-53.

Keith JC, Rowles TK, Dilorenzo K, Mishra S, Misra HP. Letter. J Perinatology. 1993;5:417-8.

Keith, Jr, JC, Thatcher CD, Schaub RG. Beneficial effects of U-63,557A, a thromboxane synthetase inhibitor, in an ovine model of pregnancy-induced hypertension. Am J Obstet Gynecol 1987; 157:199-203.

Khong TY, Pearce JM, Robertson WB. Acute atherosis in preeclampsia: Maternal determinants and fetal outcome in the presence of the lesion. Am J Obstet Gynecol. 1987;157:360-3.

King A, Balendran N, Wooding P, Carter NP, Loke YW. Phenotypic and morphologic characterization of novel $CD3^-$, $CD56^{bright}$ + lymphocytes in the pregnant human uterus. Dev Immunol 1991;1:169-190.

King A Loke YW. Differential expression of blood-group related carbohydrate antigens by trophoblast subpopulations. Placenta 1988;9:513-21.

King A, Loke YW. Human trophoblast and JEG choriocarcinoma cells are sensitive to lysis by IL-2 stimulated decidual NK cells. Cellular Immunol. 1990;129:435-48.

King A, Loke YW. Human uterine large granular lymphocytes: what are they and what is their function? Immunol Today. 1991;12:432-5.

Khong TY, De Wolf F, Robertson WB, Brosens I. Inadequate maternal vascular response to placentation in pregnancies complicated by pre-eclampsia and by small-for-gestational-age infants. Br J OBstet Gynaecol. 1986;93:1049-59.

Khong TY, Sawyer IH, Heryet AR. An immunohistologic study of endothelialization of uteroplacental vessels in human pregnancy - Evidence that endothelium is focally disrupted by trophoblast in preeclampsia. 1992;167:751-6.

Kitzmiller JL, Benirschke K. Immunofluorescence study of placental bed vessels in preeclampsia. Am J Obstet Gynecol. 1973;115:248-51.

Kitzmiller JL, Watt N, Driscoll SG. Decidual arteriopathy in hypertension and diabetes in pregnancy: Immunofluorescent studies. Am J Obstet Gynecol. 1981;141:773-9.

Kliman HJ, Nestler JE, Sermasi E, Sanger JM, Strauss JF. Purification, characterization, and *in vitro* differentiation of cytotrophoblast cells from human term placentas. Endocrinol. 1986;1118:1567-82.

Labarrere C, Alonso J, Manni J, Domenichini E, Althabe O. Immunohistochemical findings in acute atherosis associated with intrauterine growth retardation. Am J Reprod Immunol Microbiol. 1985;7:149-55.

Lanier LL, Le AM, Civin CI, Loken MR, Philips JH. The relationship of CD16 (Leu11) and Leu-19 (NKH-1) antigen expression on human peripheral blood NK cells and cytotoxic T lymphocytes. J Immunol 1986;136: 4480-6.

Legrand C, Hernadez-Verdun D. Donnees autoradiographiques sur la differenciation du trophoblaste, apres transplantation intra-testicular d'embryons, chez le hamster dore. Cytobiologie. 1974;8:457-67.

Librach CL, Werb Z, Fitzgerald ML, Chiu K, Corwin NM, Esteves RA, Grobelny D, Galardy R, Damsky CH, Fisher SJ. 92-kD type IV collagenase mediates invasion of human cytotrophoblasts. J Cell Biol. 1991;113:437-49.

Linnemeyer PA, Pollack SB. Murine granulated metrial gland cells at uterine implantation sites are natural killer lineage cells. J Immunol. 1991;147:2530-5.

Lipski KM, McQuiggan JD, Loucy KJ, Fondy TP. Cytochalasin B: Preparation, analysis in tissue extracts, and pharmacokinetics after intraperitoneal bolus administration in mice. Analytical Biochemistry. 1987;161: 332-40.

Lunell NO, Nyluna LE, Lewander R, Sarby B. Uteroplacental blood flow in preeclampsia: measurements with Indium-113M and a computer-linked gamma camera. Clin Exp Hpertens. 1982;1:105-17.

Mabie WC, Pernoll ML, Biswas MK. Chronic hypertension in pregnancy. Obstet Gynecol. 1986;67:197-205.

Mackie EJ, Scott-burden T, Hahn AW, Kern F, Bernhardt J, Regenass S. Expression of tenascin by vascular smooth muscle cells. Alterations in hypertensive rats and stimulation by angiotensin II. Am J Pathol. 1992;141:377-88.

MacLennon AH, Sharp F, Shaw-Dunn J. The ultrastructure of human trophoblast in spontaneous and induced hypoxia using a system of organ culture: a comparison with ultrastructural changes in pre-eclampsia and placental insufficiency. J Obstet Gynaecol Br Cmwlth. 1972;79:113-21.

Mantovani A, Sica A, Colotta F, Dejana E. The role of cytokines as communication signals between leukocytes and endothelial cells. Prog Clin Biol Res. 1990;349:343-53.

Maqueo M, Azuela CJ, de la Vega MD. Placental pathology in eclampsia and preeclampsia. Obstet Gynecol. 1964;24:350-6.

Marais WD. Human decidual spiral arterial studies. Part II. A universal thesis on the pathogenesis of intraplacental fibrin deposits, layered thrombosis, red and white infarcts and toxic and non-toxic abruptio placentae. A microscopic study. J Obstet Gynaecol Br Commomwealth. 1962;69:213-24.

Marais WD. Human decidual spiral arterial studies. Part III. Histological patterns and some clinical implications of decidual spiral arteriosclerosis. J Ostet Gynaecol Br Comm. 1962;69:225-33.

McCarron RM, Wang L, Siren AL, Spatz M, Hallenbeck JM. Adhesion molecules on normotensive and hypertensive rat brain endothelial cells. P. S. E. B. M. 1994;205:257-62.

McFadyen IR, Price AB, Geirsson RT. The relation of birth weight to histological appearances in vessels of the placental bed. Br J Obstet Gynaecol. 1986;93:476-81.

Meekins JW, Pijnenborg R, Hanssens M, McFayden IR, Van Asshe A. A study of placental bed spiral arteries and trophoblast invasion in normal and severe pre-eclamptic pregnancies. Br J Obstet Gynaecol. 1994;101:669-74.

Michel M, Underwood J, Clark DA, Mowbray JF, Beard RW. Histologic and immunologic study of uterine biopsy tissue of women with incipient abortion. Am J Obstet Gynecol. 1989;161:409-14.

Mitchell MD, Trautman MS, Duddley DJ. Cytokine networking in the placenta. Placenta. 1993;14:249-75.

Moll W, Kunzel W, Herberger J. Hemodynamic implications of hemochorial placentation. Eur J Gynaecol Reprod Biol. 1975;5:67-74.

Mossman HW. Comparative morphogenesis of the foetal membranes and accessory uterine structures. Contrib Embriol Carneg Instn. 1937;26: 129-246.

Mosmann TJ. Rapid colorimetric assay for cellular growth and survival: application to proliferation and cytotoxicity assays. Immunol Methods. 1983;65:55-63.

Mulvany MJ, Hansen PK, Aalkjaer C. Direct evidence that the greater contractility of resistance vessels in spontaneously hypertensive rats is associated with a narrowed lumen, a thickened media, and an increased number of smooth muscle cell layers. Cir Res. 1978;43:854.

Olofssen P, Laurini RN, Marsal K. A high uterine artery pulsatility index reflects a defective development of placental bed spiral arteries in pregnancies complicated by hypertension and fetal growth retardation. Eur J Obstet Gynecol Reprod Biol. 1993;49:161-8.

Orsini MW. The trophoblastic giant cells and endovascular cell associated with pregnancy in the hamster *Cricetus auratus*. Am J Anat. 1954:94:272-331.

Paget S. Lancet. 1889;1:571-573 (reviewed by Schirrmacher V. Cancer metastasis: Experimental approaches, theoretical concepts, and impacts for treatment strategy. Adv Cancer Research. 1985;43:1-69.

Pampfer S, Daiter E, Barad D, Pollard JW. Expression of colony stimulating factor-1 receptor (the *c-fms* proto-oncogene product) in the human uterus and placenta. Biol Reprod. 1992;46:48-57.

Pauli BU, Lee CL. Organ preference of metastasis: the role of organ-specifically modulated endothelial cells. Lab Invest. 1988;58:379-87.

Peel S. Granulated metrial gland cells. Adv Anat Embryol Cell Biol. 1989;115:1-112.

Picker LJ, Butcher EC. Physiological and molecular mechanisms of lymphocyte homing. Ann Rev Immunol. 1992;10:561-91.

Pijnenborg R. Ph. D. thesis: Placentation in the golden hamster (*Mesocricetus auratus* waterhouse). 1975.

Pijnenborg R. Uteroplacental ischemia and hypertensive disorders of pregnancy. Issues in Nephrosciences 1.91. Milano, Italy. Wichtig Editore. 1991. p8-13.

Pijnenborg R, Anthony J, Davey DA, Rees A, Tiltman A, Verscuysse L, Van Assche A. Placental bed spiral arteries in the hypertensive disorders of pregnancy. Br J Obstet Gynaecol. 1991;98:648-55.

Pijnenborg R, Bland JM, Robertson WB, Dixon G, Brosens I. The pattern of interstitial trophoblastic invasion of the myometrium in early human pregnancy. Placenta. 1981;2:303-16.

Pijnenborg R, Bland JM, Robertson WB, Brosens I. Uteroplacental arterial changes related to interstitial trophoblast migration in early human pregnancy. Placenta. 1983;4:397-414.

Pijnenborg R, Dixon G, Robertson WB, Brosens I. Trophoblastic invasion of human decidua from 8 to 18 weeks of pregnancy. Placenta. 1980;1:3-19.

Pijnenborg R, Robertson WB, Brosens I. The arterial migration of trophoblast in the uterus of the golden hamster, *Mesocricetus auratus*. J Reprod Fertil. 1974;40:269-80.

Pijnenborg R, Robertson wB, Brosens I, Dixon G. Review article: Trophoblast invasion and the establishment of hemochorial placentation in man and laboratory animals. Placenta. 1981;2:71-92.

Pollard JW, Bartocci A, Arceci R, Orlofsky A, Ladner MB, Stanley ER. Apparent role of the macrophage growth factor CSF-1 in placental development. Nature. 1987;330:484-6.

Pollard JW, Hunt JS, Wiktor-Jedrzejczak W, Stanley ER. A pregnancy defect in the osteopetrotic (op/op) mouse demonstrates the requirement for CSF-1 in female fertility. Dev Biol. 1991;148:273-83.

Praloran V, Coupey L, Donnard M, Berrada L, Naud MF. Elevation of serum M-CSF concentrations during pregnancy and ovarian hyperstimulation. Br J Hematol. 1994;86:675-7.

Prewitt RL, Hashimoto H, Stacy DL. Structural and functional rarefaction of microvessels in hypertension. In: Blood vessel changes in hypertension: structure and fucntion. Volume 2. Lee RMKW (ed). CRC Press, Boca Raton, Florida. 1988. p.71-89.

Ramon de Alvarez R. *Current Obstetric and Gynecologic Diagnostics and Treatment, 5th. edition.* Lange medical publications, Los Altos, California, 1984, p. 763.

Ramsey EM, Harris WS. Comparison of uteroplacental vasculature and circulation in the rhesus monkey and man. Cont Embryo. 1966;261:61-70.

Ramsey EM, Houston ML, Harris JWS. Interactions of the trophoblast and maternal tissues in three closely related primate species. Am J Obstet Gynecol. 1976;124:646-52.

Redline RW, Lu CY. Specific defects in the anti-listerial immune response in discrete regions of the murine uterus and placenta account for susceptibility to infection. J Immunol. 1988;140:3947-55.

Redman CWG. The definition of pre-eclampsia. In: Hypertension in pregnancy. Sharp F, Symonds EM (ed). Ithaca, Perinatology Press. 1986. p.3-13.

Rey E, Couturier A. The prognosis of pregnancy in women with chronic hypertension. Am J Obstet Gnecol. 1994;171:410-6.

Roberts JM, Redman CWG. Pre-eclampsia: more than pregnancy-induced hypertension. Lancet. 1993;341:1447-51.

Roberts JM. Pregnancy related hypertension. *In* Maternal Fetal Medicine, Creasy RK, Resnik R (eds) Philadelphia, WB Saunders, 1989.

Robertson WB. Uterine vascular pathology in hypertensive pregnancy. In: Human placentation. Brosens I, Dixon G, Robertson WB (ed). Excerpta Medica. Amsterdam. 1975. p.64-5.

Robertson WB, Brosens I, Dixon HG. The pathological response of the vessels of the placental bed to hypertensive pregnancy. Obstet Gynecol. 1964;24:350-6.

Robertson WB, Brosens I, Dixon HG. The pathological response of the vessels of the placental bed to hypertensive pregnancy. J Path Bact. 1967;93:581-92.

Robertson WB, Brosens I, Dixon G. Uteroplacental vascular pathology. Eur J Obstet Gynecol Reprod Biol. 1975;5:47-65.

Robertson WB, Brosens I, Dixon G. Maternal uterine vascular lesions in the hypertensive complications of pregnancy. In: hypertension in pregnancy. Lindheimer MD, Katz AI, Zuspan FP (eds). New York, John Wiley and Sons. 1976. p.115-27.

Robertson WB, Khong TY, Brosens I, De Wolf F, Sheppard BL, Bonnar J. The placental bed biopsy: Review from the European centers. Am J Obstet Gynecol. 1986;155:401-12.

Robertson WB, Khong TY. Pathology of the uteroplacental bed. In: Hypertension in pregnancy. Sharp F, Symonds EM (ed). Perinatology Press. New York. 1986. p. 101-13.

Robertson WB, Warner B. The ultrastructure of the human placental bed. J Pathol. 1974;112:203-11.

Rodgers GM, Taylor RN, Roberts JM. Preeclampsia is associated with a serum factor cytotoxic to human endothelial cells. Am J Obstet Gynecol. 1988;159:908-14.

Rosen P, Schwippert B, Tschope D. Adhesive proteins in platelet-endothelial interactions. Eur J Clin Invst. 1994;1:21-4.

Roth T, Podesta F, Stepp MA, Boeri D, Lorenzi M. Integrin overexpression induced by high glucose and by human diabetes: potential pathway to cell dysfunction in diabetic microangiopathy. Proc Natl Acad Sci USA. 1993;90:9640-4.

Saito S, Ibaraki T, Enomoto M, Ichijo M, Motoyoshi K. Macrophage colony-stimulating factor induces the growth and differentiation of normal pregnancy human cytotrophhoblast cells and hydatidiform moles but does not induce the growth and differentiation of choriocarcinoma cells. Jpn J Cancer Res. 1994;85:245-52.

Saito S, Motoyoshi K, Ichijo M, Saito M, Takaku E. High serum human macrophage colony-stimulating factor level during pregnancy. Int J Hematol. 1992;55:219-25.

Saito S, Motoyoshi K, Saito M, Kato Y, Enomoto M, Nishikawa K, Morii T, Ichijo M. Localization and production of human macrophage colony-stimulating factor (hM-CSF) in human placental and decidual tissues. Lymphokine Cytokine Res. 1993;12:101-7.

Sank A, Wei D, Reid J, Ertl D, Nimni M, Weaver F, Yellin A, Tuan TL. Human endothelial cells are defective in diabetic vascular disease. J Surg Res 1994;57:647-53.

Seligman SP, Buyon JP, Clancy RM, Young BK, Abramson SB. The role of nitric oxide in the pathogenesis of preeclampsia. Am J Obstet Gynecol. 1994;171:944-8.

Sexton LI, Hertig AT, Reid DE, Kellogg FS, Patterson WS. Premature separation of the normally implanted placenta. Am J Obstet Gynecol. 1950;59:13-24.

Sheppard BL, Bonnar J. An ultrastructural study of uteroplacental spiral arteries in hypertensive and normotensive pregnancy and fetal growth retardation. Br J Obstet Gynaecol. 1981;88:695-705.

Shimizu Y, Newman W, Tanaka Y, Shaw S. Lymphocyte interactions with endothelial cells. Immunol Today. 1992;13:106-12.

Spargo B, McCartney CP, Winemiller R. Glomerular capillary endotheliosis in toxemia of pregnancy. Arch Pathol. 1959;68:593-9.

Spooner BS, Yamada KM, Wessels NK. Microfilaments and cell locomotion. J Cell Biol. 1971;49:595-613.

Springer TA. Adhesion receptors of the immune system. Nature. 1990;346:425-34.

Stewart IJ. Granulated metrial gland cells: pregnancy specific leukocytes? J Leuk Biol. 1991;50:198-207.

Stewart IJ. Granulated metrial gland cells - not part of the natural killer cell lineage? J Reprod Immunol. 1994;26:1-15.

Stanley ER, Guilbert LJ, Tushinski RJ, Baltelmez SH. CSF-1: A mononuclear phagocyte lineage-specific hemopoietic growth factor. J Cell Biochem. 1983;21:151-9.

Suzuki H, Schmid-Schonbein GW, Suematsu M, DeLano FA, Forrest MJ, Miyasaki M, Zweifach BW. Impaired leukocyte-endothelial cell interaction in spontaneously hypertensive rats. Hypertension 1994;24:719-27.

Tartakovsky B. CSF-1 induces resorption of embryos in mice. Immunol Letters. 1989;23:65-70.

Tartakovsky B, Goldstain O, Brosh N. Colony-stimulating factor-1 blocks early pregnancy in mice. Biol Reprod. 1991;44:906-12.

Thorbet A, Alm P, Bjorklund AB, Owman C, Sjoberg NO. Adrenergic innervation of the human uterus. Disappearance of the transmitter and transmitter-forming enzymes during pregnancy. Am J Obstet Gynecol. 1979;135:223-6.

Walsh SW. Preeclampsia: an imbalance in placental prostacyclin and thromboxane production. Am J Obstet Gynecol. 1985;152:335-40.

Walters WA. Effects of sustained maternal hypertension on fetal growth and survivial. Lancet. 1966:2:1214-7.

Watanabe N, Tsukada N, Smith CR, Phillips MJ. Motility of bile canaliculi in the living animal: implications for bile flow. J Cell Biol. 1991 Jun; 113(5): 1069-80.

Wegmann TG, Athanassakis L, Gilbert L, Branch D, Dy M, Menu E, Chaouat G. The role of M-CSF and GM-CSF in fostering placental growth, fetal growth survival. Trans Proc. 1989;21:566-8.

Weiss L. *In: Current Concepts in Cancer.* Rubin P [ed]. Pergamon, Oxford. 1975. pp.97-9.

Wesolowski SA, Fries CC, Sabini AM, Sawyer PN. Turbulence, intimal injury, and atherosclerosis. In Sawyer PN (ed): Biophysical mechanisms in vascular homeostasis and intravascular thrombosis. New York, Appleton-Century-Crofts. 1965. p147-57.

Wynn RM. Cytotrophoblastic specializations. An ultrastructural study of the human placenta. Am J Obstet Gynecol. 1972;114:339-55.

Wynn RM, Panigel M, MacLennan AH. Fine structure of the placenta and fetal membranes of the baboon. Am J Obstet Gynecol. 1971;109:638-48.

Yednock T, Cannon C, Fritz LC, Sanchez-Madrid F, Steinman L, Karin N. Prevention of experimental autoimmune encephalomyelitis by antibodies against a4b1 integrin. Nature. 1992;356:63-6.

Yong K, Salooja N, Donahue RE, Hegde U, Linch D. Human macrophage colony-stimulating levels are elevated in pregnancy and in immune thrombocytopenia. Blood 1992;80:2897-902.

Young A. The vascular architecture of the rat uterus. Trans Roy Soc Edinburgh. 1952. Sect B. 64;292-311.

Young A. The vascular architecture of the rat uterus during pregnancy. Trans Roy Soc Edinburgh. 1956;63:167-83.

Zeeman GG, Dekker GA. Pathogenesis of preeclampsia: a hypothesis. Clin. Obset Gynecol. 1992;35:317-37.

Zimmerman GA, Prescott SM, McIntyre TM. Endothelial cell interactions with granulocytes: tethering and signaling molecules. Immunol Today. 1992;13:93-100.

Zhou Y, Damsky CH, Chiu K, Roberts JM, Fisher SJ. Preeclampsia is associated with abnormal expression of adhesion molecules by invasive cytotrophoblasts. J Clin Invest. 1993;91: 950-60.

Zhu D, Cheng CF, Pauli. Blocking of lung endothelial cell adhesion molecule-1 (Lu-ECAM-1) inhibits murine melanoma lung metastasis. J Clin Invest. 1992;89(6): 1718-24.

Vita

Yasuhiro Endo was born to Ritsuko and Noboru Endo on December 24, 1963, in Sapporo, Japan. He entered a combined program of D.V.M. and M.S. at Rakuno Gakuen University and was awarded both degrees in 1989. He began his doctoral studies in the Department of Veterinary Medical Sciences at the Virginia-Maryland Regional College of Veterinary Medicine at Virginia Polytechnic Institute and State University in 1990, and worked with Dr. James C. Keith Jr. In 1993 May - 1994 April, he conducted his doctoral research in the Department of Obstetrics and Gynaecology at University of Leuven, Belgium with Dr. Pijnenborg as his supervisor. After having returned to Virginia, he completed his research under the direction of Dr. Ludeman A. Eng.

