OPEN Case Report

Distinguishing Pseudosubluxation From True Injury: A Case of C2-3 and C3-4 Subluxation in a Pediatric Patient

Conor O'Neill, MD
Alyssa Wenzel, BS
Zakk Walterscheid, MD
Jonathan Carmouche, MD

ABSTRACT

A 6-year-old girl presented with a one-week history of neck pain after a trampoline accident. Cervical radiographs interpreted as pseudosubluxation of C2 on C3. CT demonstrated the reversal of lordosis with anterolisthesis of C2-C3 and C3-C4. Ten weeks after two months of halo traction, radiographs demonstrated anatomic alignment and maintained disk heights. This case highlights the similarities of pseudosubluxation and true injury, emphasizing the need for high index of suspicion in this population and a successful treatment of subluxation using a halo construct.

From the Virginia Commonwealth University Department of Orthopaedics, Richmond, VA (Dr. O'Neill); Virginia Tech Carilion School of Medicine, Roanoke, VA (Ms. Wenzel and Dr. Carmouche); University of Washington Department of Orthopaedic and Sports Medicine, Seattle, WA (Dr. Walterscheid); and Carilion Clinic Department of Orthopaedics, Roanoke, VA (Dr. Carmouche).

Correspondence to Dr. Carmouche: JJCarmouche@carilionclinic.org

None of the following authors or any immediate family member has received anything of value from or has stock or stock options held in a commercial company or institution related directly or indirectly to the subject of this article: Dr. O'Neill, Ms. Wenzel, Dr. Walterscheid, and Dr. Carmouche.

JAAOS Glob Res Rev 2021;5: e20.00238

DOI: 10.5435/JAAOSGlobal-D-20-00238

The evaluation and management of pediatric cervical spine injuries is challenging. The unique biomechanics of the pediatric cervical spine result in upper cervical injuries in younger children and lower cervical injuries in older children. Ligamentous injuries are more common than fractures.[1] Diagnosis is further complicated by the high frequency of radiologically benign findings often mistaken for injuries such as pseudosubluxation and synchondroses.[1] Pediatric cervical spine injuries are often secondary to motor vehicle accidents or contact sport.[2-4] Trampolines commonly cause pediatric trauma, but rarely cervical spine injuries.[5]

The child's spine is more flexible than that of an adult.[1,6] The ability of the spinal ligaments and joint capsules to stretch without tearing contributes to pseudosubluxation. Younger than 8 years old, the prevalence of pseudosubluxation of at least 3 mm at C2-3 is 40% and up to 14% at C3-4.[7] Angulation greater than 7° or 3.5 mm of subluxation is considered a sign of ligamentous injury in children.[8,9] Cervical instability is diagnosed in a child younger than 8 years old if more than 4.5 mm of subluxation is present at C2–3 or C3–4.[7,10] Evaluating pediatric cervical spine injuries must combine thorough imaging, physical examination, and clinical suspicion.

Statement of Informed Consent

Consent was obtained by family for publication.

Figure 1

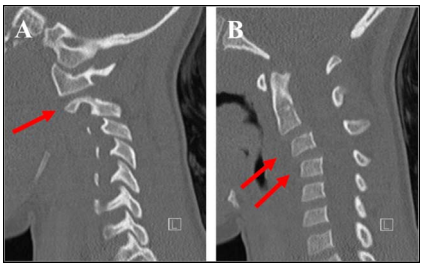

Radiographs showing sagittal CT images obtained supine. No fracture is seen. **A**, Subluxation of facet at C2-3. **B**, Anterolisthesis of C2 on C3 and C3 on C4.

Case Presentation

A 6-year-old healthy girl presented to the emergency room (ER) complaining of neck pain lasting 1 week after a trampoline accident. Cervical spine radiographs and CT scan taken the day after the incident at an outside facility demonstrated soft-tissue swelling without fracture. She described a stabbing midline neck pain with difficulty looking up and no neurologic symptoms. She denied difficulty with balance, weakness, or loss of coordination. No personal or family history of spine problems existed.

Examination revealed a healthy young girl in obvious discomfort. Her posture was balanced with a stable gait. Her neck was tender in the midline, with no masses or adenopathy. Her neck range of motion was restricted in extension. Motor function was intact throughout the upper and lower extremities. She had no sensory or proprioceptive deficits and normal reflexes. She had no clonus, a negative Babinski, and a negative Hoffman.

Radiographs of the cervical spine demonstrated anterolisthesis at C2-3 with normal segmentation. Her cervical spine CT demonstrated 30° kyphosis measured C2-4 with anterolisthesis at C2-3 measuring 4.9 mm and anterolisthesis of 4.1 mm at C3-4 (Figure 1, A and B). Prevertebral swelling was noted as was interspinous widening at C2-3.

An MRI demonstrated high interspinous T2 signal, suggesting ligamentous injury at C2-3 and C3-4. A fluid collection consistent with hematoma was noted anteriorly (Figure 2, A–C). She was placed in a cervical collar, and the risks and benefits of treatment options including observation, rigid collar, noninvasive halo, traditional halo, and surgical posterior stabilization with instrumentation were discussed.

The next day, she underwent a closed reduction in the operating room with sedation using an eight-pin halo ring and application of halo vest. Pins were placed in the lateral 2/3 of the orbit, approximately 1 cm above the supraorbital ridge and 1 cm off the ears on both sides. They were torqued to 1-inch pounds while maintaining counter torque. Fluoroscopic images confirmed correction of the deformity (Figure 3, A and B).

The patient was seen at 2 days, 2 weeks, 1 month, and 2 months. All pins were retorqued at the first appointment. Follow-up radiographs were obtained at each visit, demonstrating the maintenance of reduction at C2-3 and C3-4 (Figure 4, A and B, and Figures 5, A and B).

The halo was removed 10 weeks post-op. Radiographs demonstrated satisfactory alignment with maintained interspinous distances. The craniocervical junction was intact, and prevertebral edema had resolved. The patient was then placed in an Aspen collar, with follow-up visits at 2 weeks and then at 10 weeks. Radiographs at each visit confirmed no changes in her cervical spine. The Aspen collar was discontinued at the final appointment. No reported issues at the 2-year follow-up.

Discussion

Pseudosubluxation

Pseudosubluxation is commonly found in the pediatric population.[7,11] The high prevalence of pediatric pseudosubluxation complicates the evaluation of subaxial

Figure 2

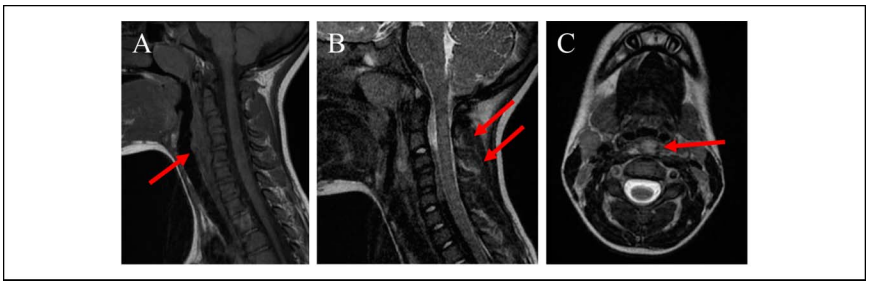

Preoperative MRI of the patient's C-spine. **A**, Sagittal T1 image with evident prevertebral swelling (arrow). **B**, Sagittal T2 image with interspinous hyperintensity at C2-3 and C3-4 (arrow). **C**, Axial T2 image with prevertebral swelling (arrow).

Figure 3

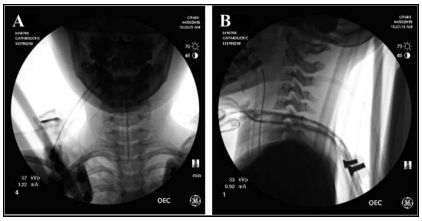

Intraoperative fluoroscopy (**A**) AP and (**B**) lateral. No coronal plane deformity present.

Figure 4

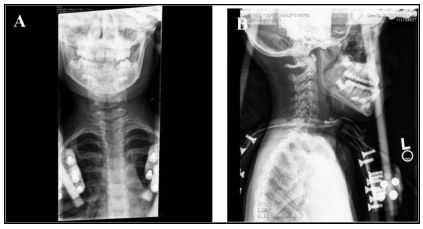

Two days postoperative radiographs of (**A**) AP and (**B**) lateral.

cervical injuries. Subaxial cervical spine injuries mainly occur after maturation of the cervical spine in children older than the age of 8 and most often occur between C5 and C7,[12] so the presentation of a 6-year-old with a true ligamentous injury yielding subluxation at C2-3 and C3-4 is atypical. Immature bony development, physiological laxity of the ligaments, greater head size relative to the overall body, and underdevelopment of the musculature of the neck,[7,13-15] however, predispose younger children to cervical spinal injury. The younger the child, the higher the injury—usually dislocations rather than fractures.[16] The severity of subaxial injuries varies widely and must be approached with wide differential.[17] This case demonstrates the challenge of discerning when a radiological finding is a harmless physiological change or a serious but treatable clinical injury.

Imaging

The difficulty of identifying pediatric cervical spine injuries based on history and physical alone always necessitates imaging. Lateral and anterior-posterior radiographs are the standard first line.[18] Some researchers have argued that routine plain radiographs have a low yield for identifying pathology,[19] yet others have shown a high rate of delayed diagnosis when original assessment is based on history and physical alone.[20] A number of large studies have explored the use of further modalities, with no clear consensus. The National Pediatric Trauma Registry reports the largest series of pediatric cervical spine injuries, with more than 1,000 recorded cases over a 10-year time frame, finding that 50% of children with neurological symptoms were found to have negative radiographs.[16] When a subluxation is seen on a lateral radiograph of a pediatric cervical spine, the first step is determining whether it is physiological or a true injury. If the child lies on a solid surface, it causes flexion of the cervical spine and enhances the appearance of a pseudosubluxation. Repeating the radiograph with a child in a neutral head position should cause a pseudosubluxation to disappear, whereas a true subluxation will not.[21]

Some patients may need further imaging, either CT or MRI. When compared with CT scans, lateral radiographs have an acceptable sensitivity to cervical spine abnormalities in pediatric patients.[22] Given that ligamentous injury is more common in this population, CT is not warranted in the routine evaluation of children presenting with cervical spine injuries.[23] MRI, in contrast, is the preferred imaging in patients with a suspected cervical spine injury. MRI is far superior to CT for delineating both mild and severe soft-tissue anatomy and injury.[17] In one study, MRI confirmed the diagnosis of a cervical spine injury in 66% of children and in addition changed the diagnosis in 34% of children.[24] Overall, initial radiographs are widely accepted as the standard of care; for additional imaging, the literature seems to suggest that MRI is better than CT.

Mechanism of Injury

Determining the events leading to an injury can elucidate the type and location of an injury. Kokoska et al found that the two leading mechanisms of injury were motor vehicle accidents (44%) and sport (16%). They also found that young children sustained high cervical spine injuries (C1 to C4) more often and had a higher incidence of dislocations.[25] The children subjected to a low-speed front collision had more forward head excursion, more vertical head excursion, and slight spinal extension in

Figure 5

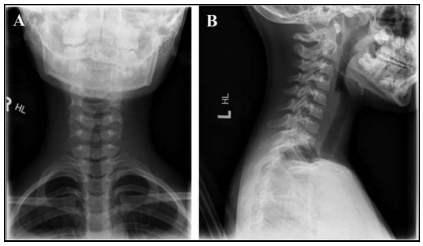

Cervical spine radiographs of (**A**) AP and (**B**) lateral from most recent appointment.

comparison to skeletally mature individuals.[26] These studies show that children have a higher risk of cervical spine injury, especially in the context of acceleration injuries and blunt trauma.

Trampolines have long been controversial in pediatrics. Despite the American Academy of Pediatrics cautioning about the regular and unmonitored use of trampolines with children, the number of injuries sustained because of trampolines over the years has increased.[27] Although falls from the trampoline are associated with fractures, falls on the body of the trampoline tend to be associated with dislocations and spinal injuries that can lead to serious neurological sequelae.[28] Thus, knowing the mechanism of injury can be an important piece of information when gathering the history and can help to increase a clinician's index of suspicion for cervical spine injuries.

Treatment

As with any injury suspicious of involving the cervical spine, early immobilization is key, especially in children, because their larger head size forces the neck into flexion. Most pediatric cervical spine injuries can be treated with hard collar immobilization.[1,29] In the cases of subaxial injuries, the use of anterior and posterior plating has increased.[17] However, a few studies that have investigated these techniques in children have found issues with the limitations caused by the small anatomy of children, creating very small margins of error when placing plates and screws.[17] Halo fixation is another treatment option that has been used in children, but without rigorous investigation. Traction is a powerful tool in restoring cervical alignment, but it is challenging in pediatrics. A child's much smaller body mass provides a lower amount of countertraction. In addition, immature musculature and physiological ligamentous laxity can lead to overdistraction.[17] Children are more susceptible to complications from the placement of the pins for the halo device, including higher risk of skull penetration, pin loosening, pin site infection, and supraorbital nerve injury.[1] Radiographs with every weight change are critical in halo fixation, to monitor the response and ensure no overdistraction. One pound of torque per cervical level in children younger than 4 years old and 2 pounds per level in children older than 4 years old seems to be sufficient for achieving adequate traction.[1] Overall, however, the literature suggests more research needs to be done in this area to find the optimal treatment that maximizes the benefit and minimizes the risk to these children because leaving them untreated can lead to serious neurologic sequelae.

Conclusion

Knowledge of the special anatomy and biomechanics of the pediatric spine is essential in diagnosis of pediatric cervical spine injuries, and special care must be taken in the diagnostic approach to a young child presenting with neck pain after traumatic injury. Understanding the mechanisms of injury and taking a thorough history with a complete neurological examination can help a clinician develop a high index of suspicion in these cases to ensure that these patients do not have a delay in diagnosis and treatment.

References

1. McCall T, Fassett D, Brockmeyer D: Cervical spine trauma in children: A review. *Neurosurg Focus* 2006;20:E5.

2. Rachesky I, Boyce WT, Duncan B, Bjelland J, Sibley B: Clinical prediction of cervical spine injuries in children. Radiographic abnormalities. *Am J Dis Child* 1987;141:199-201.

3. Brown RL, Brunn MA, Garcia VF: Cervical spine injuries in children: A review of 103 patients treated consecutively at a level 1 pediatric trauma center. *J Pediatr Surg* 2001;36:1107-1114.

4. Murphy RF, Davidson AR, Kelly DM, Warner WC Jr, Sawyer JR: Subaxial cervical spine injuries in children and adolescents. *J Pediatr Orthop* 2015;35:136-139.

5. Loder RT, Schultz W, Sabatino M: Fractures from trampolines: Results from a national database, 2002 to 2011. *J Pediatr Orthop* 2014;34: 683-690.

6. Easter JS, Barkin R, Rosen CL, Ban K: Cervical spine injuries in children, part I: Mechanism of injury, clinical presentation, and imaging. *J Emerg Med* 2011;41:142-150.

7. Cattell HS, Filtzer DL: Pseudosubluxation and other normal variations in the cervical spine in children. *J Bone Joint Surg Am* 1965;47:1295-1309.

8. White AA III, Panjabi MM: The basic kinematics of the human spine. A review of past and current knowledge. *Spine* 1978;3:12-20.

9. Ware ML, Gupta N, Sun PP, Brockmeyer DL: Clinical biomechanics of the pediatric craniocervical junction and subaxial spine, in: Brockmeyer DL, ed: *Advanced Pediatric Craniocervical Surgery*. New York, NY, Thieme, 2006, 27-42.

10. Pang D, Sun PP: Pediatric vertebral column and spinal cord injuries, in: Winn HR, ed: *Youmans Neurological Surgery, ed 5*. Philadelphia, PA, W.B. Saunders, 2004, 3515-3557.

11. Shaw M, Burnett H, Wilson A, Chan O: Pseudosubluxation of C2 on C3 in polytraumatized children—Prevalence and significance. *Clin Radiol* 1999;54:377-380.

12. Baumann F, Ernstberger T, Neumann C, et al: Pediatric cervical spine injuries: A rare but challenging entity. *J Spinal Disord Tech* 2015;28: E377-E384.

13. Swischuk LE: Anterior displacement of C2 in children: Physiologic or pathologic. *Radiology* 1977;122:759-763.

14. Cirak B, Ziegfeld S, Knight VM, Chang D, Avellino AM, Paidas CN: Spinal injuries in children. *J Pediatr Surg* 2004;39:607-612.

15. Kasai T, Ikata T, Katoh S, Miyake R, Tsubo M: Growth of the cervical spine with special reference to its lordosis and mobility. *Spine (Phila Pa 1976)* 1996;21:2067-2073.

16. Patel JC, Tepas JJ III, Mollitt DL, Pieper P: Pediatric cervical spine injuries: Defining the disease. *J Pediatr Surg* 2001;36:373-376.

17. Mortazavi M, Gore PA, Chang S, Tubbs RS, Theodore N: Pediatric cervical spine injuries: A comprehensive review. *Childs Nerv Syst* 2011;27: 705-717.

18. College of Surgeons Committee on Trauma: *Advanced trauma life support for doctors, ed 7*. Chicago, IL, American College of Surgeons, 2004.

19. Lally KP, Senac M, Hardin WD Jr, Haftel A, Kaehler M, Mahour GH: Utility of the cervical spine radiograph in pediatric trauma. *Am J Surg* 1989; 158:540-542.

20. Dietrich AM, Ginn-Pease ME, Bartkowski HM, King DR: Pediatric cervical spine fractures: Predominantly subtle presentation. *J Pediatr Surg* 1991;26:995-1000.

21. ATLS Subcommittee: ACS committee on trauma: Advanced trauma life support (ATLS): The ninth edition. *J Trauma Acute Care Surg* 2013;74: 1363-1366.

22. Silva CT, Doria AD, Traubici J, Moineddin R, Davila J, Shroff M: Do additional views improve the diagnostic performance of cervical spine radiography in pediatric trauma? *Am J Roentgenol* 2010;194:500-508.

23. Gopinathan NR, Viswanathan VK, Crawford AH: Cervical spine evaluation in pediatric trauma: A review and an update of current concepts. *Indian J Orthop* 2018;52:489-500.

24. Flynn JM, Closkey RF, Mahboubi S, Dormans JP: Role of magnetic resonance imaging in the assessment of pediatric cervical spine injuries. *J Pediatr Orthop* 2002;22:573-577.

25. Kokoska ER, Keller MS, Rallo MC, Weber TR: Characteristics of pediatric cervical spine injuries. *J Pediatr Surg* 2001;36:100-105.

26. Arbogast KB, Balasubramanian S, Seacrist T, et al: Comparison of kinematic responses of the head and spine for children and adults in low-speed frontal sled tests. *Stapp Car Crash J* 2009;53: 329-372.

27. Leonard H, Joffe AR: Children presenting to a Canadian hospital with trampoline-related cervical spine injuries. *Paediatr Child Health* 2009;14: 84-88.

28. Furnival RA, Street KA, Schunk JE: Too many pediatric trampoline injuries. *Pediatrics* 1999;103:e57.

29. Easter JS, Barkin R, Rosen CL, Ban K: Cervical spine injuries in children, part II: Management and special considerations. *J Emerg Med* 2011;41:252-256.