INTRODUCTION

The production of meat-type poultry has greatly expanded over the past several decades. The commercial broiler industry has evolved from backyard flocks into an ingenious mass food production system. Growth and yield of birds have been enhanced with the help of highly specialized diets and through the use of genetics. At the breeder level, superior birds are selected based on attributes desirable to the customer, while enhancing growth, reproductive rates, and an improved immune system of the bird. This ability to adapt the bird based on consumer preference while improving bird livability has allowed the industry to thrive and succeed.

The primary focus of the commercial broiler industry is to maximize profits by promoting maximal yield and maintaining the health of the bird. Any hindrance to bird health will decrease profitability. Improvements in technology relating to vaccines or nutrition could save companies money and allow the industry to operate more efficiently by increasing revenue and decreasing overall costs. One of the main expenses faced by the industry is loss associated with poultry diseases, including costs of vaccination, prevention, treatment, reduction in weight gains, and mortality.

Coccidiosis is a parasitic disease that is responsible for losses in production of food-producing animals worldwide. The incidence of coccidiosis in commercial poultry has increased due to higher stocking densities and more intensive husbandry practices. Stocking densities such as 0.7 ft^2 per bird, among other stressors, have favored the spread of this disease in commercial poultry facilities. It has been documented that coccidiosis is the most consistently reported health problem in poultry (Biggs, 1982; Rose et al., 1987; Williams, 1999).

Over the past 100 years, much research has persisted on coccidiosis because of its significance in the animal industry. Researchers interested in the *Eimeria* species continue to analyze the intricate details of its life cycle in hopes of alleviating the potential hazards and economic losses caused by this disease. The current methods for control of coccidiosis can be attributed to knowledge gained through past research and investigations. Much of the host-parasite interaction is unclear; however, ongoing and future information obtained will help with the treatment, prevention, and perhaps the eradication of this costly disease.

Our laboratory is particularly interested in the mechanisms responsible for mucosal immunity to coccidial parasites in broilers. Understanding these mechanisms has been complicated with the immunovariability associated with different isolates within the same *Eimeria* species. The purpose of the present study was to examine two different isolates of *Eimeria acervulina* and the pathology and immunovariability associated with both. *Eimeria acervulina* was chosen for the series of experiments because of its prevalence and continual occurrence in the commercial poultry industry. We hypothesized that immunovariability does exist between different strains within the same species of *Eimeria* and that there is a differential host response associated with each. In addition, mast cell numbers are increased during an *Eimeria* infection and exhibit effector functions, which mediate inflammatory responses and aid in intestinal immunity.

REVIEW OF LITERATURE

Eimeria

Coccidiosis is a self-limiting, infectious disease of the digestive tract caused by host-specific intracellular protozoal parasites of the genus *Eimeria*. Coccidia are classified under the subkingdom Protozoa of the phylum Apicomplexia (Jeurissen et al., 1996; Lillehoj, 1996). As a group, coccidia of the genus *Eimeria* cause the most widespread health problems in the broiler industry and remain one of the most expensive diseases of commercial poultry production (Edgar, 1992; Henken et al.,1994; Yun et al.,2000). Birds infected with coccidial oocysts do not perform as well as non-infected birds as a result of moderate to severe damage to the intestinal mucosa. Birds exhibit decreased weight gains, increased feed conversion, and in some cases, birds may appear asymptomatic, but are limited in their ability to maximize feed efficiency. According to Edgar (1992), it takes only one viable oocyst to establish the presence of coccidia in a poultry house. This is possible because of the parasite's reproduction index. Ingestion of one *Eimeria acervulina* (EA) oocyst in the infective state has the ability to yield about 72,000 oocysts in one complete life cycle (Henken, 1994).

The prevalence of coccidiosis is worldwide and can be found in almost every commercial poultry flock (McDougald and Reid, 1997; Cox, 1998). In poultry, there are seven species of *Eimeria* that infect chickens (Shirley, 1986; McDougald and Reid, 1997). All of the chicken coccidia are pathogenic; however, some species produce more severe effects than others, such as severe morbidity and mortality. These microscopic, one-celled parasites invade their host via the fecal-oral route, and immunity is achieved once the parasite completes its life cycle in the host (Brackett and Bliznick, 1950; McDougald and Reid, 1997). Chickens of all ages are susceptible to coccidiosis, but birds that are three to five weeks of age are the most vulnerable (Edgar, 1992; Yun 2000).

The *Eimeria* species have an extremely complex life cycle comprising stages both internal and external to the host. Infection occurs by ingesting sporulated coccidial oocysts found in contaminated litter, soil, feed or water. After ingestion, the protozoa go through a series of intracellular, extracellular, asexual, and sexual stages to produce viable oocysts that are excreted in the feces (Rose, 1987). After a brief period outside of the host, the oocysts become infective again through the process of sporulation, and the life cycle is complete.

The impacts of coccidiosis are significant; however, eradication is impractical due to protective mechanisms of the oocysts. *Eimeria* possess a thick outer wall that acts as a protective barrier, which enhances the chance of survival under severe conditions. The oocysts are able to remain infective outside of the host for long periods, and their protective properties allow them to be resistant to many harsh chemicals and disinfectants (Eschenbacher et al., 1996; Jeurissen, 1996; Yun et al., 2000).

Coccidian Life Cycle

As the *Eimeria* species tend to be very specific in the intestinal region at which they invade, their life cycles are similar with a degree of species specificity. The *Eimeria* complete their life cycle in three distinctive phases including sporogony, merogony, (schizogony) and gametogony; however, the lengths of these phases are unique to the species (Yun et al., 2000). The following life cycle is adapted from Edgar (1992). Coccidiosis, caused by the ingestion of microscopic oocysts, is easily transmissible by mechanical means such as contaminated footwear and equipment, or it can be found in litter, contaminated soil, feed, or water (Conaway and McKenzie, 1991; McDougald and Reid, 1997). Chickens can become infected by coccidia once the oocysts develop into an infective stage outside of the host. Sporogony is the process of a one-celled zygote within the oocyst undergoing a series of divisions to form sporozoites, which are contained within sporocysts. Only oocysts that have undergone this process are able to cause disease.

Sporulated oocysts contain four sporocysts, and each sporocyst contains two sporozoites. Mechanical action of the gizzard and pancreatic enzymes such as trypsin and bile salts cause the destruction of the oocysts' outer wall, which releases the sporocysts into the digestive tract. The sporocysts are then further excysed by trypsin and bile salts that are present in the intestine. The sporozoites invade villus epithelial cells along specific locations throughout the digestive tract depending on the species of *Eimeria*. Some species travel within the mucosa, through the lamina propria to the crypt epithelial cells. Once inside villus or crypt cells, the process of merogony takes place. The sporozoite develops into a rounded body called a trophozoite, and then into an asexually reproductive first-generation schizont (meront). The schizont grows and divides rapidly to produce many first-generation merozoites. The bodies rupture and release hundreds of first-generation merozoites, which

seek out and invade other epithelial cells. Second-generation trophozoites develop into second-generation schizonts. When the second-generation schizonts mature and rupture, increased quantities of invasive merozoites are released causing widespread infection. The number of asexual stages and time required for each depends on the *Eimeria* species involved; however, most species will have less than four asexual reproductive generations (Rose, 1987; Edgar, 1992).

Merozoites produced by the latter schizont generations develop into sexual forms called gametocytes, some male and some female. This phase of sexual reproduction is termed gametogony. The female gametocyte matures into a macrogamete and the male gametocyte matures and ruptures releasing a large number of motile, biflagellate microgametes. The microgametes penetrate the mature female macrogamete and fertilization occurs. Following fertilization, a thickened protective wall forms around the zygote. At this stage, the zygote is considered an immature oocyst. When mature, the oocysts rupture the host cell, enter the lumen, and are expelled into the feces. Clinical signs are associated with tissue destruction from the release of the merozoites and mature oocysts from the mucosal surface during the last generations of merogony and throughout gametogony. In severe infections, much of the mucosal epithelium is sloughed off and nutrient absorption is compromised (Jeurissen, 1996; McDougald and Reid, 1997; Yun, 2000).

Oocysts excreted from the birds remain in the environment and have the potential to infect other birds. Under favorable environmental conditions (approximately 84°F), sporulation of oocysts will be achieved in 24 to 48 hours, and the cycle will continue (Edgar, 1992; Graat et al., 1994; McDougald and Reid, 1997). According to Edgar (1992), once the oocyst is sporulated, it can remain infective to birds from several months to one or two years if protected from very hot, dry, or freezing conditions. Coccidial oocysts have rigid characteristics but are not totally indestructible. According to Lee (1988), unsporulated oocysts are more susceptible to physical and chemical agents than sporulated oocysts perhaps due to a highly sensitive metabolic state. Other factors, such as ammonia and anaerobic conditions, are also lethal to oocysts in the environment. Cessation of development occurs when oocysts are introduced to high levels of CO_2 or NH_4, or exposed to mercury salts, mercuric cyanide, and mercuric chloride due to the ability of these agents to penetrate the oocyst wall (Kheysin, 1972). The prepatent period, the time it takes for oocysts to be seen in

the feces after ingestion, is approximately 4 to 7 days for the *Eimeria* species (Henken et al., 1994; Jeurissen, 1996; McDougald and Reid, 1997).

Coccidiosis in Commercial Broiler Operations

Coccidiosis has plagued the poultry industry since the early 1900s, and by the 1940s, considerable information was gathered on the pathophysiology, immunology, epidemiology, and therapy of this disease. Large-scale production of poultry was developed, and with it came a need to study the control of threatening diseases (Brackett and Bliznick, 1950). Today, much knowledge has been gained about coccidiosis, but it continues to have a major economic impact on the commercial poultry industry. It has been reported that the US poultry industry suffers in excess of one to two billion dollars in annual losses relating to coccidial infection, treatment, and prevention (Danforth and Augustine, 1989; Talebi and Mulcahy, 1995; Yun et al., 2000). However, it is difficult to accurately estimate the total monetary losses suffered by the world's poultry industry resulting from coccidiosis and its prevention or control (Danforth, 1998; Williams, 1999), because coccidiosis infects any type of poultry in any type of facility and its occurrence is worldwide (McDougald and Reid, 1997).

Chicken coccidial species are highly species specific, and acquired immunity can be achieved once the coccidia complete their life cycle. However, birds can harbor the disease and be carriers after infection, increasing the likelihood of spreading coccidiosis (Lee and Shih, 1988; Williams, 1998). Most infections are mild due to the ingestion of few oocysts, and the disease will go unnoticed. With such infections, maximal feed efficiency and feed utilization by the bird is only slightly decreased. Ingestion of millions of oocysts, on the other hand, may cause severe infections, and a disastrous outbreak could occur.

Flocks infected as a result of mild to severe exposure usually show a marked decrease in food and water consumption, and birds become depressed and tend to huddle. Decreased weight gains occur as a result of the disruption of the intestinal mucosa where minimal absorption is taking place. Diarrhea may result as the host is trying to flush the organism from the body, which may induce dehydration. Lesions of the intestinal mucosa and loss of pigmentation may also become apparent during the latter stages of infection (Conaway and McKenzie, 1991; Edgar, 1992; Lillehoj and Trout, 1993; McDougald and Reid, 1997).

Mortality could result due to the lack of adequate nutrient intake, secondary infections, and other continual stressors associated with the diseased state. However, with the use of control agents such as medications, vaccines, or coccidiostats, the effects of coccidiosis are suppressed or even prevented.

Since the 1950s, the control of coccidiosis has been achieved through anticoccidial compounds administered in the feed, which prevent or reduce infections to a sub-clinical level (Danforth, 1998). When used correctly, these compounds provide sufficient disease control. However, current management practices, such as intensive confinement, encourage the severity and transmission of coccidiosis. With the use of continual feed application of anticoccidials, unavoidable drug resistance by avian coccidia has resulted. This has allowed for an increased selection of drug-resistant strains, which reduce the efficacy of many anticoccidials that are used today. To further control the emergence of drug-resistant strains, shuttle and rotation programs have been pursued. These strategies have given good results in the past but continued efficacy is questionable. To date, the most serious limitation to anticoccidial therapy is the parasite's increasing tolerance (McDougald and Reid, 1997).

New and innovative anticoccidial products are unlikely to be marketed due to the increased costs of approving such compounds for food animals and consumer perspectives concerning feed additives (Danforth, 1998; Vermeulen, 2001). With such constraints, producers and researchers have tried to identify drug-free alternatives to coccidiosis control such as improved sanitation upon complete litter cleanout, selective breeding for improved immunity, and vaccination programs (Williams, 1998). However, developments of new and improved vaccines in recent years seem to have the greatest potential. In order for a commercial vaccine to be successful, it must have a reasonable cost, be as effective as other methods, give solid protection within a short period of time, and offer long-lasting immunity (Danforth and Augustine, 1989). To date, there are four vaccines available for commercial chicken flocks but their use in broilers is relatively low due to the short grow out period (Williams, 1998).

The main objective of the broiler industry is to produce a high quality product at relatively low costs. Any extemporaneous costs related to treatment or prevention of enteric diseases increase production costs and lower profits. The drastic impacts on production caused by coccidiosis have significant economic effects at each facet of the industry. The

goal of researchers and scientists is to sequester the effects of this enteric disease, which will in turn lower the overall costs of coccidiosis. Understanding the biological aspects of the host response to *Eimeria* infections at a cellular level is crucial to the development of new approaches to coccidia control.

Eimeria acervulina

In the poultry industry, nine species of the genus *Eimeria* have been described in chickens; however, in recent years, only seven of these species are known to exist and cause pathogenic effects (Conway and McKenzie 1991; Williams, 1998). Coccidial species are classified based on attributes such as: 1) intestinal location of infection, 2) appearance of intestinal lesions, 3) oocyst size, shape, and color, 4) average prepatent period length, 5) size of invasive sporozoites and merozoites, and 6) type of cell parasitized and location within epithelial cells. Based on these characteristics, *E. acervulina, E. brunetti, E. maxima, E. mitis, E. necatrix, E. praecox,* and *E. tenella* are considered pathogenic for chickens. Of the seven species, *E. acervulina* (EA) has been one of the most frequently encountered coccidial parasites infecting poultry in commercial operations (Henken et al., 1994b; McDougald and Reid, 1997). Henken et al. (1994a) assumes that every flock is infected with coccidial parasites, and EA is responsible for the majority of these cases. Within the commercial broiler industry, infection with EA has major impacts on production. These impacts are related to how the host reacts to the parasite infection. However, there are other factors affecting the severity of disease such as the amount of viable EA oocysts ingested and pathogenicity of the isolate as well as the genetic, nutritional, and immune state of the bird (McDougald and Reid, 1997). A mild infection with EA could produce sub-clinical effects such as reduced feed utilization and increased feed passage, which can increase feeding costs and overall feed conversion ratios. However, a moderate to severe infection with EA can produce clinical signs such as loss of appetite, decreased water consumption, reduced weight gains, loss in skin pigmentation, diarrhea, lethargy, poor feed conversion, and whitish-gray lesions of the intestinal mucosa. Heavy infections may cause lesions to coalesce and death may occur (Johnson and Reid, 1970; Edgar, 1992; McDougald and Reid, 1997). While each species of *Eimeria* tend to be site specific, EA invades the anterior portion of the small intestine, specifically the duodenal loop and in severe infections, the anterior portion of the

jejunum. It is speculated that secreted molecules from the invasion site itself and surface molecules located on the parasite could be responsible for this site specificity (Lillehoj and Trout 1993; Jeurissen et al., 1996).

Immunity to Coccidial Parasites

As described above, *Eimeria* reside outside the host for part of their life cycle but, the majority of it is completed inside the host during asexual and sexual stages of development occurring inside or outside enteric tissues. Once the bird ingests the viable oocyst(s), a cascade of events occur involving both non-specific and specific defense mechanisms of immunity (Lillehoj and Lillehoj, 2000). It is to be expected that the mechanisms responsible for immunity are complex due to the complexity of the parasite life cycle. Despite all of the research completed on immunity to *Eimeria*, no clear picture has emerged as to how complete resistance is acquired and which mechanisms are sequentially involved in generation of immunity (Rose et al.,1979; Danforth and Augustine, 1989).

In naïve chickens, those previously unexposed to *Eimeria*, coccidial infections induce a variety of pathological and immunological responses, which help the host defend against the parasite and acquire protective immunity. However, the level of protection each facet of the immune system provides may vary with the developmental stage of the parasite (Rose, 1987). Prior to the generation of a specific immune response, the host tries to exclude the *Eimeria* through non-specific immune pathways such as competitive exclusion by normal flora, lysozymes, increased gastric secretions, and peristalsis to quickly flush parasites from the digestive tract (Lillehoj and Lillehoj, 2000; Yun et al., 2000). However, it has been reported that these innate defenses as well as specific immunologically mediated defenses play a role at the intestinal mucosal surface during *Eimeria* invasion (Lillehoj and Trout, 1993). Therefore, the naïve host probably does not eliminate the parasite utilizing only non-specific pathways, but infection can be controlled to a certain degree prior to the completion of the *Eimeria* life cycle and generation of a specific immune response.

It has been determined that *Eimeria* parasites are vulnerable to the host immune system at three distinct phases of their development: 1) the period between excystation and sporozoite penetration of epithelium, 2) once the sporozoite enters the host epithelium and is exposed to intra-epithelial lymphocytes, and 3) during transport of the sporozoite from the

surface enterocyte, through the lamina propria and into the crypt epithelium. After these stages in the life cycle, direct interaction between the parasite and cells of the host immune response are unlikely, and the probability of intervention is ceased (Jeurissen et al., 1996). During phases of the *Eimeria* life cycle that allow close contact with the immune system, both humoral and cell-mediated responses are stimulated; however, the contributions of each to protective immunity are still debated.

The immune response to coccidial parasites has been extensively reviewed (Lillehoj and Trout, 1996; Yun et al., 2000). As discussed in these reviews and in other literature, the humoral arm of the immune system has been shown to play a role in conferring immunity to coccidial parasites, possibly more in the control of primary infections, as evidenced by studies with bursectomized and bursal-diseased chickens. It was shown that B-cell depleted animals are less resistant to primary infections and more susceptible to challenge than controls (Rose and Hesketh, 1979; Rose, 1987; Lillehoj and Trout, 1996). It has been suggested that species-specific circulating antibodies released into the lumen of infected birds have a protective effect by directly blocking invasion at the mucosal surface or by enhancing intraluminal destruction of sporozoites (Lillehoj and Trout, 1996). Serum from immune birds has also been shown to have a protective effect against coccidiosis when given to naïve birds (Rose, 1984; McDougald, 1985; Rose, 1987; Lillehoj and Trout, 1996; Yun et al., 2000). Although studies have shown that antibodies prevent initial invasion, it is less certain if they limit the course of disease once infection is established (Lillehoj, 1991). However, it is believed that cell-mediated immunity has a far greater role in protection against coccidial parasites than humoral immunity, but both systems are important for birds to acquire complete protective immunity (Rose, 1987; Jeurissen et al., 1996).

Cell-mediated responses are an integral part of protective immunity as shown in experiments where T-cell depleted animals were unable to resist primary or secondary challenge infections (Rose and Hesketh, 1979; Rose, 1982a; Rose, 1987). Similar results were found when cyclosporin A (Cs-A), betamethasone, and dexamethasone, cell-mediated immune response suppressing agents, were given to naïve birds prior to *Eimeria* challenge (Lillehoj and Trout, 1993; Lillehoj and Trout, 1996). Talebi and Mulcahy (1995), observed a significant negative correlation between cellular lymphocyte responses and fecal shedding of oocysts in birds infected with homologous coccidia challenge, which supported the major

role of cell-mediated immunity. Further studies have confirmed that T-cell sub-population numbers in the intestinal epithelium and lamina propria change during primary and secondary EA challenge, specifically, CD4+ T-cell increases during primary challenge and CD8+ T-cell increases during secondary exposure (Lillehoj and Trout, 1996). These results suggest that variations in T-cell sub-populations may reflect infection-related changes in the intestine. Martin et al. (1995) separated several fractions from sporozoites and merozoites in order to identify antigens from EA and how they contribute to protective immunity. It was determined that the synonymous effects of cell-mediated and humoral responses confer a species-specific protection, which lasts throughout the life of the bird.

Protective immunity has normally been measured by maintenance of body weight gains, reduction in lesion scores, cessation in total oocyst output, and antibody and cellular responses in broiler birds (Stiff and Bafundo, 1993; Talebi and Mulcahy, 1995). While birds that have acquired protective immunity to a particular species of *Eimeria* no longer exhibit clinical signs of disease, they may continue to shed oocysts in the feces (Lee and Shih, 1988; Williams, 1998), a condition known as coccidiasis. However, Stiff and Bafundo (1993) showed conflicting results in a series of experiments that proved complete immunity can and does exist when birds are continuously challenged on a daily basis with homologous *Eimeria* challenge. Nevertheless, protective immunity hinders fecal oocyst production, and invasion of the mucosal epithelium is altered. Interestingly, in immune birds, sporozoites penetrate the villus epithelium but are incapable of reaching the crypt epithelium and prevented from further development (Rose et al., 1984; Jeurissen et al., 1996).

Physiological Changes

A closer look at histological and physiological changes that occur during the course of the immune response to coccidial parasites is pertinent to understand the specifics of immunity. Responses to *Eimeria* parasites at the intestinal mucosa may be mediated directly by the parasite or by the host's immunoinflammatory response, which may result in changes in the intestinal mucosal morphology (Barker, 1993). Physiological changes related to infection have been well documented in experiments with EA infected chickens. Results indicate that at the level of the intestinal mucosa, local and systemic responses to coccidia are mediated in different ways. Fernando and McCraw (1973) measured the intestinal response

to a single dose of EA, and infected birds showed a marked increase in total mucosal thickness, decreased villus height, and increased crypt length in the duodenum and to a lesser extent in the anterior jejunum. The mucosal alterations were the most severe at the height of infection, and a marked increase in the rate of replacement of intestinal epithelial cells was observed. In addition to an increase in duodenal epithelial cell turnover, Allen (1983) noticed an increase in metabolism of mucosal cells in the lower intestine, which may enhance compensatory growth and help the bird overcome the negative affects of infection on parameters of production. Other morphological changes were evident, such as increased gut length and increased tissue moisture (edema) in the intestine, which were not associated with starvation, but the sole effects of challenge. Changes in gut environment are also evident from challenge, such as decreased pH of the infected area (Ruff, 1984) and increased feed passage time (Stephens et al., 1974; McKenzie et al., 1986). These changes in gut homeostasis may alter feed intake, which leads to decreased nutrient digestion and absorption, changes in metabolism, and overall decreases in weight gains (Adams et al., 1996).

Interestingly, researchers have contrasting results in experiments where weight gains are measured. Stephens et al. (1974) and Adams et al. (1996) reported decreased weight gains associated with EA challenge, while Ogbuokiri and Edgar (1985) and McKenzie et al. (1986) showed no significant weight gain differences when compared to non-challenged controls. This difference in results could be associated with several factors such as genetics of the birds, route of challenge administration, amount of infective oocysts administered for challenge, and strain of EA (Danforth and Augustine, 1989). Additional studies have shown that initial contact of the sporozoites with the intestinal mucosa produces an inflammatory response including marked cellular infiltration at the site of infection (Rose et al., 1979). This infiltrate consists of multiple leukocyte sub-populations, macrophages, natural killer cells, granulocytes, and lymphocytes that could modulate and enhance immune responses; therefore, altering nutrient absorption and decreasing weight gains (Jeurissen et al., 1996).

The specific mechanisms by which each coccidial species causes disease is not clear; however, the establishment of secondary infections due to the altered intestinal mucosa may be responsible for a differential host response (Barker, 1993). This is possible because coccidia are able to interact with other pathogens such as bacteria and viruses, which may

amplify the observed effects (Ruff, 1993). As stated above, the ability of the chicken to control the severity of infection and develop protective immunity to coccidial parasites depends on numerous factors. Host responses to the parasite involve a complex series of internal factors that are dependent on developmental stage of the parasite, immune status of the bird, and species and strain of the *Eimeria* parasite.

Mast Cell Role in Coccidial Immunity

Current research has focused on alternative explanations for the mechanisms responsible for protective immunity to coccidial parasites. It is well established that many cells are involved in the response to *Eimeria* invasion, including rapid infiltration of polymorphonuclear cells (PMN), lymphocytes, and large mononuclear cells (LMN) to the site of inflammation (Rose et al., 1979; Rose, 1982a). Studies have indicated macrophages, granulocytes, and other leukocyte sub-populations are attracted to the lamina propria during primary infections, suggesting that these cells have a modulatory role in the intensity of *Eimeria* infections (Jeurissen et al., 1996). It appears that sporozoite contact with the mucosal surface activates a series of defense mechanisms, which lead to a local inflammatory cell influx. While much research has focused on lymphocyte involvement in protective immunity to *Eimeria*, other immune cell responses, particularly that of mast cells, to these pathogens have been neglected. Infection with *Eimeria* parasites produces reactions similar to those seen in infections with other parasites, both protozoa and helminths (Rose and Hesketh, 1982). However, there is limited data regarding the role of mast cells in the response to coccidial infection in poultry.

Mast cells contain metachromatic-staining granules that store numerous inflammatory mediators. These cells originate in bone marrow haemopoietic tissues and migrate via the blood stream to the localized area where they develop and multiply. Mast cells are most commonly recognized for mediating the pathophysiology of allergic diseases (Abraham and Arock, 1998). However, evidence supports a multifaceted and significant role in immune reactions including mucosal inflammation, tissue repair, and other immunological responses (Yong, 1997). Mast cells possess distinct attributes that support their role in immune responses such as: 1) their location at the interface between the host and environment, in particular, around blood vessels, in the skin, and in mucosal surfaces including the

gastrointestinal tract, 2) their capacity to release a wide range of inflammatory mediators, and 3) their capacity to undergo multiple cycles of mediator release (Abraham and Arock, 1998). However, researchers are limited in their ability to accurately describe the presence of mast cells during inflammatory responses due to changes in staining properties and morphological shape with respect to tissue location as well as variation between animal species (Yong, 1997).

It is now known that in mammals, mast cell responses, especially their IgE mediated responses to certain parasitic infections, contribute to adaptive immunity (Rose, 1982a; Gray, 1976; Abraham and Arock, 1998). Mast cells accomplish this protection by releasing a myriad of pharmacologically active products including histamine, heparin, and serine proteases once the cell is stimulated by antigen, activation of IgE, or other host-derived proteins, which are generated during inflammatory reactions (Abraham and Arock, 1998). These mast cell derived products are considered to play a role in the innate rejection system of the host by promoting local smooth muscle contraction, an increase in vascular permeability resulting in localized edema, an increase in mucosal permeability, facilitating a rapid accumulation of antibodies and effector cells to mucosal surfaces, and intestinal ion secretion, in particular Cl^- associated with intestinal anaphylaxis (Shi et al., 2000; Tizard, 2000).

In studies conducted with mutant mice, virtually lacking mast cells, the specific importance of mast cell mediators was shown to be crucial in acquiring protective immunity to intestinal protozoal infections, specifically *Eimeria* infection (Rose and Hesketh, 1982; Huntley et al., 1985). In response to challenge with *E. separata* in rats, Shi et al. (2000) reported an increase in mucosal mast cells following primary challenge and a further stimulation of mast cell numbers by re-infection. Sensitization of the intestinal mucosa with antigen, especially in a secondary infection or exposure, results in the association of antibodies with mast cells in the lamina propria of the small intestine, which results in further stimulation of mast cell proliferation and subsequent release of their pre-formed granules (Harari et al., 1987; Harari and Castro, 1989). This rapid response of mast cell proliferation and activation results in changes of the physiologic environment in the intestine, altering the host-parasite interaction, and limiting, if not prohibiting the organism's ability to establish itself in the host's tissue (Harari et al., 1987). The capacity of mast cells to induce

pathological effects by excessive or inappropriate release of inflammatory mediators may contribute to an increased secretory response via excessive fluid and electrolyte secretion resulting in edema of intestinal tissue and ultimately, diarrhea. In addition, the quantity of mucosal mast cells responding to antigenic stimulation can dictate the intensity of the host's physiological response (Harari and Castro, 1989). Such reactions could contribute to detrimental affects similar to what occurs with food allergies, including fecal blood loss, malabsorption, and villus atrophy (Metcalfe, 1984).

While research has confirmed that mast cells play a major role in parasitic nematode infections in birds (Gray, 1976) and mammals (Rose and Hesketh, 1982b; Fernando, 1982; and Huntley, 1985), there is limited documentation regarding mast cell involvement in chicken *Eimeria* infections. Data reported by Rose and Hesketh (1982), Fernando (1982), and Huntley (1985), suggest similar roles of mammalian and chicken mast cells in enteric *Eimeria* infections. Rose et al. (1975) found that a hypersensitivity reaction, as shown by increased permeability to macromolecules of the gut, to EA parasites does exist. Affected duodenal tissues showed signs of edema with a thickened and "juicy" appearance due to responses mediated through the release of histamine mediators produced by an increase of mucosal mast cells. This response was greater in immunized animals when compared to controls, with a heightened response during secondary exposure to EA challenge. Similar studies have reported an acute intestinal mucosal mastocytophilia response to secondary *Eimeria* challenge in chickens (Rose et al., 1980; Daszak et al., 1993); however, it was questionable if there was a true increase in mast cell numbers or if cell migration occurred (Daszak et al., 1993). Although these reports describe the appearance of mast cells in enteric parasitic infections, there has been limited research to further characterize their specific effector roles in immune response mechanisms. Despite the evidence on a variety of immune responses induced in chickens by infection with coccidial parasites, further research needs to be conducted on accessory cells and intrinsic immune factors to aid in the development of control strategies.

Immunovariability of the Eimeria Species

Commercial broiler chickens are reared under conditions favorable for the propagation of coccidial infections. Historically, the severity of coccidiosis has been

controlled through the continuous use of anticoccidial drugs and antibiotics, which have been used to reduce the frequency of apparent clinical signs and prevent widespread disease. However, coccidial outbreaks occur more often due to the rising emergence of drug-resistant strains. Since the late 1940s, producers have included prophylactic medication in the rations of broilers from one-day old until slaughter, which has resulted in widespread drug-resistance (Chapman, 1982). The efficacy of these drugs has been sequestered due to parasite modifications, which allow them to flourish in the presence of these preventatives.

Until recently, coccidia were classified according to morphological, physiological, and behavioral characteristics such as those described by Brackett and Bliznick (1950). Today, it is known that different isolates within species of *Eimeria* exist (Chapman, 1982) but, little information is available comparing the immunogenicity and immunovariability of such isolates. Shirley (1985) described new techniques for revealing definitive markers of different strains within the same species of *Eimeria*; however, the differential host response to the different strains was discussed in minute detail. Several authors briefly state events within their experiments in which different strains were noticed (Talebi and Mulcahy, 1995). It has been shown that different strains are capable of having antigenic diversity, so that the immunity conferred by one species strain does not completely protect chickens against further challenge with a different strain of the same species (Talebi and Mulcahy, 1995). In a review on the use of coccidial vaccines by Danforth and Augustine (1989), it was stated that isolates from different geographical areas do not always show cross-protection following oral immunization. This may be a challenging factor in producing specific vaccines for coccidial control. More studies need to be conducted to evaluate the variability in the host's protective immune response to different strains. This will expand the ability to find new alternatives for vaccine control; however, it is possible that the coccidia may find new ways to alter their antigenicity (Danforth and Augustine 1989).

INTESTINAL MUCOSAL MAST CELL IMMUNE RESPONSE AND PATHOGENESIS OF TWO *EIMERIA ACERVULINA* ISOLATES IN BROILER CHICKENS

INTRODUCTION

In the modern commercial poultry industry, increases in disease and infections by enteric pathogens are common due to intense rearing systems. One disease of particular concern is coccidiosis. Coccidiosis is caused by species-specific protozoal parasites of the genus *Eimeria*. Infections caused by coccidial parasites have had a major economic impact on the commercial broiler industry in the past several decades. It has been reported that the US poultry industry suffers in excess of one to two billion dollars in annual losses relating to coccidial treatment, infection, and prevention (Danforth and Augustine, 1989; Talebi and Mulcahy, 1995; Yun et al., 2000).

Chickens are infected by coccidial parasites through the fecal-oral route, and immunity is achieved once the parasite completes its life cycle within the host. Once the coccidial oocyst is ingested, *Eimeria* parasites penetrate enterocytes along the digestive tract at specific regions of the gut depending on the parasite species. Initial invasion is followed by subsequent parasite development, and severe damage to the intestinal lining occurs. This disruption of the mucosa leads to decreased nutrient absorption, increased feed conversion ratios, decreased weight gains, lethargy, diarrhea, and in severe cases, mortality. Historically, coccidial parasites have been controlled through the use of in-feed coccidiostats. However, through the years, drug-resistant strains of *Eimeria* have emerged, which hinder the efficacy of the presently used coccidiostats.

Coccidial infections induce a variety of pathological and immunological responses which help the host defend against the parasite and acquire protective immunity. In addition, it has been reported that both immunologically mediated and non-immunological defenses play a role at the intestinal mucosal surface during *Eimeria* invasion (Lillehoj and Trout, 1993). It has been difficult to completely understand these protective mechanisms due to increases in drug-resistant strains and the complexity of the *Eimeria* species life cycle. Past studies have measured the severity of coccidiosis on the basis of weight gains, lesion scores, cessation of total oocyst output, and humoral and cellular responses (Stiff and Bafundo, 1993; Talebi and Mulcahy, 1995). However, a closer look at the histological and physiological changes at the mucosal level is pertinent to understand the specific nature of this immunity.

It is well established that B and T-lymphocytes are involved in responses to *Eimeria* invasion, but there is limited data concerning the possible participation of other effector cells, such as mast cells, which may participate in protective immunity. It is known that mast cell responses contribute to adaptive immunity in mammalian parasitic infections (Rose, 1982; Abraham and Arock, 1998), but their involvement in chickens has been largely overlooked. However, an acute mucosal mastocytophilia response has been reported during secondary *Eimeria* challenge in chickens (Rose et al., 1980). These responses have been questioned as to if there was an increase in mast cell numbers or if cell migration occurred (Daszak et al., 1993). Mast cells possess distinct attributes that support their role in immune responses, but researchers have been limited in their ability to accurately describe the presence of mast cells during inflammatory responses due to changes in staining properties and morphology associated with tissue location and species variation (Yong, 1997). If mast cells are in fact responsible for aiding in protective immunity, it is imperative that they are positively identified. Microscopic differential counting should indicate significantly elevated numbers of mast cells in the small intestine.

Until recently, coccidia were classified according to morphological, physiological, and behavioral characteristics such as those described by Brackett and Bliznick (1950). Today, it is known that different isolates within species of *Eimeria* exist (Chapman, 1982). However, little information is available comparing the immunogenicity and immunovariability of different strains within each *Eimeria* species. Shirley (1985) described new techniques for revealing definitive markers of different strains within the same species of *Eimeria*; however, the differential host response to the different strains was discussed in minute detail. Several authors briefly state events within their experiments in which different strains were noticed (Talebi and Mulcahy, 1995). It has been shown that different strains are capable of having antigenic diversity, so that the immunity conferred by one species strain does not completely protect chickens against further challenge with a different strain of the same species (Talebi and Mulcahy, 1995). In reviews on the use of coccidial vaccines by Danforth and Augustine (1989) and Danforth (1998), it was stated that isolates from different geographical areas do not always show cross-protection following oral immunization. This may be a challenging factor in producing specific vaccines for coccidial control. Additional studies need to be conducted to evaluate the variability in the host's protective immune

response to different strains. This will expand opportunities for the development of alternative control measures; however, it is possible that the coccidia may find new ways to alter their antigenicity (Danforth and Augustine, 1989; Danforth, 1998).

The interaction between the *Eimeria* and the intestinal mucosal immune system is a key component to the defense of the chicken to these enteric pathogens. Before control strategies can be improved upon, it is important to first understand the host-parasite interaction and the possible role of effector cells in the immune response. The aim of the present study was to further investigate the host-parasite interaction and the mechanisms responsible for protective immunity to coccidial parasites at the mucosal level in broiler chickens and to also determine if differential responses are associated with breed type. In the experiments conducted, two isolates of *Eimeria acervulina* (EA) were given to broilers of two breeds to determine if immunovariability exists between different strains within the same species and to analyze the differential mast cell and morphological intestinal host response with each.

MATERIALS AND METHODS

Experimental Animals

In all experiments, straight-run, day-of-hatch broiler chicks of breed A (Cobb) or breed B (Ross) were obtained from a local commercial hatchery. Chicks were placed on either clean pine shavings (Experiment 1, 2, 3, and 5) or wire-floored starter batteries (Experiment 4) and given *ad libitum* access to water and un-medicated starter feed, which met or exceeded NRC (1994) requirements. For the first two weeks of life, all chicks were housed in the same room with a controlled environment. Ambient temperature was set at 33°C for bird placement and decreased to 28°C by day 14. Supplemental heating lamps were provided for the birds during the first 5 days of life. At 14 days of age (day 15 for Experiment 3), chicks were weighed, wing-banded for breed and number identification, and randomly assigned to non-challenged or challenged treatment groups. Control birds were then housed in a separate room, within the same building, from the challenge birds for isolation purposes. Rooms were monitored and maintained at the same ambient temperature (28°C) from day of challenge (day 14 of age) through day 6 post-challenge (PC). In all

experiments, rooms provided adequate negative pressure ventilation and birds were kept on continuous incandescent lighting.

Eimeria

Two EA isolates, *Eimeria acervulina* isolate 1 (EA1) and *Eimeria acervulina* isolate 2 (EA2) were supplied by Dr. Harry Danforth (USDA/ARS, Beltsville, MD) for use in these experiments. Oocysts were stored at 4°C in a 2% potassium dichromate solution prior to challenge. Aliquots of the stock concentrations were taken at the time of each experiment and washed for removal of potassium dichromate prior to dilution to challenge inocula concentration. Briefly, oocysts for challenge were centrifuged for 10 minutes at 4°C and 845 x *g*. The supernate was removed, and the remaining pellet was re-suspended in ddH_2O and centrifuged again using the same method. This process was repeated a minimum of three times to remove the potassium dichromate. After the final centrifugation, the pellet was re-suspended with sterile PBS for quantification of oocysts with a hemocytometer. Additional PBS was added to bring the inoculum to the desired challenge dose. Challenge concentrations for each experiment were determined by dose titration prior to the first trial and by the previous experimental results for all subsequent trials. All chicks in challenge groups received 1 mL of quantified sporulated oocysts *per os* directly into the crop using an oral gavage on day of challenge.

Morphometric Analysis

Descending duodenal loop samples (~25mm) were collected six days PC for analysis of cellular infiltrate of mast cells and morphological changes including villus height and crypt depth. Duodenal tissue from each broiler was fixed in 10% neutral buffered formalin for 48 hours and then placed in 70% ethyl alcohol (EtOH). Each tissue was cut into five sections for placement on each slide. Tissues were processed, embedded, and sectioned at 4 microns for slides. Tissues were stained with toluidine blue for the identification of mast cells and morphological measurements. Mast cell counts were made in the lamina propria region of the villus using an intraocular 5 x 5 eyepiece grid (total area 156.25 μm^2) with the 40X objective of a bright-field microscope. A total of three complete tissues/slide and 15 grids/tissue were counted to quantify mast cells. Morphological changes were measured in millimeters using a bright-field microscope and the Sigma Scan Pro® software program[1]

[1] SSPS Inc., Chicago, IL

(Figure 1). A total of three tissues/slide and four measurements/tissue were taken for changes in villus heights and crypt depths. Villus to crypt ratios were determined by averaging villus height measurements divided by crypt depth measurements.

Experimental Design

Five experiments involving a total of 663 chicks were conducted to evaluate the intestinal response to two isolates of EA. In four of the five experiments, birds were challenged with one of two EA isolates, and data was collected to compare differences in body weight gain, lesion scores, morphometric alterations, and mast cell influx into the upper small intestine. The fifth experiment was conducted to determine if the differential host response was due to the parasite-host interaction itself, or if there was some other organism involved, such as a bacterial or fungal contaminant. In two of the experiments conducted, the responses of two commercial broiler breeds were compared to determine if there was a different degree of susceptibility or pathological response to the two isolates of EA.

In all experiments conducted, birds were identified with metal wing bands (excluding Experiment 1) and weighed individually on day of challenge and six days PC for determination of body weight gain during the challenge. On day 6 PC, chicks were killed by cervical dislocation, and the duodenum of the upper small intestine was quickly removed and evaluated for intestinal lesion scores using the method described by Johnson and Reid (1970).

Experiment 1. Straight-run broiler chicks of breed A (n = 105) were randomly divided and placed into two floor pens (n = 52 and 53/pen) for the first 14 days of life. On day 14, birds were randomly assigned to one of three treatment groups (n = 35/pen); control (non-challenged), EA1, or EA2. Birds were challenged *per os* with 1.25×10^5 oocysts/mL of EA1 and 1.50×10^5 oocysts/mL of EA2, respectively. On day 6 PC, all birds were weighed, lesions were scored (n = 35/treatment) and duodenal samples (n = 10/treatment) were taken for morphometric analysis.

Experiment 2. Straight-run broiler chicks of two commercial breeds (breed A and breed B; n = 75/breed) were raised in two floor pens dependent on breed for the first 14 days of life. On day 14 (day 0 PC), birds were randomly separated into three treatment groups with an equal number of breed A and B (n = 25 birds per breed/treatment) within each group. Both challenge doses were increased by 2.5×10^4 oocysts/mL upon evaluation of the

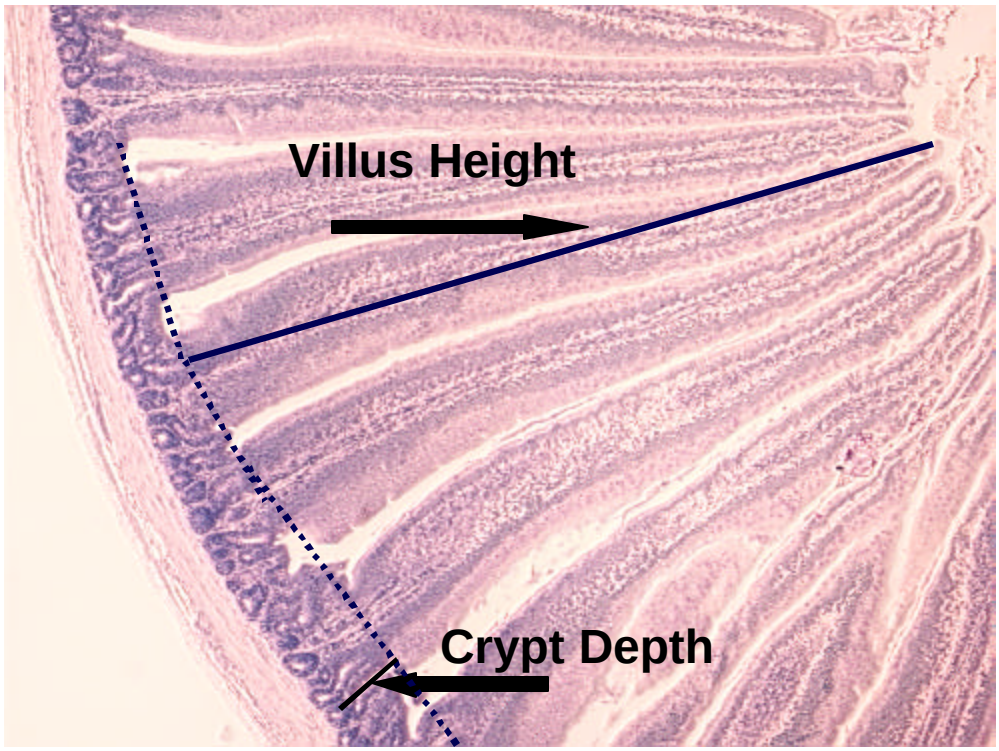

FIGURE 1. Image (4X) of a duodenal section of a broiler 6 days post-challenge. The dotted line denotes the separation between the villus structures and the intestinal crypts. Measurements for villus height were taken from the dotted line to the villus tip, and crypt depth measurements were taken from the dotted line to the base of the crypt.

responses in Experiment 1 and to prevent a possible lack of response due to aging factors of EA oocysts. Challenged groups received 1.50 x 10^5 oocysts/mL EA1 or 1.75 x 10^5 oocysts/mL EA2 *per os*, respectively. On day 6 PC, all birds were weighed, lesions were scored (n = 25 birds per breed/treatment), and duodenal samples were taken from 10 birds per breed/treatment for histological examination. Data collection and morphometric analysis were performed as previously described.

Experiment 3. Experiment 3 differed from Experiment 2 in that birds were challenged with 2.0 x 10^5/mL of EA1 or 2.5 x 10^5/mL of EA2 on day 15 of age rather than 14. On day 6 PC, all birds were weighed, lesion scored (n = 25 birds per breed/treatment) and duodenal samples were taken from 10 birds per breed/treatment for histological examination. Data collection and morphometric analysis were performed as previously described.

Experiment 4. Experiment 4 was conducted to evaluate the time-course (day 2 PC – day 6 PC) of the intestinal mast cell immune response and pathogenesis in response to EA1 and EA2 challenge. Straight-run broiler chicks of breed A were raised in starter batteries[2] (n = 20/cage) with feed and water *ad libitum*. On day 14, chicks were randomly distributed into three experimental groups (n = 66/treatment) and placed in grower batteries (n = 22/cage; 3 replicate pens/group) with controls and challenged groups housed in separate rooms. Challenged groups received 3.0 x 10^5 oocysts/mL EA1 or 3.0 x 10^5 oocysts/mL EA2 *per os*. New harvests of EA1 and EA2 were used in this experiment to ensure an infective state. On each of days 2 - 6 PC, nine birds per treatment were euthanized and samples of duodenal tissue were taken. On day 6 PC, all remaining birds (n = 30/treatment) were scored for lesions. Data collection and morphometric analyses were performed as described above.

Experiment 5. Trial five was completed to determine if bacterial contamination of the EA2 inocula was responsible for a differential host response. Oocysts for challenge were prepared using the following cleaning procedure. Four mL of EA2 oocysts, as used for previous challenge (3.66 x 10^6/mL) were placed in 15mL conical tubes and centrifuged twice at 845 x *g* for 10 minutes. The oocyst pellet was cleaned with either 5.25% sodium hypochlorite or ddH_2O at the ratio of 1.5 times the pellet volume and agitated. The oocysts were transferred to 50mL conical tubes and maintained at 4°C for 30 minutes, with gentle

[2] PETERSIME NV - Centrumstraat 125 - B-9870 Zulte - Belgium

swirling at 10-minute intervals. The tubes were then filled with ddH_2O (47mL) and centrifuged for 15 minutes at 4°C and 1320 x *g*. The supernate was removed and centrifugation was repeated 5 times. The pellet was re-suspended with sterile PBS and oocysts were quantified using a hemocytometer. PBS was added to bring the inoculum to the desired challenge dose of 2.5×10^5 oocysts/mL. The inoculum was held on ice until the birds were challenged.

Straight-run broiler chicks (n = 60) of breed A were placed in floor pens for the first 14 days of life. On day 14, birds were randomly separated into three treatment groups consisting of control (non-challenged), EA2 group 1 (challenged with 2.5×10^5/mL of 5.25% sodium hypochlorite washed oocysts) and EA2 group 2 (challenged with 2.5×10^5/mL of ddH_2O washed oocysts). On day 6 PC, duodenal samples (n = 10/treatment) were collected and all birds were lesion scored (n = 20/treatment). Data collection and morphometric analysis were performed as previously described.

Statistical Analysis

Weight gains, duodenal lesion scores, and morphometric alteration data were analyzed by ANOVA using the GLM procedures of SAS® (SAS Institute, 1998). Mast cell counts were log transformed prior to analysis of the GLM procedures and then converted to original scale using the inverse log function. LSmeans procedure of SAS® was used to obtain the equivalent of Tukey's honestly significant difference comparisons (SAS Institute, 1998). All results, unless otherwise stated, were reported at the $P \leq 0.05$ level.

RESULTS

Experiment 1

Table 1 summarizes the effects of two isolates of EA on duodenal lesion scores, morphometric alteration, and local mast cell response in broiler chicks in Experiment 1. Lesions in the duodenal intestinal mucosa were clearly apparent of challenged birds when compared to controls, which had no lesions. Birds inoculated with EA1 produced an average lesion score of 2.35, which was significantly greater ($P \leq 0.0001$) than an average score of 0.77 for EA2 challenged birds. Lesions present in the duodenum of EA1 challenged birds were white and coalescing, giving a ladder-like appearance (Figure 2), whereas, EA2 challenged birds produced fewer, scattered lesions with intestinal tissue signs of edema and a

FIGURE 2. Photograph of the mucosal surface of the duodenal loop 6 days post-challenge from a bird inoculated with *Eimeria acervulina* isolate 1. Intestinal lesions are white and ladder-like, covering much of the mucosal surface.

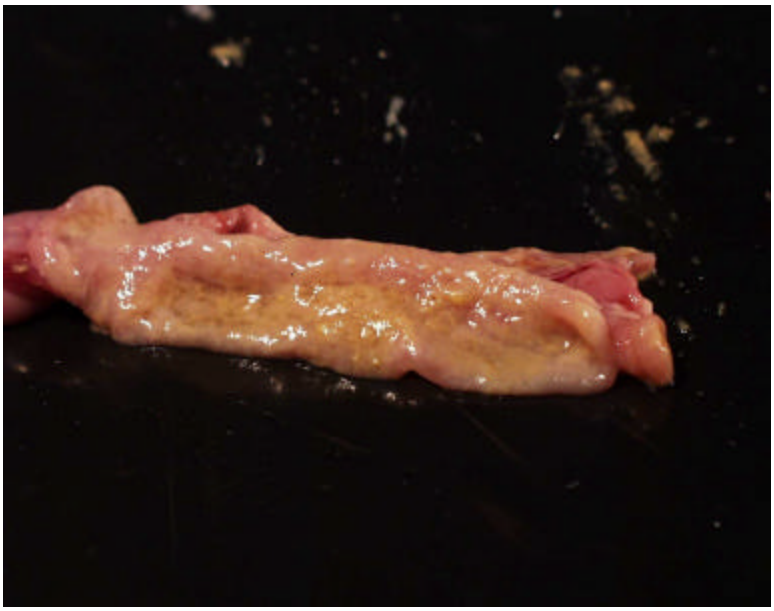

FIGURE 3. Photograph of the mucosal surface of the duodenal loop 6 days post-challenge from a bird inoculated with *Eimeria acervulina* isolate 2. There is apparent edema and sloughing of the mucosal epithelial layer. There are few white, ladder-like intestinal lesions.

loss of pigmentation (Figure 3). No significant differences were found between control and the EA2 infected birds in average villus height and crypt depth measurements. However, EA1 produced lower villus height ($P \leq 0.01$) and greater crypt depth ($P \leq 0.0001$) measurements when compared to controls and EA2 challenged birds (Figures 4 and 5). Villus height to crypt depth ratio was found to be lower in EA1 challenged birds ($P \leq 0.0001$) when compared to control or EA2 challenged groups with no significant differences between control and EA2, which is not surprising due to greater crypt measurements and lower average villus heights. Mast cells located in the lamina propria of EA2 inoculated birds were found to be numerically greater. This was significantly greater when compared to EA1 challenged birds ($P \leq 0.05$) but not controls. There was no significant difference between the number of mast cell for EA1 challenged birds and controls.

Experiment 2

Experiment 2 compared the effects of two isolates of EA on two commercial broiler breed types. Results of Experiment 2 (Table 2) indicate little differences between EA2 challenged birds and non-challenged controls, with the exception of higher weight gains in EA2 infected birds ($P \leq 0.05$). Overall, weight gains were lower ($P \leq 0.0001$) in breed B compared with breed A. While there were no lesions present in either EA2 challenged or control groups, EA2 challenged birds appeared to have watery intestinal contents when compared to non-challenged birds. Lesions of the intestinal mucosa were observed within both breeds of EA1 challenged groups, of which, breed A had fewer lesions than breed B ($P \leq 0.05$). Differences in villus height were observed between breed and between treatments. Breed A had significantly longer average villi length than breed B, and villi were significantly shorter in EA1 challenged birds as compared to either EA2 challenged or non-challenged groups. Birds challenged with EA1 also had deeper crypts, which in association with shorter villi, resulted in a significantly decreased villus to crypt ratio compared to control or EA2 challenged birds. No differences between breeds occurred for either crypt depth or villus to crypt ratio. There were no interactions present in mast cell count data; however, there were greater numbers of mast cells present in breed B birds ($P \leq 0.05$) as compared to breed A.

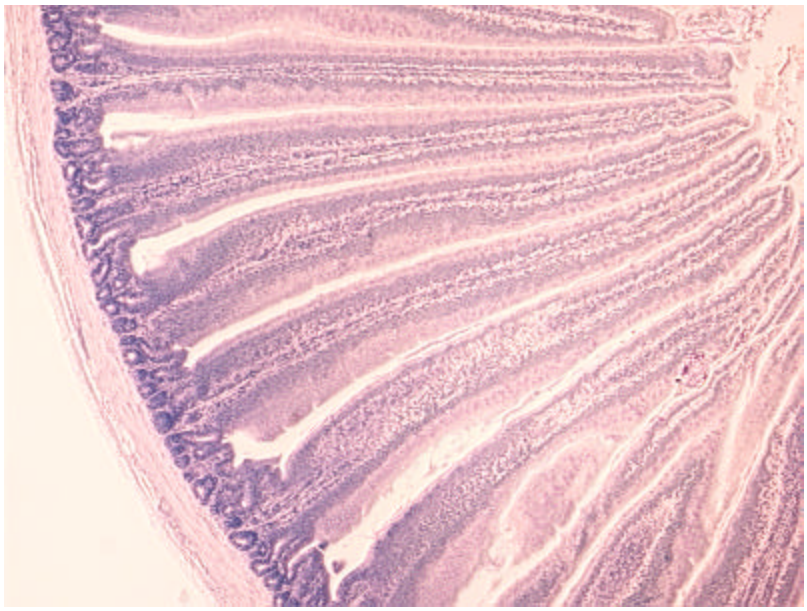

FIGURE 4. Image (4X) of a duodenal section of a control bird. The villus structures appear long, slender, and structurally complete with short crypts.

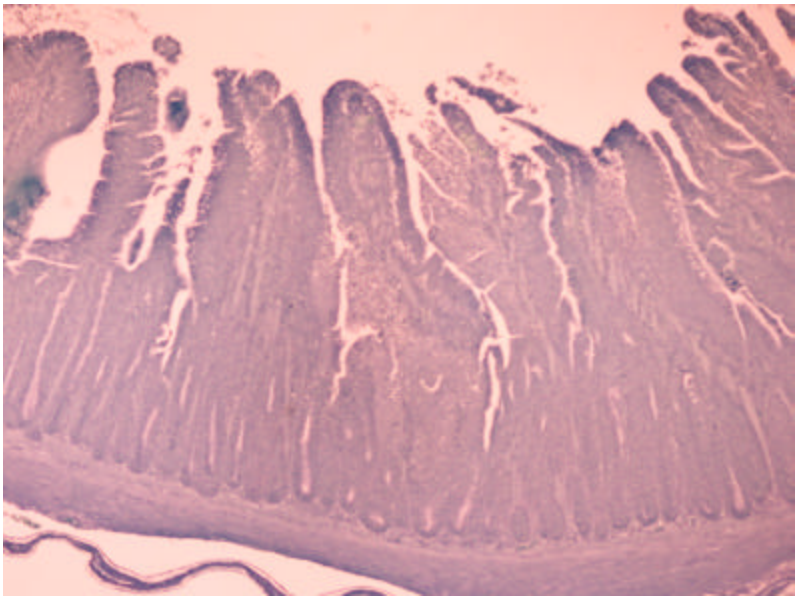

FIGURE 5. Image (4X) of a duodenal section of a *Eimeria acervulina* isolate 2 challenged bird 6 days post-challenge. The villus structures are short and thickened. Crypt hyperplasia is evidenced by long crypts as compared to villus heights.

Experiment 3

Similar to Experiment 2, Experiment 3 compared the pathophysiology of EA1 and EA2, on two commercial broiler breed types (Table 3). Infection with EA2 produced significant differences in all measured parameters when compared to EA1 or controls, including decreases in weight gains ($P \leq 0.0001$), lesion scores ($P \leq 0.01$), villus height ($P \leq 0.0001$), and villus to crypt ratios ($P \leq 0.05$), as well as an increase in crypt depth ($P \leq 0.0001$). In addition to these differences, EA1 also resulted in significantly increased lesion scores ($P \leq 0.01$) and decreased villus height to crypt depth ratio as compared to controls. No significant differences in mast cell counts were observed in this experiment between breeds or treatments. Breed A exhibited greater weight gains ($P \leq 0.05$), villus heights ($P \leq 0.001$), and villus to crypt ratios ($P \leq 0.05$), when compared to breed B. EA1 challenged birds appeared healthy and exhibited no clinical signs, whereas, EA2 challenged birds visually appeared to be listless and in a moribund condition. However, upon necropsy, white plaque-like intestinal lesions were prominent in EA1 challenged birds. On the other hand, EA2 challenged birds exhibited few plaque-like lesions, but there was evidence of epithelial sloughing of the intestinal mucosa and the intestines appeared pale and friable.

Experiment 4

To follow the time course of the mucosal responses to EA1 or EA2, Experiment 4 compared morphological alterations and mast cell influx on days 2 through 6 PC and weight gain and lesion scores on day 6 PC in breed A broiler chickens. Weight gains of birds challenged with EA1 were depressed ($P \leq 0.05$) when compared to controls (Table 4), while weight gains of birds challenged with EA2 were not different than controls. No differences were found in lesion scores between EA1 or EA2 challenged birds, which were both significantly increased as compared to controls with no lesions. Measurements taken from duodenal tissue 2 to 6 days PC of EA1 birds revealed a rapid decrease in villus height, reaching a minimum height on day 5, at which time, significant differences were found when compared to control or EA2 challenged groups. On day 6 PC, EA1 challenged birds showed an increase in villus height from day 5 PC, which was not significantly different than EA2 challenged birds, but was lower ($P \leq 0.05$) than controls. Duodenal crypt depths were increased by EA infection ($P \leq 0.05$) on days 4 through 6 PC when compared to controls, with EA1 having significantly deeper crypts than EA2 on days 5 and 6 PC. Villus height to

crypt depth ratios were lower ($P \leq 0.01$) in challenged birds than controls on days 4 through 6 post-challenge, with the exception of treatment group EA2 on day 4PC, which was not significantly different. There were no differences between EA1 and EA2 inoculated birds prior to day 5 PC, at which point EA1 had a significantly lower villus heights, increased crypt depths, and an overall lower villus height to crypt depth ratio. Mast cell counts for EA1 challenged birds were significantly greater than controls ($P \leq 0.05$) on days 3 and 4 PC; however, EA2 mast cell counts were not significantly different from EA1 or controls on any day sampled. Responses in morphometric alterations and mast cell counts for different days PC, as well as different treatments, are summarized in Table 5. Average villus heights were the lowest on day 5 PC, which was significantly different than day 3 PC when villus height was at its greatest length. Villus heights on day 2, 4, and 6 PC were not different from day 3 or 5 PC. Crypt depths were found to increase ($P \leq 0.0001$) during day 5 and 6 PC with controls having the least ($P \leq 0.0001$) and EA1 having the greatest ($P \leq 0.0001$) crypt measurement, both of which differed significantly from EA2 challenged birds. Accordingly, villus height to crypt depth ratios were found to decrease ($P \leq 0.001$) during days 5 and 6 PC with controls having the highest ($P \leq 0.01$) and EA1 having the lowest ($P \leq 0.01$) villus height to crypt depth ratio, both of which differed significantly from that of EA2 challenged birds. Mast cell numbers were higher on day 6 PC ($P \leq 0.05$) than on day 3 PC, with more cells being detected in the challenged birds ($P \leq 0.05$). Observational data revealed responses to EA1 and EA2 were quite different in this experiment than the other trials conducted. In Experiment 4, there appeared to be a secretory response in EA1 challenged birds, and a similar, but less severe response in EA2 challenged birds.

Experiment 5

To evaluate the possibility of a contaminant in the EA2 challenge inocula contributing to the differential host response and pathology, Experiment 5 compared the effects of inoculating birds with EA2 oocysts washed with either ddH_2O or 5.25% sodium hypochlorite. Weight gains of challenged birds were found to be lower ($P \leq 0.05$) than controls for both the disinfected and unclean oocyst preparations (Table 6). Lesions were only present in challenged birds, with no significant differences between EA2 cleaned and EA2 as used for other experiments. Intestinal contents of challenged birds were watery with sloughed epithelium present in the lumen. Overall appearance of the duodenum in

challenged birds appeared pale with a weakened intestinal strength when compared to controls; however, these observations were not analyzed. Villus height decreased, crypt depth increased, and villus height to crypt depth ratios decreased in both challenged groups as compared to controls ($P \leq 0.0001$), with no differences present between challenged groups. No differences in mast cell counts were present in this experiment.

DISCUSSION

The present studies were conducted to evaluate variability in the host response to a single challenge with one of two EA isolates, as well as determine if responses were influenced by the genetics of the bird. These experiments demonstrated that immunovariability does exist between two different isolates within the same species of EA. Differences in body weight gains PC, duodenal lesion scores, villus height and crypt depth, and localized mast cell influx were dependent upon which EA strain was administered; however, quantified and observed effects were not always consistent and were possibly influenced by the challenge dosages of EA.

Weight gain differed between breed A and breed B in non-challenged controls, which was expected due to different growth rates of the two breeds. Birds of breed A had faster growth rates than breed B in the first two weeks of life in our experiments. Evidence has indicated that genetics also have a major role in the bird's immune function and ability to cope with coccidial parasites (Lillehoj, 1988; Uni et al., 1995). With the exception of Experiment 4, weight gains in EA1 challenged birds, were not significantly different from weight gain of controls. In contrast, EA2 significantly depressed weight gains in challenged birds when compared to controls in experiments 1, 3, and 5, but not 2 or 4. This discrepancy in weight gain response could be attributed to insufficient oocyst challenge or aging factors of the inocula (Ruff et al., 1981). Studies conducted using homologous EA challenges have also indicated differing weight gain results. Ogbuokiri and Edgar (1986) and McKenzie et al. (1987) reported that no weight gain differences were detected between challenged birds and controls, whereas, Stephens et al. (1974) reported depressed weight gains with EA inoculation. These differences in weight gains are not surprising due to the fact that many factors are involved in an *Eimeria* infection such as a disruption of the intestinal mucosa, compromised nutrient absorption, and accelerated feed passage through the digestive system

(Jeurissen, 1996; McDougald and Reid, 1997; Yun, 2000). In addition, the degree of infection, the amount of water and food consumption (Williams, 1996), the strain of EA, and the inoculating dosage of EA are all factors contributing to differential weight gains (Long and Johnson, 1988; Gratt et al., 1996). However, the immune system has a high demand for nutrients during an infective state, and therefore, generation of an immune response could be a direct contributor to impaired growth. Variations in experimental design and factors stated above can independently or in combination have an influence on host responses to weight gains in an *Eimeria* infection.

In all experiments conducted, lesions of the duodenal mucosa of EA1 challenged birds consisted of typical white, ladder-like plaques, which were consistent with the findings of Johnson and Reid (1970) upon which the current method of lesion scoring was based. However, EA2 produced significantly fewer classical lesions, but exhibited signs of a secretory response. In Experiments 2 and 4, these findings were not consistent. In Experiment 2, there were no intestinal lesions in EA2 challenged birds, possibly due to the age or infective ability of the isolate. In Experiment 4, EA1 challenged birds exhibited clinical signs characteristic of EA2 challenged birds and vice versa. The same response was found upon examination of the intestinal contents, EA1 produced a secretory response that had been characteristic of EA2 challenged birds. Interestingly, the alterations in lesion appearance in Experiments 2 and 4 correspond to the contrasting results of body weight gain in these experiments. Intestinal lesions were present even when weight gains of the challenged birds approached those of non-challenged controls. Breed differences in lesion scores were only found in Experiment 2, with breed A having significantly fewer lesions, which supports the fact that genetics play a role in immune status (Lillehoj, 1988; Lillehoj and Trout, 1993; Yun et al., 2000). Differences in lesion scores found between EA1 and EA2 challenged birds within the same breed could possibly be related to the challenge doses given or the fact that the two isolates are generating a differential host response due to the presence of different surface antigens, which may or may not cause edema and the presence of intestinal lesions (Lillehoj and Trout, 1993). Similar findings suggest that immunological mechanisms responsible for protecting birds against weight loss may differ from mechanisms that protect against lesions of the intestinal mucosa (Augustine, et al., 1991).

Coccidiosis is known to produce different histopathological features depending on the *Eimeria* species (Johnson and Reid, 1970; Lillehoj and Trout 1993; McDougald and Reid, 1997). However, examination of the duodenal tissues taken from EA inoculated birds 6 days PC confirmed a differential host response to different EA isolates as well. EA1 significantly reduced villus lengths when compared to controls, except in Experiment 3. Similarly, birds challenged with EA2 had altered villus heights, although, these findings were not consistent in all experiments. *Eimeria acervulina* strain 1 produced results comparable to those in experiments conducted by Fernando and McCraw (1973) for a single infection with EA. No differences in villus height were found between control and EA1 challenged birds until days 5 and 6 PC, which are days considered to be the height of infection (Fernando and McCraw, 1973). In the EA2 challenged birds, histological examination revealed sloughing of the intestinal lining exposing the lamina propria. The intestinal epithelium acts as a selective barrier allowing nutritional ions and macromolecules to be absorbed while resisting harmful pathogens. Once this protective barrier is removed, the exposed lamina propria undergoes morphological changes due to the affects of inflammation and then the villus is unable to adequately absorb nutrients and is subject to secondary infections (Schat, 1991). At the mucosal level, the villus structure may be altered directly by the infectious agent, or indirectly, by the host's immunoinflammatory response (Barker, 1993). Results from the present experiments indicate that the host responds to EA2 in a different manner than EA1 at the level of the duodenal mucosa.

Crypt hyperplasia is a well-known histopathologic consequence of coccidiosis resulting in increased metabolic activity to compensate for epithelial destruction (Rose et al., 1990). In the present experiments, increases observed in intestinal crypt depth were in agreement with results from experiments conducted by Fernando and McCraw (1973). Crypt hyperplasia was found to be present in EA1 challenged birds in all experiments, with the exception of Experiment 3, when compared to controls. Crypt length increased to a maximum at 6 days PC for both challenged groups, whereas no detectable increases in controls were found over the 5 day period after challenge. It appeared that the crypt measurements were inversely related to villus height in primary EA infections and that severe alterations coincided with the heightened period of infection.

Intestinal epithelium has possess three main functions: to absorb essential nutrients and elements from digested food, to act as the host's first line of defense against pathogens, and to replace cells damaged by harmful agents or the digestive process (Yun et al., 2000). New epithelial cells are produced in the intestinal mucosal crypts and migrate in an orderly fashion along the villi to the tips where cells desquamate (Schat, 1991). During infection, this metabolic process could be enhanced to protect the exposed lamina propria and to replace infected or damaged cells. Allen (1983) noted a significant increase in metabolic activity and an increase in lower intestinal lengths in chickens, which support the fact that compensatory gain of body weight does occur during a heavy EA infection. Data from the present study suggest that during infection, the increased crypt depths were directly related to increased replacement or turnover of epithelial cells, which suggest the host's intestinal response mechanism was trying to compensate for the effects of EA infection. These histopathological changes were evident by increases in villus height to crypt depth ratios, which correlate the amount of villus atrophy and crypt hyperplasia during EA infection. Similar responses have reported in chickens (Fernando and McCraw, 1973) and in rats (Symons, 1965). Symons concluded if the crypt production of new cells was slower than the rate of replacement on the villus, sustained stunting of the villus structures could occur and epithelial cell life span could be reduced causing a "flat" mucosa.

It has been well established that many cells are involved in responses to *Eimeria* at the site of invasion including lymphocytes, large mononuclear cells, macrophages, granulocytes, and other leukocyte sub-populations (Rose et al., 1979; Rose, 1982; Jeurissen et al., 1996). However, mast cells have often been excluded from the analysis because they have been thought of as the major effector cells of allergic reactions, but mast cells have other immune functions, which are believed to be independent of IgE antibodies. Although the pivotal role of mast cells in nematode and allergic reactions is well established, the observations presented in this paper suggest that mast cells may also have a role in the induction of specific immune responses to *Eimeria* parasites.

From these results, it is suggested that there was a differential immune response elicited to the two strains of EA. However, the mechanisms responsible for these acute differences are unknown. Arguably, the differential responses could have been due to the parasite itself or the host's reaction to the parasite. Observed changes in mast cell

populations could help explain the differences in the host response. These results, along with data from other investigators, support the role of mast cell involvement in *Eimeria* infections. It appeared that increases in mast cells were related to secretory responses in the intestine, especially those seen in EA2 challenged birds. However, mast cell counts were inconsistent, and counts were highly variable in these experiments. Evaluation of mast cell responses in Experiments 2, 3, and 5 produced no significant differences in mast cell counts between treatments. However, there was a reduced overall presence of mast cell numbers when comparing these results to Experiment 1. In Experiments 1 and 4, increases in mast cells were found to correlate with intestinal morphological damages, epithelial sloughing, and an increase in a secretory response supporting their role in immunological function. Although, in Experiment 2, the EA2 challenged birds exhibited an absence of intestinal lesions, no depression of weight gains, and no observation of infection in challenged birds. These results suggest an inadequate challenge dosage and a subsequent lack of mast cell response. It has been shown that mast cell numbers present are directly proportional to the number of pathogens present (Arock et al., 1998), which could suggest the differential response throughout all experiments due to varying challenge doses given.

Inconsistencies in mast cell counts may be related to the genetic line (Lillehoj, 1988) or the developmental stages of the bird. It has been reported that mast cell numbers increase during the third and fourth weeks of life (Rose et al., 1980). However, it is possible that certain mast cells in these experiments were indistinguishable from other cells due to the preparation technique used. It is known that mast cells vary from one host to another, and unless appropriate fixatives are used, the granules could be dissolved or possibly lose their ability to take up stain (Tung, 1991). Additionally, it is possible that many mast cells may have released their contents prior to or during the fixation of the tissues, and thus did not absorb the stain due to the absence of the granules. Upon observation, mast cell appearance varied in size, shape, and number of granules present, which is suggestive of partial release of mast cell granules. These findings parallel the results found in experiments conducted by Huntley et al. (1985), that evaluated the systemic secretion of mucosal mast cell protease during primary infection to *Eimeria nieschulzi*. The presence of the protease in the blood stream was found within 3 to 6 hours after inoculation in naïve and immune rats. Also, the numbers of mucosal mast cells and presence of the rat protease were at maximal levels 9

days after inoculation. This data suggests that mast cells release their granules shortly after antigenic stimulation, therefore making it difficult to count mast cell numbers during an infective state. Rose et al. (1980) reported an initial decrease in mast cell numbers following primary challenge with EA, but there was no significant difference when compared to controls. However, during secondary infection, the number of mast cells increased within hours of challenge, and an increase in vascular leakage was present only in immunized birds.

It is possible that mast cells were responsible for the secretory response observed in the present experiments, as seen in other animal species. Mast cells are known for their involvement in mammalian intestinal immunity as described in extensive reviews by Metcalfe (1984), Abraham and Arock (1998), and Yong (1997). It was described in these reviews that mast cells are known for their role in Type I hypersensitivities, acute inflammatory reactions mediated by IgE bound to mast cells and basophils. These reactions result from a release of pharmacologically active molecules, which may cause discomfort and distress to the host, but have beneficial functions such as resistance to the pathogen and pathogen elimination. It has been well documented during parasitic infections in mammals that the association of homocytotrophic IgE antibodies and mast cells in the lamina propria result in a change in the microenvironment and produce subsequent intestinal anaphylaxis (Harari et al., 1987; Harari and Castro, 1989). This mechanism is initiated to prevent attachment and penetration by the parasite.

The anaphylactic response is primed by antigen-stimulated mast cells, which release their preformed granules, by exocytosis, to stimulate a wide range of inflammatory responses as well as the synthesis of pharmacologically active substances (Castro et al., 1987). This release of biogenic amines and arachadonic acid metabolites, such as leukotrienes and prostaglandins, promote local smooth muscle contraction, an increase in permeability resulting in localized edema, an increase in mucosal permeability, and intestinal epithelial ion secretion, in particular Cl^-, associated with intestinal anaphylaxis (Harari et al., 1987; Castro et al., 1987). Thus, the apparent anaphylactic-like reaction in EA2 challenged birds could arguably be initiated through mast cell derived products and be part of the host's innate rejection system to the pathogen.

Interestingly, this secretory response was not observed in EA1 challenged birds with the exception of Experiment 4. Upon invasion, mast cell precursors migrate by the blood

stream to the localized area, where they mature and proliferate under the influence of ligands, growth factors, and stimulation from other cells in the localized tissue (Yong, 1997; Abraham and Arock, 1998). However, differences in host response between the two EA isolates could be related to the release of particular mast cell granules, which perhaps caused a change in the intestinal microenvironment. It has been questioned if mast cells, once activated, discharge whole granules, or if there is a fractional release of certain granule contents from a number of different granules (Yong, 1997). While there is known heterogeneity among mast cell populations, they are found to be functionally heterogeneous as well, possibly site specific and have the ability to adapt to their environment, producing secretions that meet the needs of the stimulation involved. This adaptability within tissues and capacity to secrete many different substances is proven by their increased presence in certain tissues, by the variation in staining properties with different dyes, and by the diversity of the sub-structure of their granules (Yong, 1997).

In addition to the possibility of secreting specific inflammatory mediators, it is possible that one EA isolate recruited higher numbers of mast cells due to similar but modified antigenic determinant properties of the invasive sporozoites. This concept was shown to be true in bacterial studies with mouse derived mast cells *in vitro*. It appears that mucosal mast cells have a higher affinity for certain bacteria, upon which they are stimulated. It was conceived that molecules that display binding affinity for structural patterns common to microorganisms are found on the mast cell membrane (Abraham and Arock, 1998).

While there is limited evidence of the role of mast cell products contributing to the pathophysiology of avian infectious diseases, their capacity to inflict damage is clearly significant in other species. Inflammatory responses mediated through the host possibly allow the parasite to utilize the host's resources to aid in its survival. Abraham and Arock (1998) report that successful pathogens evade and resist the host's inflammatory responses to foster their life cycle and to proliferate. This concept could be applied to coccidiosis. It is conceivable that EA may activate mast cells, which contribute to anaphylaxis of the intestine involving excessive fluid and electrolyte secretion resulting in diarrhea. As a consequence, the *Eimeria* is able to pass through the host, virtually unharmed, and disseminate itself throughout the environment, enabling uptake by other hosts.

In conclusion, coccidiosis is a devastating disease that continues to plague the commercial poultry industry. While in-feed medication and newly developed vaccines currently control this disease, the increasing emergence of drug-resistant strains of coccidia urges development of new and improved coccidial vaccines and alternative control strategies. Improvements of effective coccidia vaccines or other means of controlling coccidiosis ultimately depend upon understanding the bird's immune system and its response to parasitic infections. The present experiments reveal that immunovariability does exist within *Eimeria* species due to a differential host intestinal mucosal immune response. This data, while preliminary, suggest the effector involvement of mast cells in coccidial infections which may alter gut morphology as well as aid in conferring protective immunity in broiler chickens. Additional research needs to be completed to fully understand the specific mechanisms that enhance mast cell numbers and subsequent release of their preformed granules. Further identification of the beneficial and harmful mast cell mediators released during parasitic infections will help researchers improve coccidial control strategies and limit the effects of this costly disease.

REFERENCES

Abraham S. N. and M. Arock. 1998. Mast cells and basophils in innate immunity. Immunology. 10:373-381.

Adams, C., H. A. Vahl, and A. Veldman. 1996. Interaction between nutrition and *Eimeria acervulina* infection in broiler chickens: development of an experimental infection model. British Journal of Nutrition. 75:867-873.

Allen, P. C. 1983. Physiological responses of chicken gut tissue to infection with *Eimeria acervulina*. Avian Diseases. 28:868-876.

Brackett, S. and A. Bliznick. 1950. The occurrence and economic importance of coccidiosis in chickens. Lederle Laboratories Division, American Cyanamid Company.

Barker, I. K. 1993. Pathological processes associated with coccidiosis. Pages 81-94 in Sixth International Coccidiosis Conference. Guelph, Canada.

Befus, A. D. 1996. Mast cell heterogeneity and functions in mucosal defenses and pathogenesis. Pages 341-354 in Essentials of Mucosal Immunology. ed. M. F. Kagnoff, H. Kiyono, San Diego, Academic Press.

Biggs, P. M. 1982. The world of poultry disease. Avian Pathology. 11:281-300.

Castro, G. A., Y. Harari, and D. Russell. 1987. Mediators of anaphylaxis-induced ion transport changes in small intestine. American Journal of Physiology. 193:G540-G548.

Chapman, H. D. 1982. Host immune responses. Pages 429-452 in: The Biology of The Coccidia. P. L. Long, University Park Press, Baltimore.

Conaway, D. P., and E. McKenzie. 1991. Poultry coccidiosis: diagnostic and testing procedures. Pfizer Incorporated. Studio Zaba, New York, NY.

Cox, F. E. G. 1998. Control of coccidiosis: lessons from other sporozoa. International Journal for Parasitology. 28:165-179.

Danforth, H. D., and P. C. Augustine. 1989. Coccidia vaccines. Veterinary Protozoan and Hemoparasite Vaccines. Chapter 8:165-175

Danforth, H. D. 1998. Use of live oocyst vaccines in the control of avian coccidiosis: experimental studies and field trials. International Journal for Parasitology. 28:1099-1109.

Daszak, P., S. J. Ball, R. M. Pittilo, C. C. Norton. 1993. Ultrastructural observations on ceacal epithelial cells invaded by first-generation merozoites of *Eimeria tenella in vivo*. Annals of Tropical Medicine and Parasitology. 87:357-364.

Edgar, S. A. 1992. Field diagnosis of coccidiosis in chickens. Agri-Bio Corporation.

Eschenbacher, K. H., P. Eggli, M. Wallach, and R. Braun. 1996. Characterization of a 14kDa oocyst wall protein of *Eimeria tenella and E. acervulina*. Parasitology. 112:169-176.

Fernando, M. A. 1982. Pathology and pathogenicity. Pages 287-327 in The Biology of Coccidia. P. L. Long ed., University Park Press, Baltimore.

Fernando M. A. and B. M. McCraw. 1973. Mucosal morphology and cellular renewal in the intestine of chickens following a single infection of *Eimeria acervulina*. The Journal of Parasitology. 59:493-501.

Graat, E. A. M., A. M. Henken, H. W. Ploeger, J. P. T. M. Noordhuizen, and M. H. Vertommen. 1994. Rate and course of sporulation of oocysts of *Eimeria acervulina* under different environmental conditions. Parasitology. 108:497-502.

Harari, Y., D. A. Russell, and G. A. Castro. 1987. Anaphylaxis-mediated epithelial Cl^- secretion and parasite rejection in rat intestine. Journal of Immunology. 138:1250-1255.

Harari, Y., D. and G. A. Castro. 1989. Simulation of parasite-induced gut-hypersensitivity: implications for vaccination. Immunology. 66:302-307.

Henken, A. M., H. W. Ploeger, E. A. M. Graat, and T. E. Carpenter. 1994a. Description of a simulation model for the population dynamics of *Eimeria acervulina* infection in broilers. Parasitology 108:503-512.

Henken, A. M., E. A. M. Graat, H. W. Ploeger, and T. E. Carpenter. 1994b. Description of a model to simulate effects of *Eimeria acervulina* infection on broiler production. Parasitology. 108:513-518.

Huntley, J. F., G. F. J. Newlands, H. R. P. Miller, M. McLauchlan, M. E. Rose, and P. Hesketh. 1985. Systemic release of mucosal mast cell protease during infection with the intestinal protozoal parasite, *Eimeria nieschulzi*. Studies in normal and nude rats. Parasite Immunology. 7:489-501.

Jeurissen, S. H. M., E. M. Janse, A. N. Vermeulen, L. Vervelde. 1996. *Eimeria tenella* infections in chickens: aspects of host-parasite interaction. Veterinary Immunology and Immunopathology. 54:231-238.

Kheysin, Y. M.. 1972. Life cycles of coccidia of domestic animals. University Park Press.

Lee, M. R. and J. C. H. Shih. 1988. Effect of anaerobic digestion on oocysts of the protozoan *Eimeria tenella*. Applied and Environmental Microbiology. 54:2335-2341.

Lillehoj, H. S. 1988. Influence of inoculation dose, inoculation schedule, chicken age, and host genetics on disease susceptibility and development of resistance to *Eimeria tenella* infection. Avian Diseases. 32:437-444.

Lillehoj, H. S. 1991. Lymphocytes involved in cell-mediated immune responses and methods to assess cell-mediated immunity. Poultry Science. 70:1154-1164.

Lillehoj, H. S. and J. M Trout. 1993. Coccidia: A review of recent advances on immunity and vaccine development. Avian Pathology. 22:3-31.

Lillehoj, H. S. and J. M Trout. 1996. Avian gut-associated lymphoid tissues and intestinal immune responses to *Eimeria* parasites. Clinical Microbiology Reviews. July:349-360.

Lillehoj H. S. and E. P. Lillehoj. 2000. Avian coccidiosis. A review of acquired intestinal immunity and vaccination strategies. Avian Diseases. 44:408-425.

Martin A., S. Awadalla, and H. S. Lillehoj. 1995. Characterization of cell-mediated responses to *Eimeria acervulina* antigens. Avian Diseases. 39:538-547.

Metcalfe, D. D. 1984. Mast cell mediators with emphasis on intestinal mast cells. Annals of Allergy. 53:563-575.

McKenzie M. E., G. L. Colnago, S. R. Lee, and P. L. Long. 1987. Gut stasis in chickens infected with *Eimeria*. Poultry Science. 66:264-269.

McDougald, L. R. and W. M. Reid. 1997. Coccidiosis. Pages 865-883 in Diseases of Poultry, 10th Edition, B. W. Calnek, ed. Iowa State University Press, Ames, IA.

McDougald, L. R., L. P. Joyner, P. L. Long. 1985. Research in Avian Coccidiosis. Proceedings of the Georgia Coccidiosis Conference.

National Research Council. 1994. Nutrient Requirements of Poultry. 9th rev. ed. National Academy Press, Washington, DC.

Ogbuokiri U. D. E. and S. A. Edgar. 1985. Effect of mild infections with six species of *Eimeria* on skin pigmentation of broiler chickens. Poultry Science. 65:1816-1818.

Rose, M. E., P. Hesketh. 1979. Immunity to coccidiosis: T-lymphocyte or B-lymphocyte-deficient animals. Infection and Immunity. 26:630-637.

Rose, M. E., P. Hesketh, and B. M. Ogilvie. 1979. Peripheral blood leukocyte response to coccidial infection: a comparison of the response in rats and chickens and its correlation with resistance to reinfection. Immunology. 36:71-79.

Rose, M. E., B. M. Ogilvie, and J. W. A. Bradley. 1980. Intestinal mast response in rats and chickens to coccidiosis, with some properties of chicken mast cells. International Archives of Allergy and Applied Immunology. 63:21-29.

Rose, M. E. 1982. Host immune responses. Pages 329-371 in The Biology of Coccidia. P. L. Long ed., University Park Press, Baltimore.

Rose, M. E. and P. Hesketh. 1982. Coccidiosis: T-Lymphocyte-dependent effects of Infection with *Eimeria nieschulzi* in rats. Veterinary Immunology and Immunopathology. 3:499-508.

Rose, M. E., A. M. Lawn, and B. J. Millard. 1984. The Effect of immunity on the early events in the life cycle of *Eimeria tenella* in the cecal mucosa of the chicken. Parasitology. 88:199-210.

Rose, M. E. 1987. Immunity to *Eimeria* infections. Veterinary Immunology and Immunopathology. 17:333-343.

Ruff, M. D., D. J. Doran, and G. C. Wilkins. 1981. Effect of aging on survival and Pathogenicity of *Eimeria acervulina*. Avian Diseases. 25:595-599.

Ruff M. D. and G. C. Wilkins. 1984. Intestinal absorption following challenge of immune chicks with *Eimeria acervulina*. Avian Pathology. 13:25-35.

Ruff M. D. 1993. Factors affecting coccidiosis. Pages 73-79 in Sixth International Coccidiosis Conference. Guelph, Canada.

Schat, K. A. 1991. Avian intestinal immunity. Critical Reviews in Poultry Biology. 3:19-34.

Shi, M. Q., S. Huther, E. Burkhardt, H. Zahner. 2000. Immunity in rats against *Eimeria separata*: oocyst excretion, effects on endogenous stages and local tissue response after primary and challenge infections. Parasitology Research. 86:891-898.

Shirley, M.W. 1986. New methods for the identification of species and strains of *Eimeria*. Pages 13-35 in Research in Avian Coccidiosis. McDougald, L. R., L. P. Joyner, P. L. Long, University of Georgia, Athens, Georgia.

Stephens, J. F., W. J. Borst, and B. D. Barnett. 1974. Some physiological effects of *Eimeria acervulina*, *E. brunetti*, and *E. mivati* infections in young chickens. Poultry Science. 53:1735-1742.

Stiff, M. I. and K. W. Bafundo. 1993. Development of immunity in broilers continuously exposed to *eimeria* sp. Avian Diseases. 37:295-301.

Symons, L. E. A. 1965. Kinetics of the epithelial cells, and morphology of villi and crypts in the jejunum of rat infected by the nematode *Nippostrongylus brasiliensis*. Gastroenterology. 49:158-168.

Talebi, A. and G. Mulcahy. 1995. Correlation between Immune Responses and oocysts production in chickens monospecifically infected with *E. maxima*. Avian Pathology 24:485-495.

Tizard, I. R. 2000. Type I hypersensitivity. Pages 307-323 in Veterinary Immunology. I. R. Tizard and R. M. Schubot, W. B. Saunders Company, Philadelphia, Pennsylvania.

Tung, W. 1991. Mast cells in the chick digestive tract II. Fixation, distribution, histochemistry, and ultrastructure. Tokai J. Exp. Clin. Med. 16:27-32.

Uni, Z., D. Sklan, N. Haklay, N. Yonash, and D. Heller. 1995. Response of three class-IV major histocompatability complex haplotypes to *Eimeria acervulina* in meat-type chickens. British Poultry Science. 36:555-561.

Vermeulen, A. N., D. C. Schaap, Th. P. M. Schetters. 2001. Control of coccidiosis in chickens by vaccination. Veterinary Parasitology. 100:13-20.

Williams, R. B. 1996. The ratio of the water and food consumption of chickens and its significance in the chemotherapy of coccidiosis. Veterinary Research Communications. 20:437-447.

Williams, R. B. 1998. Epidemiological aspects of the use of live anticoccidial vaccines for chickens. International Journal for Parasitology. 28:1089-1098.

Williams, R. B. 1999. A Compartmentalized model for the estimation of the cost of coccidiosis to the world's chicken production industry. International Journal for Parasitology. 29:1209-1229.

Yong, L. C. J. 1997. The mast cell: origin, morphology, distribution, and function. Experimental Toxic Pathology. 49:409-424.

Yun, C. H., H. S. Lillehoj, E. P. Lillehoj. 2000. Intestinal immune responses to coccidiosis. Developmental and Comparative Immunology. 24:303-324.

VITA

Bruce Corlise Morris was born on April 2, 1978. He lived in Amelia, Virginia until graduating from Amelia County High School in June of 1996. He attended Virginia Polytechnic Institute and State University where he completed his Bachelor of Science degree in Animal and Poultry Sciences, with a minor in Agricultural and Applied Economics, in May of 2000. He entered the Master of Science program in Animal and Poultry Sciences, Poultry Immunophysiology, at Virginia Polytechnic Institute and State University August of 2000 and will complete his degree in December of 2002. In the summer of 2002, he married Alicia Marie Moyer, in Amelia, Virginia.

_____

Bruce C. Morris