

# Novel technique in treating portal cavernous transformation with portal Biliopathy

Alexander D. Zhang, Michael Bergen

**Funding:** This research did not receive any specific grant from funding agencies in the public, commercial, or not-for-profit sectors.

**Abstract:** We present a case report of a patient who is a non-cirrhotic with portal cavernous transformation secondary to previous trauma. The patient presents with portal biliopathy requiring ERCP/EUS with biliary stenting. The patient was referred to Interventional Radiology (IR) for portal vein recanalization. The patient underwent a novel technique of transplenic access with portal vein recanalization via a gunsight technique, ultimately receiving a direct intrahepatic portocaval shunt (DIPS). Subsequently, his symptoms resolved, and the biliary stent was successfully removed.

**Keywords:** Portal cavernous transformation ■ Portal biliopathy ■ Direct intrahepatic portocaval shunt (DIPS) ■ Transjugular intrahepatic portosystemic shunt (TIPS) ■ Gunsight approach

**Author affiliations:** Alexander D. Zhang VTCOM: 2 Riverside Circle Roanoke, VA 24016; Michael Bergen Carilion Clinic: 1906 Belleview Ave SE, Roanoke, VA 24014

Corresponding author. © 2022 National Medical Association. Published by Elsevier Inc. All rights reserved.

<https://doi.org/10.1016/j.jnma.2022.06.003>

## INTRODUCTION

Cavernous transformation of the portal vein (CTPV) results from long-standing portal vein thrombosis (PVT), which involves the development and dilation of multiple small collateral vessels that develop around the portal vein in the setting of portal hypertension to bypass the occlusion.<sup>1</sup> These are observed in non-cirrhotic livers secondary to extrahepatic portal vein thrombosis. A complication is portal biliopathy or ductopathy, which refers to biliary obstruction from the collateral vessels extrinsically compressing the intrahepatic and extrahepatic bile duct, leading to inflammation and ischemic changes, culminating in peribiliary fibrosis.<sup>2</sup>

## CASE REPORT

A 23-year-old male presented to our institution with portal biliopathy requiring endoscopic retrograde cholangiopancreatography (ERCP) and endoscopic ultrasound (EUS) with biliary stenting. He had a distant history of traumatic pancreatitis that led to the development of non-cirrhotic portal hypertension, hypersplenism, esophageal varices that required esophageal banding five times, and biliary stricture. The patient underwent biliary stenting to

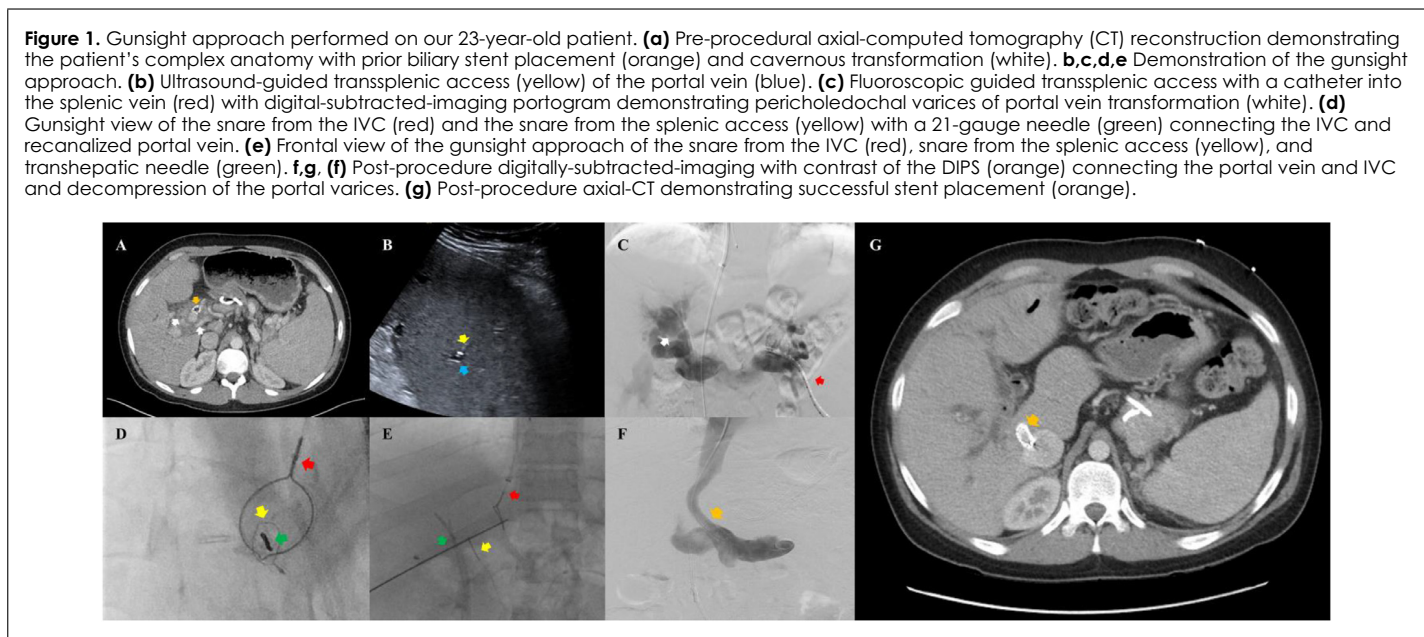
relieve the stricture; however, upon biliary stent removal, the patient had a large volume of hemobilia (Figure 1a). Interventional Radiology (IR) was subsequently consulted for transjugular intrahepatic portosystemic shunt (TIPS) to allow portal decompression. However, due to complex anatomy at play, the team decided to undergo a novel technique of transplenic access with portal vein recanalization via a gunsight technique, with the patient ultimately receiving a direct intrahepatic portosystemic shunt (DIPS). The procedure was done with the support of general anesthesia.

Under ultrasound guidance, the splenic vein was accessed (1b). A catheter was advanced to the portal vein (1c). Next, the right internal jugular vein was accessed under ultrasound guidance, and a catheter was advanced into the supra-hepatic inferior vena cava (IVC). Cone beam computed tomography (CT) was confirmed to verify the placement of the wires. The team then discovered that the patient had variant anatomy where the right hepatic vein was orientated in a superior horizontal position and deemed too distal of a target for a TIPS approach with potential injury to the pericholedochal varices. This discovery led to the decision to connect the IVC and portal vein instead. Snares were deployed in the IVC and the recanalized portal vein and lined in the same plane (1d). Under fluoroscopic guidance, a needle was advanced down the barrel 'gunsight approach' (1d,1e). A guidewire was then advanced from the transhepatic access and snared via the intrajugular access and portal vein access achieving through and through access. Subsequently, a stent was deployed over the wire, connecting the two veins.

Subsequent imaging showed successful stent placement and portal varices decompression (1f).

## DISCUSSION

Primary cavernoma cholangiopathy refers to biliary tract injuries that occur in the setting of extrahepatic portal vein obstruction (EHPVO) with subsequent cavernoma formation and can result as a complication of CTPV. The most common causes of thrombosis and cavernous transformation were neonatal omphalitis (~30.7%), acute destruc-



tive, and chronic indurative pancreatitis (~26%), with blunt abdominal trauma being the rarest (~1.6%).<sup>3</sup> CTPV has been seen in non-cirrhotic and non-tumoral livers and typically presents with gastroesophageal variceal bleeding, hepatosplenomegaly, and development of portosystemic collateral veins.<sup>4</sup> However, diagnosis is made using abdominal ultrasound, color Doppler ultrasonography, multi-phase computed tomography with contrast, and magnetic resonance imaging (MRI). Treatment aims to reduce portal hypertension and resolve the biliary obstruction.<sup>5</sup>

Current recommendations suggest starting anticoagulation (AC) early (low-molecular-weight heparin, unfractionated heparin, or direct oral-anti-coagulants) in patients with acute, noncirrhotic EHPVO given the fact that patients are more likely to be predisposed to hypercoagulability (thrombotic disorder, surgery).<sup>6</sup> Despite this, authors have found that within a 1-year, 38% of patients have recanalization, and 40% had findings consistent with cavernoma and chronic EHPVO.<sup>7</sup>

Given these limitations, TIPS was explored as a potential treatment option in these patients.<sup>8</sup> The TIPS procedure was developed to treat patients with portal hypertension. First introduced in Germany in 1988, the procedure involves artificially creating an intrahepatic central connection between the hepatic vein and the portal vein.<sup>9</sup> While effective in treating the adverse effects of CTPV, the procedure since inception has been complex and technically challenging, requiring some cases to take 6 to 7 hours for the interventional radiologist to complete.<sup>10</sup> The challenge has been gaining access into the portal vein; thus, techniques and 'tricks' have been developed to make this part easier.<sup>11</sup> A variation of TIPS

was introduced in 1996 initially as the gunsight technique, then modified to the DIPS in 2006. The premise of DIPS involves ultrasound-guided percutaneous puncture of the portal vein and the inferior vena cava, followed by a guidewire to connect the two compared with TIPS which involved connecting the hepatic and portal veins.<sup>12</sup> The gunsight technique is a method that allows initial puncture of the portal vein and inferior vena cava. Two snares are used; one is placed in the portal vein and the other in the inferior vena cava under fluoroscopy. The connection is then made by puncturing both snares in the same plane. The communication is then created by retrieving a wire from the IVC and then advancing the catheter from the transjugular approach to be snared from the portal vein access.<sup>13</sup>

EHPVO with PVT is often seen as a relative contraindication to TIPS/DIPs, with CTPV as an absolute contraindication given procedure technical complexity.<sup>14</sup> Additionally, few studies have investigated the efficacy of TIPS in non-cirrhotic patients with EHPVO.<sup>15</sup> The most extensive study of TIPS in non-cirrhotic patients with EHPVO with cavernoma was done by the Knight group of a single-center, retrospective cohort analysis of 39 adult patients evaluated up to 72-months post TIPS. All 39-patients achieved TIPS patency, with 87% patients maintaining patency and clinical improvement. At 72-months, ~50% had maintained primary patency while ~80% maintained patency with additional interventions (angioplasty, stenting),<sup>16</sup> demonstrating TIPS as a viable and effective option in the treatment of CTPV.

In our case, portal recanalization was initially attempted with TIPS; however, we chose a transsplenic access to re-

canalize the portal vein due to the enlarged perichole-  
dochal varix near the intrahepatic branch. A multidisci-  
plinary team discussion between IR, gastroenterology and  
transplant surgery concluded that a DIPS procedure using  
the gunsight approach would allow for better control due  
to the complicated anatomy; the angle from the hepatic  
vein was unfavorable, and there was a hypertrophied cau-  
date lobe to ensure our needle/stent placement was not ex-  
trahepatic and instead went through the liver. With the ad-  
vent of the gunsight approach, the team quickly reassessed  
the situation and used the workaround to recanalize the  
portal vein in the same procedure. A supplemental image  
is attached to show the stent place on CT coursing through  
the liver (1g).

## IMPLICATIONS

Over the past five years, a growing body of literature sup-  
ports using transplenic access to recanalize a chronically  
occluded portal vein, which was once considered a con-  
traindication to a TIPS procedure.<sup>17</sup> Our patient was ex-  
tremely young with a poor prognosis, as there were no  
surgical options offered to him at our institution, and the  
patient was deemed not a transplant candidate due to his  
occluded portal vein. It is important for the IR commu-  
nity to share these novel techniques with our medical  
colleagues to help these patients with limited treatment  
options.

## DECLARATIONS OF INTEREST

None.

## REFERENCES

1. Kauzlaric D, Petrovic M, Barmeir E. Sonography of cavernous transformation of the portal vein. *AJR Am J Roentgenol.* 1984;142(2):383–384. doi:10.2214/ajr.142.2.383.
2. Baskan O, Erol C, Sahingoz Y. Portal biliopathy, magnetic resonance imaging and magnetic resonance cholangiopancreatography findings: a case series. *Gastroenterol Rep.* 2022;4(1):68–72. doi:10.1093/gastro/gou062.
3. Dzidzava I, Kotiv B, Kashkin D, Slobodyanik A, Soldatov S. Surgical shunting of the extrahepatic form of portal hypertension. *HPB.* 2016;18(2):309–310. doi:10.1016/j.hpb.2016.02.796.
4. Kumar A, Sharma P, Arora A. *Alimentary Pharmacology and Therapeutics.* Review article: Portal vein obstruction - Epidemiology, pathogenesis, natural history, prognosis and treatment. Blackwell Publishing Ltd; 2015.
5. Franceschet I, Zanetto A, Ferrarese A, Burra P, Senzolo M. Therapeutic approaches for portal biliopathy: a systematic review. *World J Gastroenterol.* 2016;22:9909–9920.
6. Plessier A, Darwish-Murad S, Hernandez-Guerra M, Consigny Y, Fabris F, Trebicka J, et al. Acute portal vein thrombosis unrelated to cirrhosis: a prospective multicenter follow-up. 2022
7. Amitrano L, Guardascione MA, Menchise A, Martino R, Scaglione M, Giovine S, et al. Safety and efficacy of anticoagulation therapy with low molecular weight heparin for portal vein 2022
8. Abud A, Maddur H, Salem R. Management of symptomatic portal cavernoma cholangiopathy with transplenic portal vein recanalization and transjugular intrahepatic portosystemic shunt. *Hepatology.* 2021;73(1):456–459. doi:10.1002/hep.31411.
9. Richter GM, Noeldge G, Palmaz JC, Roessle M. The transjugular intrahepatic portosystemic stent-shunt (TIPSS): 2022
10. Fidelman N, Kwan SW, LaBerge JM, Gordon RL, Ring EJ, Kerlan RK. The transjugular intrahepatic portosystemic shunt: An update. *Am J Roentgenol.* 2012. doi:10.2214/AJR.12.9101.
11. Saxon RR, Keller FS. Technical aspects of accessing the portal vein during the TIPS procedure. *J Vasc Interv Radiol.* 1997;8:733–744.
12. Peynircioglu B, Shorbagi AI, Balli O, Cil B, Balkanci F, Bayraktar Y. Ultrasound-guided direct intrahepatic portosystemic shunt placement in Budd-Chiari syndrome. *Saudi J Gastroenterol.* 2010;16(4):315–318. doi:10.4103/1319-3767.70633.
13. Ferral H, Bilbao JI. The difficult transjugular intrahepatic portosystemic shunt: alternative techniques and "tips" to successful shunt creation. *Seminars Intervent Radiol.* 2005;22(4):300–308. doi:10.1055/s-2005-925556.
14. Luca A, Miraglia R, Caruso S, Milazzo M, Sapere C, Maruzzelli L, et al. Short-and long-term 2022
15. Lv Y, Li K, He C, Luo B, Zhang B, Liu H, et al. TIPSS for variceal bleeding in patients with idiopathic non-cirrhotic portal hypertension: comparison with patients who have cirrhosis. *Aliment Pharmacol Ther.* 2019;49:926–939.
16. Knight GM, Clark J, Boike JR, Maddur H, Ganger DR, Talwar A, Riaz A, Desai K, Mouli S, Hohlastos E, Garcia Pagan JC, Gabr A, Stein B, Lewandowski R, Thornburg B, Salem R. TIPS for adults without cirrhosis with chronic mesenteric venous thrombosis and EHPVO Refractory to standard-of-CARE therapy. *Hepatology.* 2021;74(5):2735–2744. doi:10.1002/hep.31915.
17. Kallini JR, Gabr A, Kulik L, Ganger D, Lewandowski R, Thornburg B, Salem R. Noncirrhotic complete obliterative portal vein thrombosis: Novel management using trans-splenic transjugular intrahepatic portosystemic shunt with portal vein recanalization. *Hepatology.* 2016;63(4):1387–1390. doi:10.1002/hep.28429.