



Primary Acromioclavicular-Coracoclavicular Reconstruction Using 2 Allografts, TightRope, and Stabilization to the Acromion

Daniel B. Haber, M.D., Petar Golijanin, B.S., Genevra L. Stone, M.D., Anthony Sanchez, B.S., Colin P. Murphy, B.A., Liam A. Peebles, B.A., Connor G. Ziegler, M.D., Jonathan A. Godin, M.D., M.B.A., Jake A. Fox, B.S., and CAPT Matthew T. Provencher, M.D., M.C., U.S.N.R.

Abstract: Acromioclavicular (AC) joint injuries are a common cause of shoulder pain, particularly among young athletes participating in contact sports. Injuries to the AC joint most commonly occur from direct impact at the acromion and are classified as types I to VI. Although most AC joint injuries can be treated nonoperatively, types IV to VI are best treated with surgery, with type III being controversial and most surgeons recommending an initial trial of nonoperative treatment. Although numerous surgical techniques have been described, no gold standard technique has been established. Biomechanical testing suggests that anatomic reconstruction of both the AC and coracoclavicular ligaments results in a superior surgical construct. The objective of this Technical Note is to describe our preferred technique for the primary treatment of AC joint instability in the acute and chronic setting. Using 2 free tendon grafts in combination with a cortical button suspensory device combines the advantages of a nonrigid biologic and anatomic AC and coracoclavicular ligament reconstruction while benefiting from the strength of a cortical suspensory device in resisting displacement of the AC joint.

Injuries to the acromioclavicular (AC) joint are common occurrences in the athletic patient population, with approximately 9% of all shoulder injuries involving the AC joint.¹ The AC joint is a diarthroidal joint, with stability maintained by the coracoacromial (CA) and coracoclavicular (CC) ligaments, shoulder

capsule, and deltoid and trapezius muscles and fascia. AC joint injuries are most commonly caused by a direct lateral impact at the acromion with the arm in an adducted position. Initially, the force drives the acromion inferiorly, while the clavicle remains in its anatomic position. This involves sequential injury beginning with the AC ligaments, extending to the CC ligaments, and finally affecting the deltoid and trapezial muscles and fascia. Severe injuries may also disrupt the deltoid and trapezius muscular attachments. Approximately half of AC joint injuries occur in the third decade of life and most commonly in men.²

Treatment of AC joint injuries depends on the extent of ligament injury, displacement observed, position of clavicle relative to the coracoid, and whether the AC joint can be reduced as classified according to the Rockwood criteria. Type I and II injuries are typically treated nonoperatively owing to partial injury to the AC and/or CC ligaments, whereas type IV to VI injuries are most often treated surgically owing to complete disruption of the AC and CC ligaments leading to instability, pain, and disability.² Treatment of type III injuries remains controversial, with a trend toward nonoperative management and rehabilitation.³⁻⁵ The ISAKOS Terminology Project suggested a revision to

From the Harvard Combined Orthopaedic Residency Program, Massachusetts General Hospital (D.B.H.), and the Beth Israel Deaconess Medical Center (G.L.S.), Boston, Massachusetts; Geisel School of Medicine at Dartmouth (P.G.), Hanover, New Hampshire; The Steadman Philippon Research Institute (A.S., C.P.M., L.A.P., J.A.F., M.T.P.) and The Steadman Clinic (C.G.Z., M.T.P.), Vail, Colorado; and Carilion Clinic Orthopaedics, Virginia Tech Carilion School of Medicine (J.A.G.), Roanoke, Virginia, U.S.A.

The authors report the following potential conflicts of interest or sources of funding: C.P.M. receives support from Arthrex. M.T.P. receives support from Arthrex, JRF Ortho, and SLACK. Full ICMJE author disclosure forms are available for this article online, as [supplementary material](#).

Received May 21, 2018; accepted October 19, 2018.

Address correspondence to Matthew T. Provencher, M.D., The Steadman Philippon Research Institute, The Steadman Clinic, 181 West Meadow Dr, Ste 1000, Vail, CO 81657, U.S.A. E-mail: mprovencher@thesteadmanclinic.com

© 2018 by the Arthroscopy Association of North America. Published by Elsevier. This is an open access article under the CC BY-NC-ND license (<http://creativecommons.org/licenses/by-nc-nd/4.0/>).

2212-6287/18619

<https://doi.org/10.1016/j.eats.2018.10.006>

the Rockwood classification by further subdividing the type III AC joint injuries into type IIIA (stable) and type IIIB (unstable).⁶ Type IIIA injuries are defined as those with no overriding of the clavicle on a cross-body abduction radiograph and with no significant scapular dysfunction, whereas unstable type III injuries demonstrate therapy-resistant scapular dysfunction and persistent pain after 3 to 6 weeks of conservative management with overriding of the clavicle on the cross-body abduction radiograph.

Since the Weaver-Dunn procedure was first described, numerous modifications and new open and arthroscopic techniques have emerged. Despite these many surgical techniques, no gold standard surgical technique is agreed on.⁷⁻⁹ Nevertheless, specific criteria are recommended when treating AC joint dislocations surgically: (1) biologic augmentation, namely, tendon graft, should be used, and (2) anatomic techniques for surgical reconstruction should be favored.⁵ The objective of this Technical Note is to describe an anatomic AC and CC ligament reconstruction technique using 2 tendon grafts, an AC TightRope (Arthrex, Naples, FL), and 2 precontoured Dog Bone Buttons (Arthrex) for primary surgical treatment of symptomatic primary AC joint instability.

Surgical Technique

A narrated video with demonstration of the surgical technique described in the following may be reviewed ([Video 1](#)).

Patient Positioning and Anesthesia

The patient is placed in the supine position on the operating table, and general anesthesia is administered. Single-shot or catheter-infused regional anesthesia may also be provided. The patient is then placed in the beach chair position with care taken to pad all bony prominences. The knees are placed in slight flexion with a soft pad under the popliteal fossa. Moreover, the head and neck positioning should be carefully assessed to ensure neutral position prior to starting the procedure.

The operative extremity is draped free with a well-padded Mayo placed under the elbow. Perioperative antibiotic prophylaxis is administered intravenously prior to incision. All relevant bony anatomy is identified through palpation and marked using a surgical pen. An examination under anesthesia may be performed, followed by shoulder arthroscopy to assess and/or address concomitant shoulder pathology.

Surgical Approach

The open reconstruction is begun with an anteroposterior saber-type incision extending from the coracoid to the posterior aspect of the AC joint. The incision should be centered approximately 2 to 3 cm medial to the AC joint, measuring approximately 6 cm in length ([Fig 1](#)). Subcutaneous full-thickness flaps are

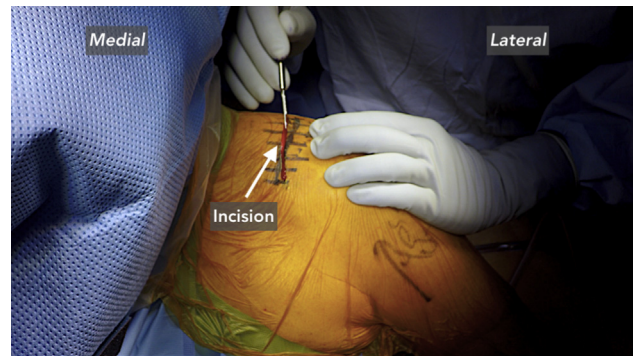


Fig 1. Initial incision. It should be centered approximately 2 to 3 cm medial to the AC joint, measuring approximately 6 cm in length (incision, white arrow). Shoulder in beach chair position.

elevated medially and laterally. Dissection is carried down to the deltotrapezial fascia with a combination of Metzenbaum scissors and needle-tip Bovie (Bovie Medical, Purchase, NY). Meticulous hemostasis should be maintained for good visualization. The deltotrapezial fascia is carefully split in line with the long axis of the clavicle, roughly 90° to the skin incision, and preserved to facilitate a layered closure. Full-thickness, subperiosteal dissection of the distal clavicle and the medial aspect of the acromion is performed, resulting in a skeletonized clavicle and medial acromion. The superior and inferior aspects of the coracoid are also approached and exposed with care using a Metzenbaum scissors. At this time, provisional manual reduction of the AC joint is attempted.

Graft Preparation

Depending on surgeon preference, semitendinosis allograft or autograft, or tibialis anterior allograft may be used. While the initial exposure is performed, an assistant may prepare 2 grafts on a back table. The grafts are prepared such that they fit easily through a 4.5-mm sizing block. Each free end is whip-stitched using a FiberTape (Arthrex) and set aside.

Bone Tunnel Preparation and Suture Passing

Three bone tunnels are needed for this reconstruction—1 in the coracoid, 1 in the clavicle, and 1 in the acromion as well as separate tunnels for the AC TightRope. First, tunnels of the 3.0-mm diameter are drilled for the AC TightRope, consisting of 2 Dog Bone Buttons and a continuous loop of braided ultra-high-molecular-weight polyethylene and polyester No. 5 FiberTape suture. One tunnel is made in the coracoid and another in the clavicle. With Hohmann retractors placed along the inferior aspect of the coracoid, an AC drill guide (Arthrex) is placed on the base of the coracoid, approximately 25 to 30 mm posterior from the anterior tip, which is first measured with a small ruler.

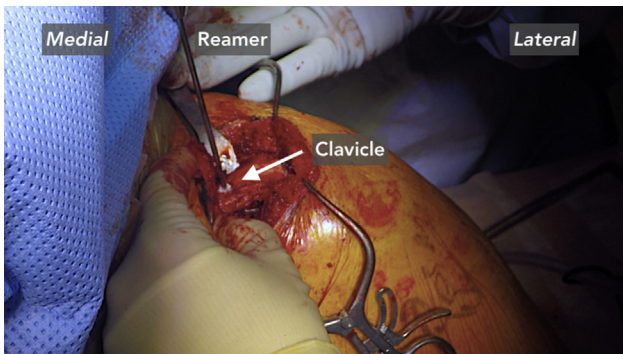


Fig 2. Reaming of superior cortex of the clavicle. A unicortical reamer is placed over a cannulated drill bit to accomplish this (clavicle, white arrow). Shoulder in beach chair position.

This should approximate the anatomic attachment site of the CC ligaments. A 3-mm cannulated drill (Arthrex) is used to drill this tunnel. Once the tunnel is drilled, the cannulated drill bit is left in the bone and the SutureLasso SD Wire Loop (Arthrex) is passed through the cannulated drill bit. The loop is retrieved, and the cannulated drill bit is removed, leaving only the wire in the coracoid tunnel. A passing suture is then passed through the coracoid and snapped for later passage of the AC TightRope.

Next, the AC guide (Arthrex) is positioned on the clavicle, approximately 35 to 40 mm medial to the AC joint and slightly more posterior on the clavicle to recreate the conoid ligament. Using the same 3-mm cannulated drill bit, a tunnel is drilled from superior to inferior, and the drill bit is left in place. A unicortical reamer (Arthrex) is placed over the cannulated drill bit to ream the superior cortex of the clavicle (Fig 2). This functions as a countersink for the suture button. Next, the SutureLasso SD is passed through the cannulated drill bit and the loop is retrieved. The cannulated drill bit is removed, and a passing suture is passed, snapped, and set aside.

A guide pin and a 4.5-mm cannulated reamer (reamer size should match the diameter of the prepared

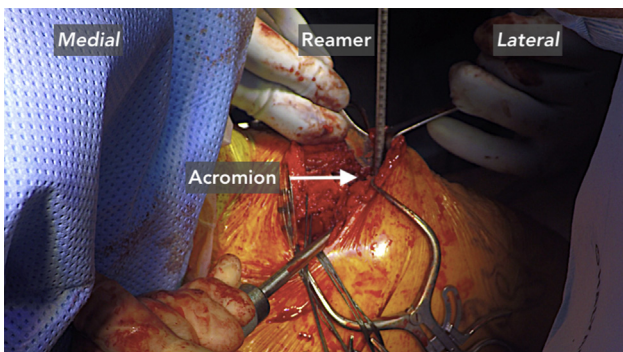


Fig 3. An additional acromial tunnel is drilled (acromion, white arrow). Shoulder in beach chair position.

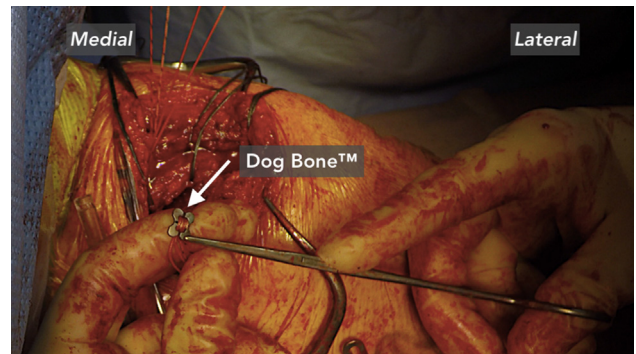


Fig 4. Clavicle reduction. A clavicle Dog Bone Button is loaded to the suture and tensioned securely against the superior clavicle until the clavicle is fully reduced (Dog Bone Button, white arrow). Shoulder in beach chair position.

grafts) are then used to create an additional bone tunnel in the distal clavicle approximately 20 to 25 mm medial to the AC joint (or 15 mm lateral from the first clavicular tunnel). This tunnel should be positioned just anterior to the midline clavicle to match the anatomic position of the trapezoid ligament. Next, the acromion tunnel is drilled with a 4.5-mm drill and guide positioned 10 to 15 mm medial to the AC joint. A large Cobb elevator is used to protect the rotator cuff at all times (Fig 3). Passing sutures are placed through these 2 bone tunnels and snapped. An additional passing suture is passed from superior to inferior along the posterior aspect of the clavicle approximately 45 mm medial to the AC joint and snapped; another is placed around the inferior aspect of the coracoid. These sutures will be used to pass the tendon grafts.

The FiberTape limbs used for the AC TightRope construct are placed into the slots of a Dog Bone Button (precontoured button), ensuring that the concavity of the button will sit flush against the bottom of the coracoid base. All FiberTape limbs are then loaded through the SutureLasso SD Wire Loop and pulled superiorly through the coracoid and clavicle bone tunnels.

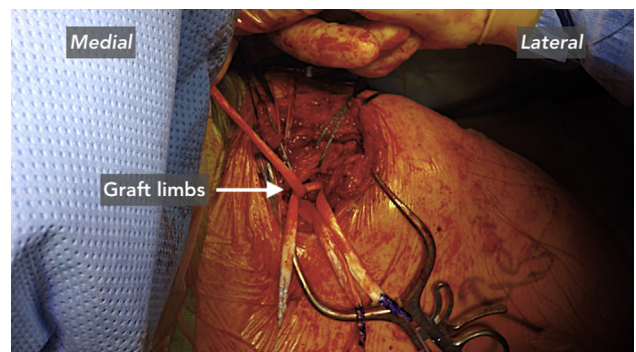


Fig 5. Medial and lateral limbs of the first graft are crossed and sutured to reconstruct the conoid ligament (crossed graft limbs, white arrow). Shoulder in beach chair position.

Table 1. Pearls and Pitfalls

Pearls	Pitfalls
Anatomic placement of bone tunnels is important for anatomic coracoclavicular reconstruction. Note that the conoid (medial-most) tunnel for the Dog Bone Button should be 30 to 45 mm medial from the acromioclavicular joint and on the posterior aspect of the clavicle.	Coracoid fracture may occur if the drill tunnel is too medial or lateral.
The trapezoid (lateral-most) tunnel for graft 1 should be positioned 15 mm lateral from, and more anterior to, the conoid tunnel. This will improve the stability and strength of the construct.	Watch the brachial plexus inferiorly and avoid.
Ensure that the center of the coracoid is drilled independently with a 3.0-mm pin.	Injury to the rotator cuff or humeral head articular surface may occur if the drill plunges deep to the acromion.
Do not resect more than 1 to 2 mm of the distal clavicle to preserve stability.	Injury to neurovascular structures may occur if the drill plunges deep to the clavicle and coracoid. Stability is improved by taking the graft to the acromion.

A hemostat may be used to ensure the coracoid Dog Bone Button is positioned flush on the inferior aspect of the coracoid. The clavicle Dog Bone Button is then loaded to the suture and tensioned securely against the superior clavicle until the clavicle is fully reduced (Fig 4). A Cobb elevator can be used to help reduce the lateral clavicle relative to the acromion, and slight overreduction can be performed as there is an inevitable amount of creep in the system. The suture ends are tied and then cut.

Both grafts are then passed around the inferior aspect of the coracoid using the previously placed passing suture. The lateral aspect of one graft (graft 1) is then passed from inferior to superior around the posterior aspect of the clavicle using the previously placed passing suture. The medial limb of the same is brought around the anterior clavicle. This graft serves to reconstruct the conoid ligament. These 2 limbs are crossed on top of the clavicle, just medial to the Dog Bone Button, and sutured together with FiberTape (Fig 5).

The edges of the distal clavicle are smoothed with a rasp. The lateral limb of the second graft (graft 2) is then passed from inferior to superior through the distal clavicle tunnel previously drilled. This graft serves to reconstruct the trapezoid ligament. The graft is positioned such that two-thirds of the graft is coming through the superior aspect of the clavicle. A 4.75-mm PEEK (polyether ether ketone) interference screw (Arthrex) is then used to secure the graft in the superior clavicle. The long end of the graft is then fed from superior to inferior through the AC joint, creating a soft tissue spacer, and then passed from inferior to superior through the 5 mm acromion bone tunnel. The graft is tensioned, ensuring that the AC joint is appropriately reduced, and an additional 4.75-mm PEEK interference screw is placed in from superior to inferior to secure the graft in the acromion. This, in essence, creates a soft tissue hook plate. The medial limb of graft 2 (conoid ligament graft) is then crossed over the lateral limb and secured atop the acromion by suturing together using FiberTape while maintaining tension on

the limbs. These 2 limbs may then optionally be reinforced in the acromion and clavicle with 3-mm bioabsorbable BioComposite (Poly L-Lactide-co-D acid amorphous copolymer and beta-tricalcium phosphate) PushLock knotless suture anchors (Arthrex). Moreover, the remaining limbs of grafts 1 and 2 can be crossed, tensioned, and sutured together to further reinforce the construct. Reduction is then confirmed with fluoroscopy. The shoulder is checked for impingement and stability as it is taken through a full arc of motion.

Closure

The wound is irrigated and closed. The periosteum and full-thickness deltoid fascia flaps are closed using a nonabsorbable suture in a pants-over-vest fashion, that is to say, a modified horizontal fashion with a watertight closure, which reinforces the construct. The deep dermal layer is closed, followed by the skin layer with Monocryl suture (Ethicon, Somerville, NJ). A sterile dressing is applied, and the patient is placed in a padded abduction sling with elbow support. The pearls and pitfalls associated with the technique are listed in Table 1.

Postoperative Rehabilitation

The patient remains in the padded abduction sling with elbow support for a total of 6 weeks. During this time, the patient is instructed to come out of the sling daily for gentle passive range of motion of the shoulder, elbow, and wrist. Prior to 4 weeks, shoulder passive range of motion is limited to 60° external rotation, 30° abduction, and 90° forward flexion. From 4 to 6 weeks postoperatively, range of motion exercises are used that specifically increase external rotation. Progressive resistance training is permitted 6 weeks after surgery, and the patient is referred to physical therapy. After 4 months, the patient may return to full activities.

Discussion

High-grade AC joint injuries benefit from reconstructive surgery because the clavicle acts as a strut

between the shoulder and thorax and any disruption to this link may alter shoulder position, mechanics, scapular dynamics, and ultimately function over time. In 1972, Weaver and Dunn¹⁰ first described the treatment of AC dislocations through excision of the lateral border of the clavicle and transfer of the CA ligament to the clavicle. However, the technique is reported to fail, in part, because the CA ligament is only 20% as strong as the native CC ligaments and does not anatomically restore the joint.¹⁰ Mazzocca et al.¹¹ performed biomechanical tests, which demonstrated the superiority of an anatomic CC ligament reconstruction over the modified Weaver-Dunn technique. Numerous modifications of the Weaver-Dunn technique and anatomic CC reconstruction have been reported including both open and arthroscopic options.^{7-9,12,13} Despite these efforts, up to 80% of patients following AC reconstruction have been reported to lose radiographic reduction, and between 20% and 30% of patients treated surgically are reported to have complications leading to reoperation.^{14,15} The goal of the presented technique is to use the biomechanical data available to create a construct that minimizes failure and provides anatomic restoration of the AC joint using a reinforced biologic construct.

Tashjian et al.¹⁶ demonstrated good biomechanical results following anatomic CC ligament reconstruction with hamstring allograft alone; however, cyclic loading was found to cause displacement and graft elongation, with the degree to which depending on the method of graft fixation. Beitzel et al.¹⁷ demonstrated that a CC ligament reconstruction using an adjustable loop-length, cortical, suspensory fixation button device provides approximately equal stability to the native CC ligaments when tested for superior displacement. However, although vertical AC joint stability is essential, anteroposterior stability is also important and is thought to be best maintained with an anatomic CC and AC ligament reconstruction.

Using 2 free tendon grafts in combination with a nonabsorbable suture cortical button suspensory device combines the advantages of an anatomic AC and CC ligament reconstruction while benefiting from the strength of the cortical suspensory device, which together resist anteroposterior and superior migration. The free tendon grafts provide a biologic and anatomic reconstruction of the AC, conoid, and trapezoid ligaments, and the cortical button system secures the anatomic reduction in the early stage of bone tendon healing. The articular disc is recreated by soft tissue graft interposition, thus making this an anatomic and biomechanically optimized reconstruction.

We acknowledge numerous limitations to the presented technique. Although we suggest this surgical technique for the treatment of both acute and chronic AC joint instability, future biomechanical and clinical

studies with long-term follow-up are needed to assess outcomes. Proper graft selection is also fundamental to the success of the present technique. We prefer biologic over synthetic grafts as biologic grafts have been reported in the literature to have superior clinical and radiographic outcomes.¹⁸ Moreover, we believe that the use of Dog Bone Buttons to tension the superior clavicle until the clavicle is fully reduced reinforces the reconstruction, further minimizing the risk of loss of reduction and subsequent instability. Finally, there is an increasing interest in treating AC joint dislocations; however, the current literature regarding this pathology and other concomitant injuries does not support any form of treatment over the other.

The described surgical technique results in anatomic reconstruction of the AC joint. The nonrigid fixation restores normal joint kinematics by reconstructing the AC and CC ligaments with allografts, which are then protected by the cortical button suspensory device until graft incorporation takes place and continues to protect against superior migration. This technique is a novel, anatomic, reinforced biologic and nonrigid reconstruction of the AC joint that provides a powerful option to the surgeon to restore both anteroposterior and superior stability of the AC joint.

References

1. Rieser GR, Edwards K, Gould GC, Markert RJ, Goswami T, Rubino LJ. Distal-third clavicle fracture fixation: A biomechanical evaluation of fixation. *J Shoulder Elbow Surg* 2013;22:848-855.
2. Moatshe G, Kruckeberg BM, Chahla J, et al. Acromioclavicular and coracoclavicular ligament reconstruction for acromioclavicular joint instability: A systematic review of clinical and radiographic outcomes. *Arthroscopy* 2018;34:1979-1995.e1978.
3. Korsten K, Gunning AC, Leenen LP. Operative or conservative treatment in patients with Rockwood type III acromioclavicular islocation: A systematic review and update of current literature. *Int Orthop* 2014;38:831-838.
4. Natera Cisneros L, Sarasquete Reiriz J. Unstable acromioclavicular joint injuries: Is there really a difference between surgical management in the acute or chronic setting? *J Orthop* 2017;14:10-18.
5. Beitzel K, Cote MP, Apostolakis J, et al. Current concepts in the treatment of acromioclavicular joint dislocations. *Arthroscopy* 2013;29:387-397.
6. Beitzel K, Mazzocca AD, Bak K, et al. ISAKOS upper extremity committee consensus statement on the need for diversification of the Rockwood classification for acromioclavicular joint injuries. *Arthroscopy* 2014;30:271-278.
7. Torkaman A, Bagherifard A, Mokhatri T, et al. Double-button fixation system for management of acute acromioclavicular joint dislocation. *Arch Bone Joint Surg* 2016;4:41-46.
8. Tiefenboeck TM, Popp D, Boesmueller S, et al. Acromioclavicular joint dislocation treated with Bosworth screw and additional K-wiring: Results after 7.8 years—Still an

- adequate procedure? *BMC Musculoskelet Disord* 2017;18:339.
9. Darabos N, Vlahovic I, Gusic N, Darabos A, Bakota B, Miklic D. Is AC TightRope fixation better than Bosworth screw fixation for minimally invasive operative treatment of Rockwood III AC joint injury? *Injury* 2015;46:S113-S118 (suppl 6).
 10. Weaver JK, Dunn HK. Treatment of acromioclavicular injuries, especially complete acromioclavicular separation. *J Bone Joint Surg Am* 1972;54:1187-1194.
 11. Mazzocca AD, Santangelo SA, Johnson ST, Rios CG, Dumonski ML, Arciero RA. A biomechanical evaluation of an anatomical coracoclavicular ligament reconstruction. *Am J Sports Med* 2006;34:236-246.
 12. DeBerardino TM, Pensak MJ, Ferreira J, Mazzocca AD. Arthroscopic stabilization of acromioclavicular joint dislocation using the AC graft rope system. *J Shoulder Elbow Surg* 2010;19:47-52.
 13. Hegazy G, Safwat H, Seddik M, Al-Shal EA, Al-Sebai I, Negm M. Modified Weaver-Dunn procedure versus the use of semitendinosus autogenous tendon graft for acromioclavicular joint reconstruction. *Open Orthop J* 2016;10:166-178.
 14. Millett PJ, Horan MP, Warth RJ. Two-year outcomes after primary anatomic coracoclavicular ligament reconstruction. *Arthroscopy* 2015;31:1962-1973.
 15. Clavert P, Meyer A, Boyer P, Gastaud O, Barth J, Duparc F. Complication rates and types of failure after arthroscopic acute acromioclavicular dislocation fixation. Prospective multicenter study of 116 cases. *Orthop Traumatol Surg Res* 2015;101:S313-S316.
 16. Tashjian RZ, Southam JD, Clevenger T, Bachus KN. Biomechanical evaluation of graft fixation techniques for acromioclavicular joint reconstructions using coracoclavicular tendon grafts. *J Shoulder Elbow Surg* 2012;21:1573-1579.
 17. Beitzel K, Obopilwe E, Chowaniec DM, et al. Biomechanical comparison of arthroscopic repairs for acromioclavicular joint instability: Suture button systems without biological augmentation. *Am J Sports Med* 2011;39:2218-2225.
 18. Fauci F, Merolla G, Paladini P, Campi F, Porcellini G. Surgical treatment of chronic acromioclavicular dislocation with biologic graft vs synthetic ligament: A prospective randomized comparative study. *J Orthop Traumatol* 2013;14:283-290.