

Echocardiographic Investigation of Canine Myxomatous Mitral Valvular Disease

Sonya R. Wesselowski

Thesis submitted to the faculty of the Virginia Polytechnic Institute and State
University in partial fulfillment of the requirements for the degree of

Master of Science

In

Biomedical & Veterinary Sciences

Michele Borgarelli, Committee Chair

Jonathan A. Abbott

Martha M. Larson

July 8, 2014

Blacksburg, Virginia

Keywords: Canine, Mitral Valve, Echocardiography, Myxomatous, Left Atrial
Volume

Copyright © 2014 by Sonya R. Wesselowski

Echocardiographic Investigation of Canine Myxomatous Mitral Valvular Disease

Sonya R. Wesselowski

ABSTRACT

Objectives: To further characterize the echocardiographic anatomy of the canine mitral valve in healthy dogs and those affected by myxomatous mitral valve disease (MMVD), and to compare the level of agreement between two methods of assessment of left atrial size in identification of left atrial enlargement in dogs with MMVD.

Animals: Sixty dogs with MMVD and 22 normal dogs were prospectively studied with 2-dimensional echocardiography.

Methods: The length (AMVL), width (AMVW) and area (AMVA) of the anterior mitral valve leaflet and the diameter of the mitral valve annulus in systole (MVA_s) and diastole (MVA_d) were measured. Left atrial size was evaluated with the left atrial to aortic root ratio (LA:Ao) and by measuring left atrial volume indexed to body weight (LA Vol/BW). All patients were staged using published ACVIM guidelines and separated into groups B1 and B2/C.

Results: Measurements of AMVL, AMVW, AMVA, MVA_s and MVA_d were all significantly greater in the B2/C group than in the control group. AMVW was significantly greater in group B1 than control. Twelve dogs had left atrial enlargement identified with LA Vol/BW that were considered normal using LA:Ao. Diagnostic disagreement between these two measurements was significant ($P = 0.00012$). The majority of dogs with diagnostic disagreement had concurrent echocardiographic evidence of more advanced mitral regurgitation.

Conclusions: Relative to normal dogs, AMVL, AMVW, AMVA, MVA_s and MVA_d are greater in patients with advanced MMVD. LA Vol/BW may be superior to LA:Ao for identification of mild left atrial enlargement

TABLE OF CONTENTS

List of Figures	v
List of Tables	vi
Preface/Attribution.....	vii
Introduction & Literature Review.....	1
Echocardiographic Anatomy of the Mitral Valve in Healthy Dogs and Dogs with Myxomatous Mitral Valve Disease	9
Discrepancies in Identification of Left Atrial Enlargement using Left Atrial Volume versus Left Atrial-to-Aortic Root Ratio in Dogs.....	26
Conclusions.....	42
References	43

LIST OF FIGURES

1. Echocardiographic anatomy of the mitral valve in healthy dogs and dogs with myxomatous mitral valve disease

Figure 1: 2-Dimensional right parasternal long-axis four chamber view demonstrating the measurement of the anterior mitral valve leaflet length, width, and area. 13

Figure 2: Control group data are presented in scatterplot form. The predicted value for each measurement is depicted by a solid line. Upper and lower 95% prediction intervals are depicted by dashed lines.18

2. Discrepancies in identification of left atrial enlargement using left atrial volume versus left atrial-to-aortic root ratio in dogs

Figure 1: Measurement of left atrial volume using the biplane area-length method: $[0.85 \times A1 \times A2]/L$ 31

Figure 2: Histogram depicting the empirical distribution of LA Vol/BW (ml/kg) in normal dogs.34

Figure 3: Scatterplot showing classification agreement between LA Vol/BW and LA:Ao. 35

LIST OF TABLES

1. Echocardiographic anatomy of the mitral valve in healthy dogs and dogs with myxomatous mitral valve disease

Table 1: % Coefficient of variation (% CV) and Repeatability coefficients (RC) (mm) of mitral valve measurements.	16
Table 2: Normal mitral valve measurements and 95% prediction intervals for dogs of varying weights.	19
Table 3: Mitral valve measurements in 22 healthy dogs (control), 13 dogs in group B1, and 47 dogs in group B2/C.	20

2. Discrepancies in identification of left atrial enlargement using left atrial volume versus left atrial-to-aortic root ratio in dogs

Table 1: Mitral Regurgitation Severity Scoring System (MRSS) Outline.	32
--	----

PREFACE/ATTRIBUTION: The studies presented in this thesis were performed within the Department of Small Animal Clinical Sciences of the Virginia-Maryland Regional College of Veterinary Medicine. Although all individuals who contributed to the projects are represented as authors, Dr. Wesselowski collected all data and authored all components of the thesis. The additional authors listed served roles in statistical analysis, the revision process, or the production of figures and tables.

1. Introduction & Literature Review

Mitral valve anatomy

The mitral valve apparatus is composed of the mitral valve leaflets, chordae tendineae, papillary muscles, and the mitral valve annulus.¹⁻³ The two mitral valve leaflets are structurally distinct from one another and are typically referred to as the anterior and posterior leaflets, however they have also been termed the aortic and mural leaflets, respectively.^{4,5} The anterior leaflet is distinguished by its fibrous continuity with the aortic valve.^{4,6} It is also distinctly broader than the posterior leaflet, with the basal to free edge length being at least twice that of the posterior leaflet in humans.³ The canine anterior mitral valve leaflet is also known to be significantly longer than the posterior leaflet.^{2,5,7} Histologically, the canine mitral valve has four layers.^{6,8} The atrialis and ventricularis are thin layers of endothelial cells that line the atrial and ventricular surface of the valve leaflets, respectively.^{6,8} The fibrosa layer is immediately above the ventricularis layer and is composed of dense collagen and scattered fibroblasts. It is continuous with the mitral valve annulus at the proximal aspect and with the collagen core of the chordae tendineae at the distal aspect.⁸ The final layer is a layer of loose connective tissue rich in proteoglycans and glycosaminoglycans known as the spongiosa.⁶ It lies just beneath the atrialis layer and contains ground substance that embeds a collection of elastic fibers, collagen, fibroblasts and Anichkov's cells.⁶

The chordae tendineae originate from the two left ventricular papillary muscles and insert into the mitral valve leaflets. The chordae provide crucial support to the majority of the valvular tissue and must not be too long or too short, lest inversion of the leaflets or inappropriate leaflet coaptation arise.⁵ Those chordae that branch in a fan-like pattern to insert into the margins of the

commisural tissue between valve leaflets are known as commmisural chordae, while chordae that insert into the valve leaflets themselves can be further classified based on the leaflet into which they insert and the location of insertion on the leaflet.⁹ The total number of chordae tendineae in dogs² is approximately twice the number reported in humans.⁹ It has also been shown that there are a significantly higher number of chordae tendineae attaching to the anterior mitral valve leaflet versus the posterior leaflet in the dog, while the number of chordae originating from each of the papillary muscles is similar.² Each chordae branches between 2 and 5 times.²

The mitral valve annulus provides a fibrous basal attachment for the mitral valve leaflets and also undergoes contraction during systole to help decrease the area that the anterior and posterior leaflets must bridge.³ The geometry of the mitral valve annulus in dogs ranges from elliptical to circular in shape, with no apparent correlation between body weight and annular morphology.² The plane of the mitral valve annulus is oblique in relation to the axis through the ventricular apex due to the slightly apical displacement of the posterior mitral valve leaflet relative to the anterior leaflet.⁵ The mitral valve annulus has been described as saddle shaped in humans, sheep and baboons.¹⁰ It has been proposed that this particular annular shape is conserved across species due to a mechanical benefit that decreases mitral valve leaflet stress.¹⁰ Preliminary data from our laboratory suggest that the canine mitral valve annulus also conforms to the saddle shape.

The echocardiographic anatomy of the normal canine mitral valve has not been well characterized. One study provided the normal thickness, length and area of the anterior mitral valve as well as the systolic diameter of the mitral valve annulus in 7 healthy Norfolk Terriers.¹¹ Another study compared echocardiographic measurements of the normal mitral valve to anatomic measurements obtained post-mortem.² This study found that echocardiographic

measurements of the length of the anterior and posterior mitral valve leaflets did not differ significantly from measurements obtained post-mortem, although echocardiographic measurements of the mitral valve annulus were larger than their corresponding anatomic measurements.² The latter may have reflected shrinkage of the heart after formalin fixation.²

Myxomatous Mitral Valve Disease

Myxomatous mitral valve disease (MMVD) is the most common acquired cardiac disease in dogs and is considered to be the leading cause of congestive heart failure in this species.¹²⁻¹⁴ Gross pathology of affected mitral valve leaflets ranges from mild nodular thickening to severely thickened and prolapsed leaflets with lengthening or rupture of the chordae tendineae.^{15,16} Mitral regurgitation develops as the leaflets fail to properly coapt which, when long-standing, leads to volume overload of the left heart and dilation of the mitral valve annulus⁸. Histopathologic lesions of affected mitral valve leaflets are characterized by an accumulation of glycosaminoglycans and proteoglycans that lead to expansion of the spongiosa layer in combination with connective tissue derangements that cause disruption of the fibrosa layer.^{6-8,16,17} Early lesions are most prominent at the free edge of the valve leaflet, with disease progression leading to more diffuse involvement.⁶

From a clinical standpoint, the prevalence of MMVD increases significantly with increasing age; MMVD most commonly affects male, small breed dogs.¹⁸ The natural history of MMVD in dogs is characterized by a long pre-clinical period.^{14,18} Initially, changes associated with MMVD are only identifiable upon post-mortem examination. Progression of the disease leads to the development of mitral regurgitation, with further deterioration contingent upon the severity and chronicity of this valvular insufficiency. In advanced cases, MMVD-related death

typically occurs due to the development of congestive heart failure.¹⁹ Epidemiologic data suggest that dogs with pre-clinical MMVD have a favorable long-term prognosis, while dogs with moderate or severe heart failure have median survival times of 33 and 9 months, respectively.¹⁹

Diagnosis and staging of canine MMVD often involves a combination of physical examination findings, thoracic radiographs and transthoracic echocardiography. A working group of the American College of Veterinary Internal Medicine has proposed a staging system in which dogs are divided into Stages A through D based on a combination of clinical findings and diagnostic imaging.¹⁸ Stage A encompasses dogs with no current evidence of MMVD that are considered high risk for developing the disease in the future. Stage B represents pre-clinical patients affected by MMVD with substages B1 and B2 reflecting those patients who do or do not have radiographic or echocardiographic evidence of left-sided cardiac remodeling, respectively. Stage C encompasses those patients that have clinical signs as a result of MMVD but importantly, also includes patients that had clinical signs that have resolved in association with therapy. Stage D includes dogs that have developed end-stage, refractory congestive heart failure.

A number of risk factors have been associated with disease progression in dogs with MMVD, with left atrial enlargement frequently identified as one of the most important.¹⁹⁻²¹ Left atrial enlargement serves as an indicator of both the chronicity and severity of mitral valve regurgitation.¹⁹ Multiple echocardiographic methods have been used to quantify left atrial size in both human and veterinary cardiology. Methodologies include assessment of M-mode linear dimensions, 2-dimensional linear dimensions, left atrial areas and left atrial volumes. While the 2-dimensional ratio comparing the diameter of the left atrium to the diameter of the aortic root

remains the most commonly utilized method in veterinary medicine^{22,23}, volumetric assessments of left atrial size have supplanted linear dimensions for quantification of left atrial size in humans.²⁴ The American Society of Echocardiography currently recommends that left atrial size be assessed by obtaining a left atrial volume using either the biplane area-length method or the biplane Simpson's method of discs.²⁵ The biplane area-length method assumes that left atrial geometry can be represented as a prolate ellipse, while the Simpson's method of discs is calculated by dividing the left atrium into a series of stacked discs whose volumes can be calculated individually and summed.²⁵ A recent study suggested that measurement of left atrial volume using the biplane area-length method in dogs was feasible and proposed an upper reference limit of normal left atrial volume indexed to body weight of 0.92 ml/kg.²⁶ The same study identified significant differences in left atrial volume amongst different breeds of dog, however all dogs had an upper 95th percentile left atrial volume indexed to body weight of 1.12 ml/kg or less.²⁶

Other modalities available to measure left atrial volume include real-time 3-dimensional echocardiography, multi-slice computed tomography and cardiac magnetic resonance imaging. Two veterinary studies have compared left atrial volumes derived from real-time 3-dimensional echocardiography to traditional 2-dimensional echocardiography. The first study used Bland-Altman analysis to compare the level of agreement between the left atrial volume obtained with real-time 3-dimensional echocardiography to the 2-dimensional left atrial to aortic root ratio.²⁷ Results suggested that the 3-dimensional measurements underestimated the left atrial volume in comparison to the 2-dimensional ratio at lower values and overestimated at higher values.²⁷ The second study compared several linear measurements of left atrial size to estimate left atrial volume based on geometric assumptions that the left atrium could be considered a sphere and

compared those values to the left atrial volumes obtained using real-time 3-dimensional echocardiography.²⁸ Correlations between the two modalities used in this fashion were weak.²⁸ Correlation of echocardiographically derived left atrial volumes to those obtained with either computed tomography or cardiac magnetic resonance imaging are lacking in veterinary medicine. Many studies investigating these correlations have been performed in humans, however. Data suggest that although there are good correlations among the various imaging modalities, absolute volume differs between modalities, with echocardiographic volumes generally being smaller than volumes obtained with computed tomography or magnetic resonance imaging.^{24,29-32} While the requirement of general anesthesia for either computed tomography or magnetic resonance imaging is a significant limitation for use in veterinary patients, additional studies are warranted to help provide clarification as to how these modalities correlate to the echocardiographic modalities used on a more regular basis in veterinary cardiology.

Additional systematic study is also needed to further characterize the echocardiographic descriptions of canine mitral valves affected by MMVD. Current veterinary literature on this subject is relatively sparse. One study investigated 537 dogs with mitral valve prolapse and found that the most common leaflet exhibiting prolapse was the anterior leaflet (48.4%), with only 7.1% of dogs having prolapse solely involving the posterior leaflet.³³ Bileaflet prolapse was relatively common and was identified in 44.5% of the study population.³³ In human patients with mitral valve prolapse it is the posterior mitral valve leaflet that is most commonly affected.³⁴ In another retrospective study, 189/558 dogs with MMVD for which the description of the affected mitral valve leaflet(s) was available, bileaflet involvement was the most common (55.5%).¹⁹ Only 2.2% of dogs had only the posterior leaflet affected, while 42.3% of dogs had

only anterior leaflet involvement.¹⁹ Finally, a retrospective study investigating the prevalence of chordae tendineae rupture of the mitral valve in dogs with MMVD described a prevalence of chordal rupture of 16.1% in their population of 706 dogs, with the ruptured chord being associated with the anterior mitral valve leaflet in 96.5% of cases.²¹

The lack of objective data available to describe the evolution of the normal canine mitral valve into a valve affected by obvious myxomatous pathology becomes especially problematic when breeding dogs are presented for pre-breeding screening. Differentiation between mild myxomatous degeneration and normal variation is particularly important for accurate diagnosis and appropriate breeding recommendations in this setting. If breeding programs are to be successful in their goal of decreasing the frequency of MMVD within their breeding populations, accurate identification of the early stages of MMVD is required to allow for timely elimination of dogs affected at an early age from the breeding pool.

Objectives & Hypotheses

A prospective, two-pronged study was designed to further characterize the echocardiographic anatomy of the mitral valve and the assessment of left atrial size in normal dogs and dogs with MMVD. The objectives of the first study were: 1) to evaluate the relationships between mitral valve measurements and body size; 2) to propose reference intervals for echocardiographic measurements of the anterior mitral valve leaflet and the mitral valve annulus in normal dogs; 3) to determine which echocardiographic view provides more repeatable measurements of the mitral valve apparatus in dogs, and 4) to compare these echocardiographic measurements among groups of dogs defined by clinical stage of MMVD. Our hypotheses were: 1) that the relationship between mitral valve dimensions and body size would best be described

by the allometric equation and 2) that the length, width and area of the anterior mitral valve leaflet and the diameter of the mitral valve annulus in systole and diastole would be greater in dogs with advanced MMVD than in healthy dogs.

The objectives of the second study were to 1) propose a cut-off for normal left atrial volume by 2-dimensional echocardiographic assessment using the biplane area-length method in normal dogs and 2) to compare the level of agreement in identification of left atrial enlargement between the left atrial-to-aortic root ratio and left atrial volume using the biplane area-length method in dogs with different stages of MMVD. Our hypothesis was that left atrial volume would be superior to the left atrial-to-aortic root ratio in identification of mild left atrial enlargement.

2. Echocardiographic Anatomy of the Mitral Valve in Healthy Dogs and Dogs with Myxomatous Mitral Valve Disease.

a. Title: Echocardiographic Anatomy of the Mitral Valve in Healthy Dogs and Dogs with Myxomatous Mitral Valve Disease.

Authors: S. Wesselowski, DVM, MS^a, M. Borgarelli, DMV, PhD^a, G. Menciotti, DVM^a, and J. Abbott, DVM^a

^a Department of Small Animal Clinical Sciences, Virginia-Maryland Regional College of Veterinary Medicine, Blacksburg, VA 24061

Corresponding author: S. Wesselowski, sonyarw@vt.edu

b. Abstract

Objectives: To further characterize the echocardiographic anatomy of the canine mitral valve apparatus in normal dogs and in dogs affected by myxomatous mitral valve disease (MMVD).

Animals: Twenty-two normal dogs and 60 dogs with MMVD were prospectively studied.

Methods: The length (AMVL), width (AMVW) and area (AMVA) of the anterior mitral valve leaflet were measured in the control group and the affected group, as were the diameters of the mitral valve annulus in diastole (MVA_d) and systole (MVA_s). MMVD patients were staged based on ACVIM guidelines and separated into groups B1 and B2/C. All measurements were indexed to body weight based on empirically defined allometric relationships.

Results: There was a statistically significant relationship between all log₁₀ transformed mitral valve dimensions and body weight. The AMVL, AMVW, AMVA, MVA_d and MVA_s were all significantly greater in the B2/C group compared to the B1 and control groups. AMVW was also significantly greater in the B1 group compared to the control group.

Conclusions: Measurements of the anterior mitral valve leaflet and the mitral valve annulus in the dog can be indexed to body weight based on allometric relationships. Reference intervals have been proposed over a range of body sizes. Relative to normal dogs, AMVL, AMVW, AMVA, MVA_d and MVA_s are greater in patients with advanced MMVD.

Key Words: Canine, anterior leaflet, annulus, reference intervals

Abbreviations:

AMVA	anterior mitral valve leaflet area
AMVL	anterior mitral valve leaflet length
AMVW	anterior mitral valve leaflet width
MMVD	myxomatous mitral valve disease
MVA _d	mitral valve annulus diameter in diastole
MVA _s	mitral valve annulus diameter in systole
RC	repeatability coefficients
% CV	% coefficient of variation

c. Introduction

The most common acquired cardiac disease in canine patients is myxomatous mitral valve disease (MMVD).^{1,2} Gross pathology of affected mitral valve leaflets has a wide spectrum of lesion severity; some dogs develop only mild nodular thickening of the leaflets, while others are found to have lengthening or rupture of the chordae tendineae with elongated and severely thickened leaflets.^{3,4} Dilation of the mitral valve annulus also develops in association with long-standing mitral regurgitation due to MMVD.⁵ Histopathology of affected leaflets shows an accumulation of proteoglycans and

glycosaminoglycans in combination with connective tissue derangements.⁴⁻⁸ Standardized echocardiographic criteria distinguish between normal and abnormal mitral valve morphology in humans, but despite the high prevalence of MMVD in dogs, similar criteria for use in canine echocardiography have not been established.⁹⁻¹¹ The lack of objective echocardiographic criteria has hampered systematic investigation of the relationships between structural mitral valve abnormalities and clinical assessments of disease severity. Additionally, the prognostic relevance of abnormal mitral valve anatomy associated with MMVD in dogs has not been fully evaluated. In humans, mitral valve leaflets measuring 5 mm or greater in width are known to be a predictor of complications associated with MMVD.¹²

The image plane utilized most commonly for evaluation of the mitral valve in human beings, especially with regard to diagnosis of mitral valve prolapse, is the parasternal long axis view. This view corresponds most closely to the veterinary image plane known as the right parasternal long-axis left ventricular outflow view, which allows visualization of the aorta in addition to the left atrium, left ventricle and mitral valve leaflets.¹³ The right parasternal long-axis four-chamber view, though not a standard image plane in human cardiology, is also considered a standard echocardiographic view for assessment of the canine mitral valve.^{7, 13, 14} Both views provide visualization of the mitral valve apparatus, however the optimal image plane for assessment of the mitral valve in dogs has not been critically assessed.

The goals of this study were: 1) to evaluate the relationships between mitral valve measurements and body size; 2) to propose reference intervals for echocardiographic measurements of the anterior mitral valve leaflet and the mitral valve annulus in normal dogs; 3) to determine which echocardiographic view provides more repeatable measurements of the mitral valve apparatus in dogs, and 4) to compare these echocardiographic measurements among groups of dogs defined by clinical stage of MMVD.

d. Materials and Methods

The control group was made up of healthy dogs owned by faculty, staff and students of the Virginia Maryland Regional College of Veterinary Medicine (VMRCVM) as well as dogs presenting for pre-breeding cardiac screening to both the VMRCVM and the Kansas State University Veterinary Teaching Hospital (KSUVTH). These dogs were evaluated with approval of the Virginia Tech Institutional Animal Care and Use Committee and were deemed cardiologically normal based on physical examination, complete echocardiographic evaluation and Doppler^b blood pressure measurement. An ultrasound unit^c equipped with 1.5-10MHz phased array transducers was used to obtain standard M-mode, 2D, and Doppler blood flow measurements with contemporaneous ECG monitoring. Doppler blood pressure measurements were performed compliant with previously published recommendations.¹⁵ Criteria for exclusion included auscultation of a mid-systolic click or left apical systolic murmur, echocardiographic evidence of mitral valve prolapse or MR assessed as greater than trivial in severity, or evidence of cardiovascular or systemic disease expected to affect cardiovascular function.

The study group comprised client-owned dogs that were presented to the VMRCVM Veterinary Teaching Hospital or the KSUVTH for evaluation of MMVD. All dogs had complete echocardiographic evaluation and measurement of Doppler blood pressure. Thoracic radiographs were obtained only if clinically indicated. The diagnosis of MMVD was based on the echocardiographic identification of mitral valve thickening or prolapse, typically in combination with the presence of mitral regurgitation. Dogs were classified according to previously published ACVIM staging guidelines.¹⁶ The distinction between Stage B1 and Stage B2 was based on radiographic and/or echocardiographic findings. Patients for which the vertebral heart scale exceeded 10.5, the echocardiographic left atrial volume indexed to body weight was greater than 1.1 ml/kg¹⁷ or the left ventricular end-diastolic dimension exceeded the upper limit of a published reference interval¹⁸ were classified as Stage B2. Dogs classified as Stage B1 made up one group while Stage B2 and Stage C dogs were grouped together (B2/C) to represent patients with advanced disease and cardiac remodeling. Both the control population and the study population were previously utilized for a separate echocardiographic study.¹⁷

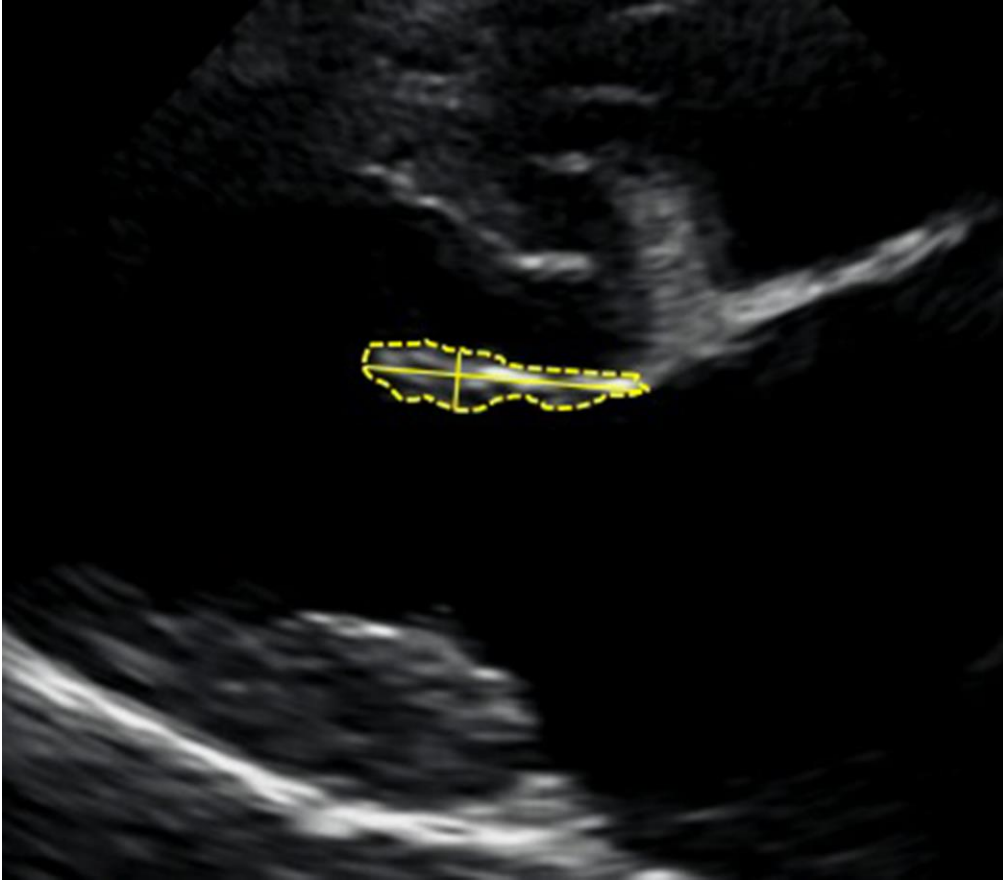

Figure 1: 2-Dimensional right parasternal long-axis four chamber view demonstrating the measurement of the anterior mitral valve leaflet length, width, and area.

Measurements of the mitral valve were obtained in the four-chamber, right parasternal long-axis view and in the right parasternal long-axis left ventricular outflow view. The length (AMVL), width (AMVW) and area (AMVA) of the anterior mitral valve leaflet were measured during diastole, when the leaflet was fully extended (Fig 1). The length of the leaflet was measured as a straight line from the hinge point of the mitral valve annulus to the tip of the extended leaflet. The width was determined by measuring the widest part of the extended leaflet. Finally, the area of the leaflet was obtained using planimetry to trace its border. The mitral valve annulus was measured at both end-diastole (MVA_d) and end-systole (MVA_s) by measuring the distance from mitral valve hinge point to hinge point. The first frame after mitral valve closure and the last frame prior to mitral valve opening defined end-diastole and end-systole, respectively. All measurements were repeated on three consecutive cardiac cycles and

averaged. Average values were used in the statistical analysis. One observer (SW) obtained measurements on all dogs and these data were subject to the principal analyses. Measurements of the same stored images were repeated in a randomly selected subset of six control dogs by SW one week after the initial measurements. A second observer (MB) also obtained measurements from the stored images of those six dogs. These data were used to assess intra-observer and inter-observer repeatability.

e. Statistics

A relationship between mitral valve dimensions and body size was assumed. Therefore, exploratory analyses were used to identify the most appropriate measure of body size with which to index echocardiographic variables. More specifically, simple linear regression was used to evaluate relationships between echocardiographic variables and body-weights of the control group. This procedure was repeated with calculated body surface area serving as the explanatory variable. To explore the possibility of an allometric relationship between mitral valve dimensions and body size, \log_{10} transformed echocardiographic dimensions were regressed against the \log_{10} of body weight. For each variable, goodness of fit, defined by the coefficient of determination (R^2), was greatest for the linear relationship between \log_{10} transformed echocardiographic data and \log_{10} of body weight. The parameters of the regression equation were used to define the terms of the allometric equation: $y=ax^b$ where y is the response variable, a is the proportionality constant, x is body-weight and b is the scaling exponent. For inter-group comparisons, echocardiographic variables were indexed to body weight raised to the scaling exponent defined by the aforementioned allometric relationship.

Intraobserver and interobserver repeatability of variables obtained from the four chamber right parasternal long-axis view and from the right parasternal long-axis left ventricular outflow view were assessed through calculation of the % coefficient of variation (% CV). These values are presented in Table 1. Relative to those obtained from the right parasternal long-axis left ventricular outflow view, values of % CV were consistently lower for variables obtained from the four chamber right parasternal

long-axis view. Additionally, right parasternal left ventricular outflow view images from five patients within the study group were of insufficient quality to obtain all measured variables. Therefore, further analyses were performed only on data obtained from the four chamber right parasternal long-axis image plane.

Intraobserver and interobserver repeatability of variables obtained from the four chamber right parasternal long-axis image plane were further characterized through calculation of repeatability coefficients (RC).^{19,20} Specifically, a mixed linear model that included the fixed effects of observer and time as well as the random effect of dog was developed. Variance components were derived from this model and used to calculate the RC. In some cases, measurement variability attributed to the operator was negligible and generated RC of zero. These data are presented in Table 1.

Predicted values and 95% prediction intervals were derived from the allometric relationship between echocardiographic variables and body-size and from these data, reference intervals for ranges of body-weights were developed. Comparisons between study groups were by one-way analysis of variance for normally distributed data, and by a Kruskal-Wallis analysis of variance for data that were not normally distributed. When these tests disclosed a statistically significant difference between groups, post-hoc evaluation consisted of the Tukey's honest significant different test or Steel-Dwass test as appropriate, based on distribution of data. Normally distributed data are presented as mean (\pm SD) while non-normally distributed are presented as median (range). A p value of <0.05 was considered significant. Distributions of data and residual plots were graphically evaluated to ensure that the assumptions implicit in the use of statistical methods were met.

		Intraobserver		Interobserver	
		RP4	RPLVOT	RP4	RPLVOT
AMVL	CV(%)	3.12	6.25	5.16	14.47
	<i>RC</i>	<i>1.33</i>		<i>0.00</i>	
AMVW	CV(%)	7.67	12.49	29.62	41.62
	<i>RC</i>	<i>0.35</i>		<i>1.28</i>	
AMVA	CV(%)	10.33	13.08	9.99	18.94
	<i>RC</i>	<i>0.00</i>		<i>2.49</i>	
MVA _d	CV(%)	1.65	2.50	5.40	8.35
	<i>RC</i>	<i>0.00</i>		<i>3.72</i>	
MVA _s	CV(%)	0.73	1.46	3.16	13.72
	<i>RC</i>	<i>0.37</i>		<i>1.87</i>	

Table 1: % Coefficient of variation (% CV) and Repeatability coefficients (RC) (mm) of mitral valve measurements. RP4, right parasternal four-chamber view; RPLVOT, right parasternal left ventricular outflow tract view; **Bold values:** % CV; *Italic values:* RC; AMVL, anterior mitral valve length; AMVW, anterior mitral valve width; AMVA, anterior mitral valve area; MVA_d, mitral valve annulus diameter in diastole; MVA_s, mitral valve annulus diameter in systole.

f. Results

Twenty-two cardiologically normal dogs of 12 different breeds were enrolled in the control group. Ten dogs were of mixed breed origin, 2 were beagles, and the remaining 10 breeds were represented by 1 dog each. The mean age of the control group was 4.6 years (\pm 2.0 years) and median weight was 14.25 kg (4-37.1 kg).

Sixty client-owned dogs with MMVD were enrolled in the study group. Twenty-seven breeds were represented, with the most common breeds being Cavalier King Charles Spaniel (n=9), Toy Poodle (n=5), Pomeranian (n=4), Shih Tzu (n=3), Yorkshire Terrier (n=3), and Labrador Retriever (n=3). The median weight of the study group was 9.4 kg (2.5-51.5kg) and the mean age was 10.5 years (\pm 2.7 years). Within the study group there were 13 dogs classified as ACVIM stage B1 and 47 classified as stage B2/C. The mean age of the dogs in group B1 was 8.3 years (\pm 2.5 years) and the mean age of the dogs in group

B2/C was 11.1 years (± 2.5 years), both of which were significantly older than the mean age of dogs in the control group ($p < 0.0001$ and $p < 0.001$, respectively). Group B2/C dogs were also significantly older than those in group B1 ($p = 0.0011$). The median body weight of dogs in group B1 was 17.4 kg (2.5-41.1 kg) and the median body weight of dogs in group B2/C was 7.7 kg (3.5-51.5 kg). There was no significant difference in body weight between the control group and group B1 ($p = 0.67$), whereas body weight of group B2/C was significantly less than the weights of both the control group ($p = 0.027$) and group B1 ($p = 0.028$).

There was a statistically significant relationship between all log transformed mitral valve dimensions and body weight. Coefficients of determination for AMVL, AMVW, AMVA, MVA_d and MVA_s were .87, .93, .93, .93, and .88, respectively. The scaling exponents derived from these allometric relationships were close to the theoretical expectations of 0.33 for linear dimensions and 0.67 for areas; they were, respectively: 0.37, 0.41, 0.78, 0.37 and 0.4 for AMVL, AMVW, AMVA, MVA_d and MVA_s . Figure 2 relates measurements of AMVL, AMVW, AMVA, MVA_d and MVA_s from the control group to body-weight in scatterplot form. Table 2 shows predicted values for each mitral valve measurement for a range of body sizes.

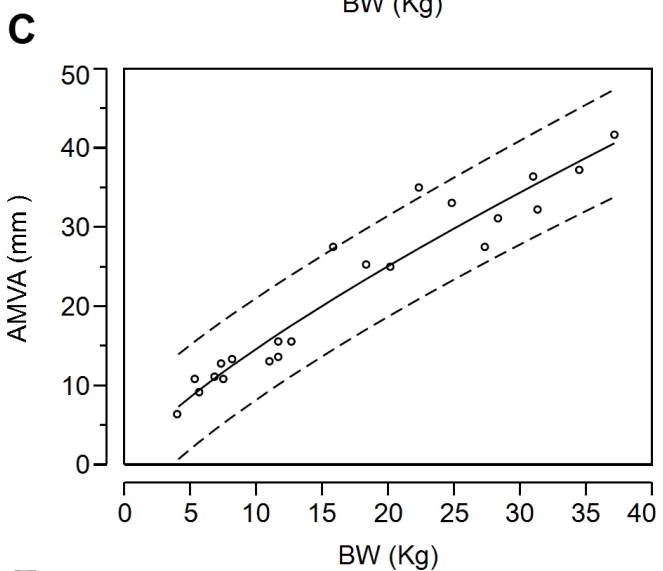
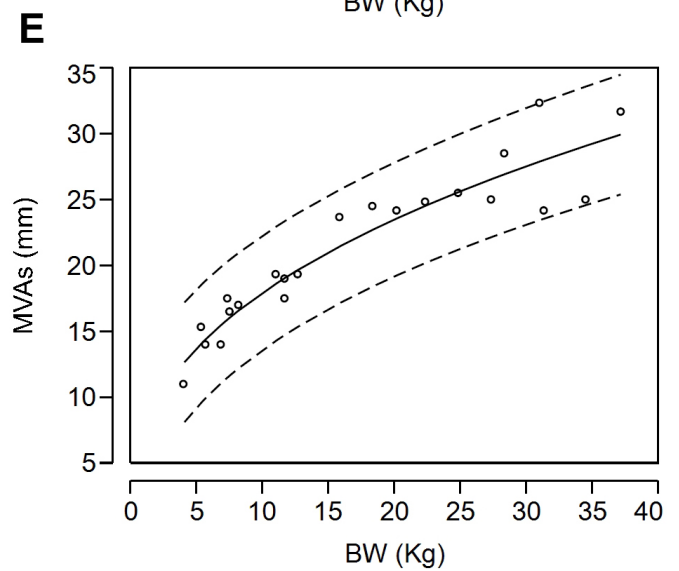
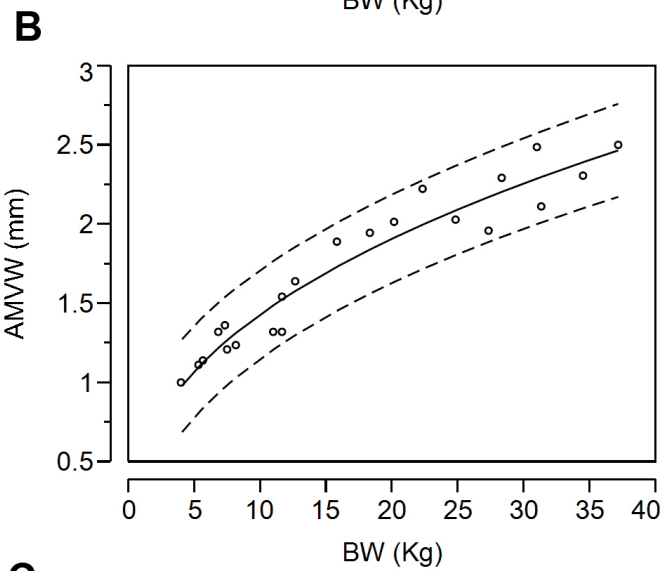
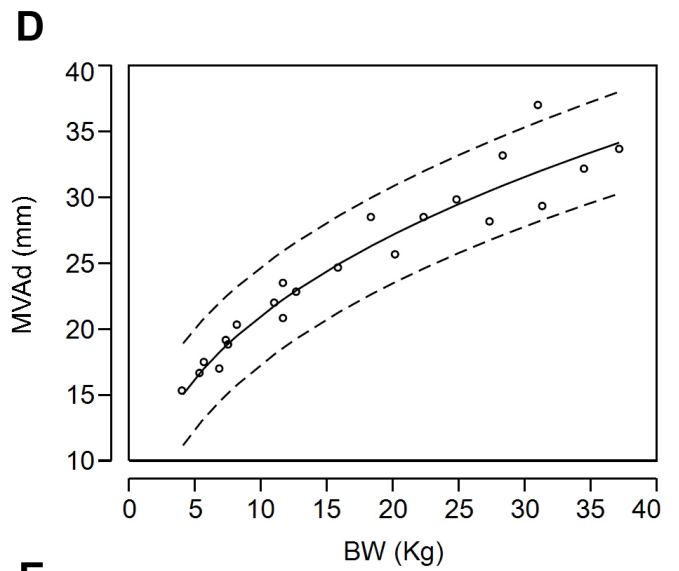
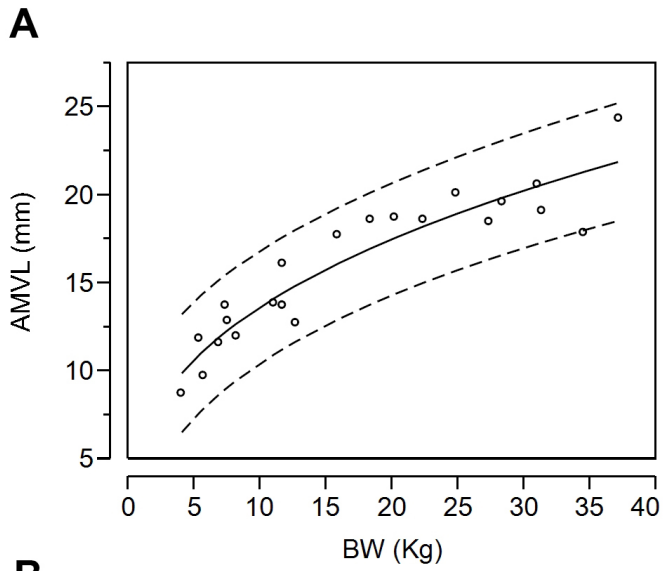


Figure 2: Control group data are presented in scatterplot form. The predicted value for each measurement is depicted by a solid line. Upper and lower 95% prediction intervals are depicted by dashed lines. A: Anterior mitral valve leaflet length (AMVL); B: Anterior mitral valve leaflet width (AMVW); C: Anterior mitral valve leaflet area (AMVA); D: Mitral valve annulus diameter in diastole (MVA_d); E: Mitral valve annulus diameter in systole (MVA_s).

BW (Kg)	AMVL (mm)	AMVW (mm)	AMVA (mm ²)	MVA _d (mm)	MVA _s (mm)
3	8.95 (5.54 - 12.36)	0.87 (0.58 - 1.17)	6.01 (< 12.68*)	13.60 (9.66 - 17.54)	11.41 (6.80 - 16.03)
4	9.90 (6.55 - 13.25)	0.99 (0.69 - 1.28)	7.44 (0.81 - 14.06)	15.11 (11.24 - 18.98)	12.72 (8.18 - 17.26)
6	11.42 (8.14 - 14.70)	1.17 (0.88 - 1.45)	10.08 (3.55 - 16.62)	17.53 (13.75 - 21.31)	14.84 (10.40 - 19.28)
8	12.64 (9.42 - 15.87)	1.31 (1.03 - 1.60)	12.54 (6.07 - 19.01)	19.48 (15.75 - 23.20)	16.56 (12.18 - 20.94)
10	13.69 (10.49 - 16.89)	1.44 (1.16 - 1.72)	14.86 (8.44 - 21.28)	21.14 (17.45 - 24.83)	18.04 (13.70 - 22.38)
12	14.61 (11.43 - 17.79)	1.55 (1.27 - 1.83)	17.08 (10.69 - 23.47)	22.60 (18.93 - 26.27)	19.36 (15.04 - 23.67)
14	15.44 (12.26 - 18.61)	1.65 (1.38 - 1.93)	19.22 (12.85 - 25.59)	23.92 (20.25 - 27.58)	20.54 (16.24 - 24.85)
17	16.55 (13.37 - 19.72)	1.79 (1.51 - 2.07)	22.31 (15.95 - 28.67)	25.69 (22.02 - 29.35)	22.15 (17.84 - 26.45)
20	17.54 (14.35 - 20.73)	1.92 (1.64 - 2.20)	25.28 (18.91 - 31.65)	27.27 (23.59 - 30.94)	23.59 (19.27 - 27.91)
25	19.01 (15.79 - 22.23)	2.10 (1.82 - 2.38)	30.02 (23.59 - 36.46)	29.60 (25.88 - 33.31)	25.73 (21.36 - 30.09)
30	20.30 (17.03 - 23.56)	2.26 (1.98 - 2.55)	34.56 (28.01 - 41.12)	31.65 (27.88 - 35.42)	27.62 (23.19 - 32.05)
35	21.46 (18.14 - 24.78)	2.41 (2.12 - 2.70)	38.94 (32.22 - 45.65)	33.50 (29.67 - 37.33)	29.33 (24.82 - 33.84)
40	22.52 (19.13 - 25.90)	2.55 (2.25 - 2.85)	43.18 (36.27 - 50.08)	35.19 (31.28 - 39.09)	30.90 (26.31 - 35.50)
50	24.41 (20.90 - 27.93)	2.80 (2.49 - 3.10)	51.32 (43.95 - 58.70)	38.20 (34.15 - 42.26)	33.72 (28.94 - 38.50)
60	26.08 (22.43 - 29.73)	3.01 (2.69 - 3.34)	59.12 (51.19 - 67.04)	40.85 (36.64 - 45.07)	36.22 (31.24 - 41.20)

Table 2: Normal mitral valve measurements and 95% prediction intervals for dogs of varying weights. AMVL, anterior mitral valve length;

AMVW, anterior mitral valve width; AMVA, anterior mitral valve area; MVA_d, mitral valve annulus diameter in diastole; MVA_s, mitral valve

annulus diameter in systole. *In dogs weighing 3 kg the lower 95% prediction interval for AMVA was negative in value, thus the range is

represented within the table as < the upper 95% prediction interval.

Comparisons of mitral valve measurements, indexed according to the empirically defined allometric relationship, are summarized in Table 3. The AMVL was significantly longer in the B2/C group compared to both the control group ($p= 0.0086$) and the B1 group ($p= 0.0013$). A significant difference between AMVL from the control group and dogs in stage B1 was not detected ($p= 0.56$). The AMVW was significantly greater in the B2/C group compared to the control group ($p < 0.001$) and the B1 group ($p < 0.001$). Additionally, AMVW from the B1 group was significantly greater than AMVW from the control group ($p= 0.0296$). The AMVA was significantly larger in the B2/C group than the control group ($p < 0.001$) and the B1 group ($p < 0.001$). There was no significant difference between the control group and the B1 group ($p = 0.5959$) with respect to AMVA. MVA_d was significantly greater in the B2/C group than in the control group ($p < 0.001$) or the B1 group ($p < 0.001$), however there was no significant difference between the control group and the B1 group ($p= 0.7333$). Finally, the dimension of the MVA_s was also significantly greater in the B2/C group than the control group ($p < 0.001$) or the B1 group ($p < 0.001$). No significant difference in MVA_s was found between the control group and the B1 group ($p = 0.9721$).

	Control		B1		B2/C	
AMVL/BW ^{0.37}	5.81	(±5.81) ^a	5.51	(±0.80) ^a	6.46	(±0.94)
AMVW/BW ^{0.41}	0.56	(±0.04) ^{b,c}	0.81	(±0.17) ^b	1.29	(±0.34)
AMVA/BW ^{0.78}	2.44	(±0.32) ^b	2.92	(±0.83) ^b	5.13	(±1.74)
MVA_d /BW ^{0.37}	9.01	(±0.52) ^b	8.74	(±1.15) ^b	10.63	(±1.13)
MVA_s /BW ^{0.40}	7.14	(±0.60) ^b	7.08	(±0.71) ^b	8.48	(±1.00)

Table 3: Mitral valve measurements in 22 healthy dogs (control), 13 dogs in group B1, and 47 dogs in group B2/C. Data are presented as mean (±SD). AMVL, anterior mitral valve length; AMVW, anterior mitral valve width; AMVA, anterior mitral valve area; MVA_d , mitral valve annulus diameter in diastole; MVA_s , mitral valve annulus diameter in systole; BW, body weight.

^a = significantly different from B2C ($p < 0.01$)

^b = significantly different from B2C ($p < 0.0001$)

^c = significantly different from B1 ($p < 0.05$)

g. Discussion

The results of this study demonstrate an allometric relationship between mitral valve dimensions and body size. The scaling exponents derived for AMVL, AMVW, MVA_d and MVA_s were all close to the theoretical exponent of 1/3 expected for measurements related to body length, while the exponent derived for AMVA was close to the theoretical exponent of 2/3 for measurements related to BSA. These findings are consistent with data presented in previously published studies of allometric scaling.^{18, 21-24}

We have proposed reference intervals across a range of body sizes that provide the basis of standardized criteria that define the quantitative echocardiographic characteristics of the normal canine mitral valve. Previously published data on the echocardiographic anatomy of the normal mitral valve in dogs are limited to the results of a study in which 7 Norfolk Terriers made up the normal population.²⁵ Additional study is warranted to determine whether breed-specific measurements provide a significant advantage in assessment of the normal mitral valve over the mixed population used to derive the reference intervals presented in this study.

Comparisons between the mitral valve anatomy of the control group and the study groups presented here yielded expected differences. Increases in thickness, length and area of the anterior mitral valve leaflet were evident in more severely affected patients. These echocardiographic changes parallel the classic valvular remodeling reported on gross pathologic examination.³⁻⁵ Additionally, there was an increase in the diameter of the mitral valve annulus in both systole and diastole in patients with more advanced MMVD. Dilation of the mitral valve annulus in the more severely affected dogs in this study is consistent with the expected changes associated with chronic mitral regurgitation, volume overload, and enlargement of the left heart.⁵ All of the increases in each of the five measurements that were studied were significantly different when comparing the control group to the B2/C group with advanced MMVD. The only measurement that showed a significant difference between the control group and the B1 group, however, was AMVW. The lack of echocardiographic change related to the length and area of the

anterior mitral valve leaflet in the B1 group may reflect the fact that more advanced disease is required before significant changes in these parameters can be appreciated echocardiographically, or may relate to an insufficient sample size of the B1 group. Annular dilation, on the other hand, would not be expected in ACVIM Stage B1 patients as this group was defined by the absence of chamber enlargement. Further investigation with a larger study population could help to clarify whether additional echocardiographic valvular changes can be identified when comparing normal dogs to those classified as ACVIM Stage B1. This is particularly relevant to routine screening of breeding dogs, where the ability to definitively identify early echocardiographic valvular changes referable to MMVD is especially important for accurate diagnosis and appropriate breeding recommendations.

Comparison of the % CV between the parasternal long-axis four chamber view and the parasternal long-axis left ventricular outflow tract view in this study suggests that the parasternal long-axis four chamber view should be considered the preferred image plane for quantitative assessment of the mitral valve in the dog. The intraobserver and interobserver repeatability based on % CV were less than 10.4% for all measurements obtained from the parasternal long-axis four chamber view, with the exception of the interobserver repeatability of the AMVW. We suspect this has to do with differences between observers in their choice of delineation between the edge of the valve leaflet and the many chordal attachments to the free edge of the valve. While this may reflect a limitation of this measurement if comparisons are made between observers, the intraobserver repeatability suggests that measurements obtained by the same observer do have value. Additionally, the RC for all measurements performed on the parasternal long-axis four chamber view suggest that minimal variability between measurements was attributable to differences between observers or within the same observer, with more variability attributed to the dog itself or to unexplained factors.

This study has several limitations. Firstly, small sample size may have limited our ability to detect differences between the control group and the B1 group as previously mentioned. Additionally, the small sample size of the control population may have led to wider prediction intervals than those that

could have been derived from investigation of a larger control group. Nonetheless, the data reported here does provide a starting point from which further study can continue to fine tune the echocardiographic delineation between normal and abnormal anatomy of the canine mitral valve.

Repeatability data were obtained by repeated measurements of the same stored image loops, thus the ability of the same observer or a different observer to obtain similar measurements on new images acquired at a different time was not evaluated. Furthermore, images were obtained from standard image planes that included full visualization of the left atrium and left ventricle in addition to the mitral valve itself. Images with a narrowed sector focusing on only the mitral valve itself or images obtained with magnification of the mitral valve may have improved resolution and repeatability.

Finally, the differentiation of valvular thickening attributable to MMVD from that attributable to normal aging remains a significant challenge, with gross and histologic findings ascribed to each group bearing substantial similarities.²⁶ The severity of mitral valve lesions in dogs with MMVD has previously been correlated to increasing age.^{3,27} Indeed, some have proposed that aging itself is likely a part of the pathogenesis of MMVD⁴, though the complex etiology of MMVD in the dog remains unresolved. Within our study groups, age was lowest in the control group and highest in the B2/C group. The AMVW increased sequentially and significantly from the control group to the B1 group, and from the B1 group to the B2/C group. Without an age-matched control group it remains difficult to differentiate the degree of valvular thickening that is attributable to MMVD pathology alone versus that attributable to advancing age. Even with an age-matched control group, histologic study would likely be needed for further clarification, as some dogs that have been deemed normal based on physical exam and echocardiography have been shown to have mild to moderate myxomatous degeneration when examined histologically.²⁸ In normal human hearts, age-related changes in mitral valve thickness has been investigated using autopsy specimens to stratify expected valve width across various age ranges.¹⁰ Similar investigation is warranted in veterinary medicine and could help clarify where to draw the line between normal aging change and true pathology.

In conclusion, measurements of the anterior mitral valve leaflet and the mitral valve annulus in the dog can be indexed to body weight based on the allometric relationship between mitral valve dimensions and body size. Reference intervals have been proposed over a range of body sizes. Relative to normal dogs, the diameter of the mitral valve annulus as well as the thickness, length and area of the anterior mitral valve leaflet are greater in patients with advanced MMVD.

Footnotes

^b811-B, Parks Medical Electronics, Inc, Aloha, OR

^cVivid 7; GE-Medical, Milwaukee, WI

h. References

1. Detweiler DK, Patterson DF. The prevalence and types of cardiovascular disease in dogs. *Ann N Y Acad Sci.* 1965;127:481-516.
2. Borgarelli M, Haggstrom J. Canine degenerative myxomatous mitral valve disease: natural history, clinical presentation and therapy. *Vet Clin North Am Small Anim Pract.* 2010;40:651-663.
3. Whitney JC. Observations on the effect of age on the severity of heart valve lesions in the dog. *Journal of Small Animal Practice.* 1974;15:511-522.
4. Pomerance A, Whitney JC. Heart valve changes common to man and dog: a comparative study. *Cardiovasc Res.* 1970;4:61-66.
5. Buchanan JW. Chronic valvular disease (endocardiosis) in dogs. *Adv Vet Sci Comp Med.* 1977;21:75-106.
6. Han RI, Black A, Culshaw G, French AT, Corcoran BM. Structural and cellular changes in canine myxomatous mitral valve disease: an image analysis study. *J Heart Valve Dis.* 2010;19:60-70.
7. Pedersen HD, Haggstrom J. Mitral valve prolapse in the dog: a model of mitral valve prolapse in man. *Cardiovasc Res.* 2000;47:234-243.
8. Fox PR. Pathology of myxomatous mitral valve disease in the dog. *J Vet Cardiol.* 2012;14:103-126.
9. Babburi H, Oommen R, Brofferio A, Ilercil A, Frater R, Shirani J. Functional anatomy of the normal mitral apparatus: a transthoracic, two-dimensional echocardiographic study. *J Heart Valve Dis.* 2003;12:180-185.
10. Sahasakul Y, Edwards WD, Naessens JM, Tajik AJ. Age-related changes in aortic and mitral valve thickness: implications for two-dimensional echocardiography based on an autopsy study of 200 normal human hearts. *Am J Cardiol.* 1988;62:424-430.
11. Takamoto T, Nitta M, Tsujibayashi T, Taniguchi K, Marumo F. [The prevalence and clinical features of pathologically abnormal mitral valve leaflets (myxomatous mitral valve) in the mitral valve prolapse syndrome: an echocardiographic and pathological comparative study]. *J Cardiol Suppl.* 1991;25:75-86.

12. Bonow RO, Carabello BA, Kanu C, de Leon AC, Jr., Faxon DP, Freed MD, Gaasch WH, Lytle BW, Nishimura RA, O'Gara PT, O'Rourke RA, Otto CM, Shah PM, Shanewise JS, Smith SC, Jr., Jacobs AK, Adams CD, Anderson JL, Antman EM, Fuster V, Halperin JL, Hiratzka LF, Hunt SA, Nishimura R, Page RL, Riegel B. ACC/AHA 2006 guidelines for the management of patients with valvular heart disease: a report of the American College of Cardiology/American Heart Association Task Force on Practice Guidelines (writing committee to revise the 1998 Guidelines for the Management of Patients With Valvular Heart Disease): developed in collaboration with the Society of Cardiovascular Anesthesiologists: endorsed by the Society for Cardiovascular Angiography and Interventions and the Society of Thoracic Surgeons. *Circulation*. 2006;114:e84-231.
13. Boon JA. *Veterinary echocardiography*. 2nd ed. Ames, Iowa, Wiley-Blackwell; 2011.
14. Pedersen HD, Lorentzen KA, Kristensen BO. Observer variation in the two-dimensional echocardiographic evaluation of mitral valve prolapse in dogs. *Veterinary Radiology & Ultrasound*. 1996;37:367-372.
15. Brown S, Atkins C, Bagley R, Carr A, Cowgill L, Davidson M, Egner B, Elliott J, Henik R, Labato M, Littman M, Polzin D, Ross L, Snyder P, Stepien R. Guidelines for the identification, evaluation, and management of systemic hypertension in dogs and cats. *J Vet Intern Med*. 2007;21:542-558.
16. Atkins C, Bonagura J, Ettinger S, Fox P, Gordon S, Haggstrom J, Hamlin R, Keene B, Luis-Fuentes V, Stepien R. Guidelines for the diagnosis and treatment of canine chronic valvular heart disease. *J Vet Intern Med*. 2009;23:1142-1150.
17. Wesselowski S, Borgarelli, M., Bello, N., Abbott, J. Discrepancies in Identification of Left Atrial Enlargement Using Left Atrial Volume versus Left Atrial-to-Aortic Root Ratio in Dogs. *J Vet Intern Med*. 2014;In press.
18. Cornell CC, Kittleson MD, Della Torre P, Haggstrom J, Lombard CW, Pedersen HD, Vollmar A, Wey A. Allometric scaling of M-mode cardiac measurements in normal adult dogs. *J Vet Intern Med*. 2004;18:311-321.
19. Bland JM, Altman DG. Measuring agreement in method comparison studies. *Stat Methods Med Res*. 1999;8:135-160.
20. Pinna GD, Maestri R, Torunski A, Danilowicz-Szymanowicz L, Szwoch M, La Rovere MT, Raczak G. Heart rate variability measures: a fresh look at reliability. *Clin Sci (Lond)*. 2007;113:131-140.
21. Holt JP, Rhode EA, Kines H. Ventricular volumes and body weight in mammals. *Am J Physiol*. 1968;215:704-715.
22. Holt JP, Rhode EA, Holt WW, Kines H. Geometric similarity of aorta, venae cavae, and certain of their branches in mammals. *Am J Physiol*. 1981;241:R100-104.
23. Gutgesell HP, Rembold CM. Growth of the human heart relative to body surface area. *Am J Cardiol*. 1990;65:662-668.
24. Batterham AM, George KP, Whyte G, Sharma S, McKenna W. Scaling cardiac structural data by body dimensions: a review of theory, practice, and problems. *Int J Sports Med*. 1999;20:495-502.
25. Trafny DJ, Freeman LM, Bulmer BJ, MacGregor JM, Rush JE, Meurs KM, Oyama MA. Auscultatory, echocardiographic, biochemical, nutritional, and environmental characteristics of mitral valve disease in Norfolk terriers. *J Vet Cardiol*. 2012;14:261-267.
26. Connell PS, Han RI, Grande-Allen KJ. Differentiating the aging of the mitral valve from human and canine myxomatous degeneration. *J Vet Cardiol*. 2012;14:31-45.
27. Kogure K. Pathology of chronic mitral valvular disease in the dog. *Nihon Juigaku Zasshi*. 1980;42:323-335.
28. Borgarelli M, Tursi M, Rosa GL, Savarino P, Galloni M. Anatomic, histologic, and two-dimensional-echocardiographic evaluation of mitral valve anatomy in dogs. *Am J Vet Res*. 2011;72:1186-1192.

3. Discrepancies in Identification of Left Atrial Enlargement using Left Atrial Volume versus Left Atrial-to-Aortic Root Ratio in Dogs.

a. Title: Discrepancies in Identification of Left Atrial Enlargement Using Left Atrial Volume versus Left Atrial-to-Aortic Root Ratio in Dogs

Authors: S. Wesselowski¹, M. Borgarelli¹, N. M. Bello², and J. Abbott¹

1. Department of Small Animal Clinical Sciences, Virginia-Maryland Regional College of Veterinary Medicine, Blacksburg, VA 24061.

2. Department of Statistics, Kansas State University, Manhattan, KS 66506

Short Title: Echocardiographic left atrial measurement

Key Words: Biplane area-length method, echocardiography, canine, myxomatous mitral valve disease

Abbreviations: 2-D: Two-dimensional; CMR: Cardiac magnetic resonance imaging; LA:Ao: Left atrial to aortic root ratio; LAE: Left atrial enlargement; LA Vol/BSA: Left atrial volume indexed to body surface area; LA Vol/BW: Left atrial volume indexed to body weight; MMVD: Myxomatous mitral valve disease;

MR: Mitral regurgitation; MRSS: Mitral regurgitation severity score; MSCT: Multi-slice computed tomography; RT3D: Real-time three-dimensional; VHS: Vertebral Heart Score

Corresponding author: Sonya Wesselowski, Department of Small Animal Clinical Sciences, Virginia-Maryland Regional College of Veterinary Medicine, 205 Duck Pond Drive, Blacksburg, VA 24061; email: sonyarw@vt.edu

The work was performed at the Veterinary Teaching Hospital at the Virginia-Maryland Regional College of Veterinary Medicine and the Veterinary Teaching Hospital at the Kansas State University College of Veterinary Medicine.

The study was not supported by outside funding.

The study was presented in abstract form at the 2013 ACVIM Forum.

b. Abstract

Background: Left atrial size is prognostically important in dogs with myxomatous mitral valve disease (MMVD).

Hypothesis/Objectives: To compare the level of agreement in identification of left atrial enlargement (LAE) between the left atrial-to-aortic root ratio (LA:Ao) and left atrial volume using the biplane area-length method indexed to body weight (LA Vol/BW).

Animals: Sixty dogs with MMVD and 22 normal dogs were prospectively studied with 2-dimensional (2-D) echocardiography.

Methods: The upper limit of normal for LA Vol/BW was defined as 1.1 ml/kg. LA:Ao was deemed normal if ≤ 1.5 . To define overall disease severity, each dog was assigned a mitral regurgitation severity score (MRSS) based on echocardiographic parameters that did not include left atrial size. ACVIM staging also was utilized.

Results: Of 60 affected dogs, 20 were ACVIM Stage B1, 25 were Stage B2 and 15 were Stage C. LA Vol/BW identified LAE in 12 cases in which LA:Ao was normal; 7 of these were Stage B1 and 5 were Stage B2. This diagnostic disagreement was significant ($P=0.00012$). Of the 12 cases in which diagnostic discrepancies were identified, 5/5 of the B2 dogs and 3/7 B1 dogs had a moderate MRSS whereas 4/7 B1 dogs had a mild MRSS. No diagnostic discrepancies between LA:Ao and LA Vol/BW were apparent in dogs with a severe MRSS.

Conclusions and clinical importance: This study shows evidence of diagnostic disagreement between LA:Ao and LA Vol/BW for assessment of LAE. LA Vol/BW may be superior to LA:Ao for identification of mild LAE.

c. Introduction

Myxomatous mitral valve disease (MMVD) is the most common acquired heart disease in dogs.^{1,2} Typically, MMVD is slowly progressive, and many affected dogs never develop congestive heart failure.³ One of the most important predictors of progression of MMVD is increased left atrial size.^{3,4} The degree of left atrial enlargement (LAE) is reflective of both the chronicity and severity of mitral regurgitation (MR).³

Given the prognostic relevance of LAE, it is important to determine which of methods used to assess left atrial size is most useful in the clinical evaluation of patients with MMVD. Currently, the most commonly used method to quantify left atrial size in veterinary medicine is the 2-dimensional (2-D) left atrial-to-aortic root ratio (LA:Ao), which provides a body weight-independent measurement of left atrial size.^{5,6} An alternative method for assessing left atrial size is measurement of left atrial volume. Volumetric assessments are based on dimensions obtained from multiple planes and may detect chamber enlargement with greater sensitivity than the LA:Ao, which is determined by a single linear atrial dimension. In human medicine, there has been a paradigm shift in the assessment of the left atrium, such that left atrial volume has become the standard for assessment of left atrial size, whereas linear dimensions used for quantification of left atrial size have fallen out of favor.⁷

In addition to 2-D echocardiography, real-time 3-dimensional (RT3D) echocardiography, cardiac magnetic resonance imaging (CMR), and multi-slice computed tomography (MSCT) also have been investigated for their utility in measuring left atrial volume. Although there appears to be good correlation among the various imaging techniques, absolute volume differs by technique, with volumes measured by echocardiographic methods generally being smaller than volumes obtained with CMR or MSCT.⁷⁻¹³ In veterinary patients, the requirement of general anesthesia for either MSCT or CMR imaging is an important drawback, especially for patients with advanced or decompensated cardiovascular disease. Although these imaging modalities may provide a more accurate assessment of left atrial volume, the risks associated with anesthesia may outweigh the benefit.

If left atrial volume assessed by 2-D echocardiography were to be superior to LA:Ao in predicting clinical status or assessing the severity of MR, it could improve ability to accurately gauge long-term prognosis at presentation. The use of left atrial volume derived from 2-D echocardiographic dimensions to assess left atrial size in dogs with MMVD has not been investigated extensively. A recent study suggested 0.92 ml/kg as the upper limit of normal for left atrial volume obtained by the biplane area-length method indexed to body weight.¹⁴

The aims of this study were: 1) to propose a cut-off for normal left atrial volume by 2-D echocardiographic assessment using the biplane area-length method in normal dogs and 2) to compare the level of agreement in identification of LAE between LA:Ao and left atrial volume using the biplane area-length method in dogs with different stages of MMVD. Our hypothesis was that left atrial volume would be superior to LA:Ao in identification of mild LAE.

d. Materials and Methods

Healthy dogs owned by faculty, staff and students of Virginia Maryland Regional College of Veterinary Medicine (VMRCVM) and healthy dogs presented for pre-breeding cardiac screening to both the VMRCVM and the Kansas State University Veterinary Teaching Hospital (KSUVTH) made up the control group. Each of these dogs was judged to have normal cardiovascular status based on physical examination, Doppler blood pressure measurement^a and complete echocardiographic examination. Evaluations were performed with approval of the Virginia Tech Institutional Animal Care and Use Committee. Doppler blood pressure measurements were performed in accordance with published recommendations.¹⁵ Standard M-mode, 2D, and Doppler blood flow measurements were performed with continuous ECG monitoring in right and left lateral recumbency using an ultrasound unit^b equipped with 1.5-10 MHz phased array transducers. Exclusion criteria included the presence of a left apical systolic heart murmur or mid-systolic click on physical examination, more than trivial MR or mitral valve prolapse identified by echocardiography, or any evidence of cardiovascular or systemic disease expected to affect cardiovascular function.

The study group comprised client-owned dogs presented to the VMRCVM Veterinary Teaching Hospital or the KSUVTH for evaluation of MMVD. All patients had complete echocardiographic evaluation and measurement of Doppler blood pressure. Thoracic radiographs were obtained if clinically indicated. The diagnosis of MMVD was based on the echocardiographic identification of mitral valve thickening or prolapse, typically in combination with the presence of MR.

In all dogs, left atrial volume was calculated using the biplane area-length method¹⁶ from the left apical 2- and 4-chamber views (Figure 1) at the end of ventricular systole. End-systole was defined as the frame immediately preceding opening of the mitral valve. Briefly, the endocardial border of the left atrium was traced to obtain atrial areas in both the left apical 4-chamber (A1) and 2-chamber (A2) views. The left auricular appendage and the confluence of the pulmonary veins were excluded, and the boundary of the left atrium and left ventricle was delineated by a straight line drawn from hinge point to hinge point across the mitral valve annulus. The length of the left atrium (L) was defined as the perpendicular distance from the mid-point of the delineation between atrium and ventricle to the dorsal aspect of the left atrial wall on the left apical 4-chamber view. Left atrial volume was calculated using the equation: $[0.85 \times A1 \times A2]/L$ and was indexed to both body weight and body surface area.¹⁶ All measurements were repeated on 3 consecutive cardiac cycles and averaged. Average values were used in the statistical analysis. The LA:Ao was measured as previously reported⁵ and expressed as the average of 3 consecutive measurements. One operator (SW) conducted measurements on all dogs. In addition, the images from a randomly selected subset of 6 control dogs were measured again by operator SW 1 week after the original measurements and also by a second operator (MB). These data then were used to assess intra-operator repeatability (i.e. within-operator variability) and inter-operator reproducibility (i.e. between-operator variability) of the area-length method.

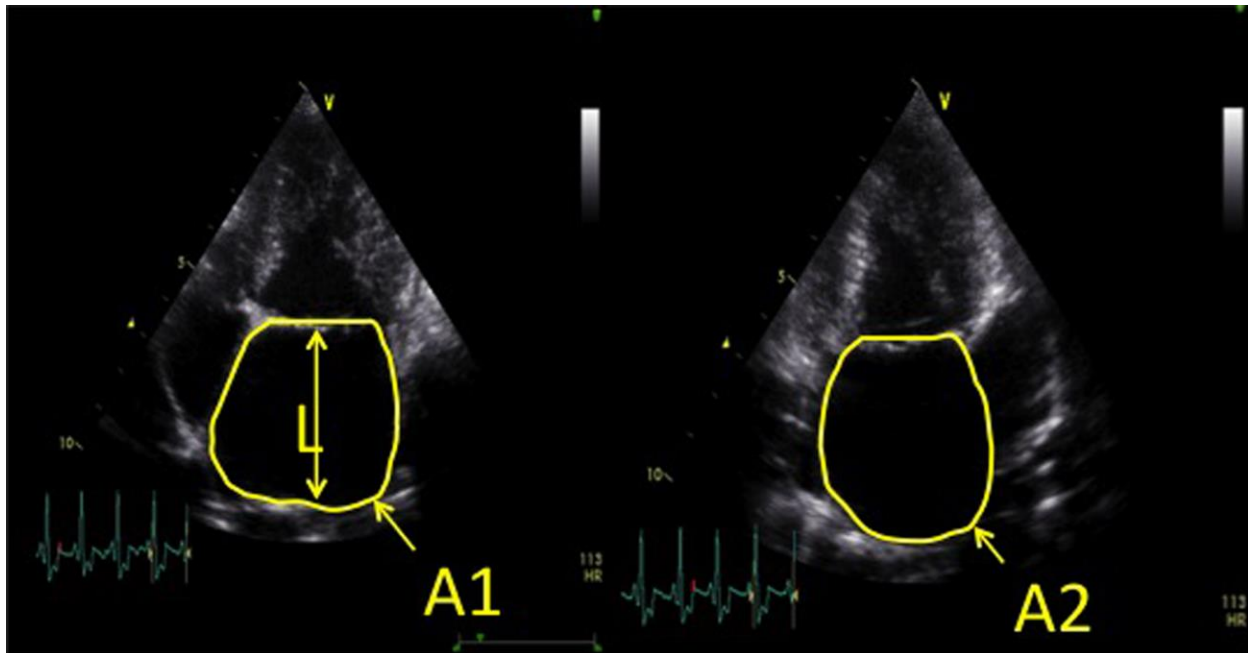


Figure 1: Measurement of left atrial volume using the biplane area-length method: $[0.85 \times A1 \times A2]/L$. A1, left atrial area from apical 4 chambers view; A2, left atrial area from 2 chamber view; L, length of left atrium.

All patients were classified based on the ACVIM staging system¹⁷. Specifically, Stage B1 dogs were defined as asymptomatic patients with vertebral heart score (VHS) < 10.5 , LA:Ao < 1.5 and normal left ventricular end-diastolic dimensions based on previously published reference intervals,¹⁸ whereas Stage B2 dogs were defined as asymptomatic patients with either VHS > 10.5 or echocardiographic evidence of increased left ventricular end-diastolic dimensions or LA:Ao > 1.5 . Patients also were classified based on our own echocardiographically-derived mitral regurgitation severity scoring system (outlined in Table 1) to assess overall disease severity using parameters other than left atrial size. The chosen parameters have been utilized previously for assessment of the severity of MR and included the area of the regurgitant jet assessed with color Doppler^{19,20}, the peak velocity of the transmitral E wave^{3,21}, left ventricular internal dimension at end-diastole²², the anatomy of the mitral valve leaflets^{3,23}, and the density of the continuous wave Doppler MR signal²⁴. Individual scores assigned for each of the echocardiographic parameters were summed to obtain the mitral regurgitation severity score (MRSS). Although based on established echocardiographic parameters, this composite measure of disease severity

has not been clinically validated in veterinary patients. The scores are presented only to provide additional descriptive data related to the severity of MMVD.

Echocardiographic Parameter	Normal	Mild	Moderate	Severe
Color Doppler Regurgitant Jet Area	None, or trivial (0)	< 20% of left atrial area (1)	20-40% of left atrial area (2)	>40% of left atrial area (3)
Mitral Inflow	E wave <1.2m/sec (1)	E wave < 1.2 m/sec (1)	E wave >1.2 m/sec with E wave deceleration time > 80msec (2)	E wave >1.2 m/sec with E wave deceleration time < 80 msec (3)
Left ventricular internal dimension in diastole	Normal (1)	Normal (1)	Enlarged (<20% over upper reference limit for body weight) (2)	Enlarged (>20% over upper reference limit for body weight) (3)
Leaflet Anatomy	Normal (1)	Normal (1) or mitral valve prolapse seen in 2 views (2)	Normal (1) or mitral valve prolapse seen in 2 views (2)	Flail leaflet (3)
Continuous wave Doppler mitral regurgitation jet density	None (0)	Incomplete/faint (1)	Dense (2)	Dense (2)
Score Ranges	3	4 to 7	8 to 11	12 to 14

Table 1: Mitral Regurgitation Severity Scoring System (MRSS) Outline. Numbers in parenthesis represent the assigned scores for each echocardiographic parameter.

e. Statistical Analyses

A multiclass ROC analysis was conducted to estimate the multiclass area under the curve (AUC) and to classify the MRSS based on either LA:Ao, LA volume indexed to body weight (LA Vol/BW) or

LA volume indexed to body surface area (LA Vol/BSA). An estimate of the multiclass AUC provides a measure of classification performance for each of the selected predictors to accurately separate the 4 classes of the MRSS (normal, mild, moderate and severe). The estimated multiclass AUC for LA:Ao was 87.6%, for LA Vol/BW was 91.9% and for LA Vol/BSA was 87.0%. Although these AUC estimates show similar numerical magnitudes, no formal testing was conducted because statistical approaches to multiclass classification problems represents an active area of research for which the development and validation of statistical methodologies is on-going. For the purpose of this study, LA:Ao was considered the reference standard and further comparisons were conducted using LA Vol/BW, which showed the best classification performance of the 2 LA volumetric assessments.

Patients were classified as having either a normal or enlarged left atrium based on LA:Ao and LA Vol/BW. For LA:Ao, the accepted clinical threshold of $1.5^{4,25}$ was utilized as the upper limit and cut-off between normal left atrial size and LAE. For LA Vol/BW, the empirical distribution of LA Vol/BW in the control group was evaluated to determine an upper normal threshold and cut-off between normal left atrial size and LAE. Classification agreement for LAE between LA:Ao and LA Vol/BW was evaluated using a McNemar test of symmetry for 2x2 frequency tables.

A linear mixed model approach was used to quantify sources of random variability in the assessment of LA Vol/BW. The statistical model included random effects for patient, operator and residual; the latter 2 terms allowed for assessment of between-operator reproducibility and within-operator repeatability, respectively, following a standard gauge repeatability and reproducibility (GR&R) approach.²⁶

f. Results

Twenty-two dogs with normal cardiovascular status of 12 different breeds were enrolled in the control group. Ten dogs were of mixed breed origin, 2 were beagles, and the remaining 10 breeds were represented by 1 dog each. The mean age of the control group was 4.6 years (range, 1.5-8.2 years) and mean weight was 17.4 kg (range, 4-37.1 kg).

Sixty client-owned dogs with MMVD were enrolled in the study group. Twenty-seven breeds were represented, with the most common breeds being Cavalier King Charles Spaniel (n=9), Toy Poodle (n=5), Pomeranian (n=4), Shih Tzu (n=3), Yorkshire Terrier (n=3), and Labrador Retriever (n=3). The mean age of this group was 10.5 years (range, 5.4-19.5 years) and mean weight was 13.7 kg (range, 3.5-51.5 kg). On average, animals in the study group were older than those in the control group ($P<0.0001$), whereas there was no evidence for differences in body weight between the groups ($P=0.19$). Within the study group there were 20 dogs classified as ACVIM stage B1, 25 classified as stage B2 and 15 classified as stage C. Of the 25 dogs classified as stage B2, 23 dogs were identified as having left heart enlargement based on echocardiographic parameters and 2 dogs were identified as having left heart enlargement based on radiographic parameters. The 2 dogs with radiographic enlargement included a Cavalier King Charles Spaniel with a VHS of 11.9 and a Shih Tzu with a VHS of 10.9. Seventeen of the study group patients had a mild MRSS, 20 patients had moderate scores and 13 had severe MRSS scores.

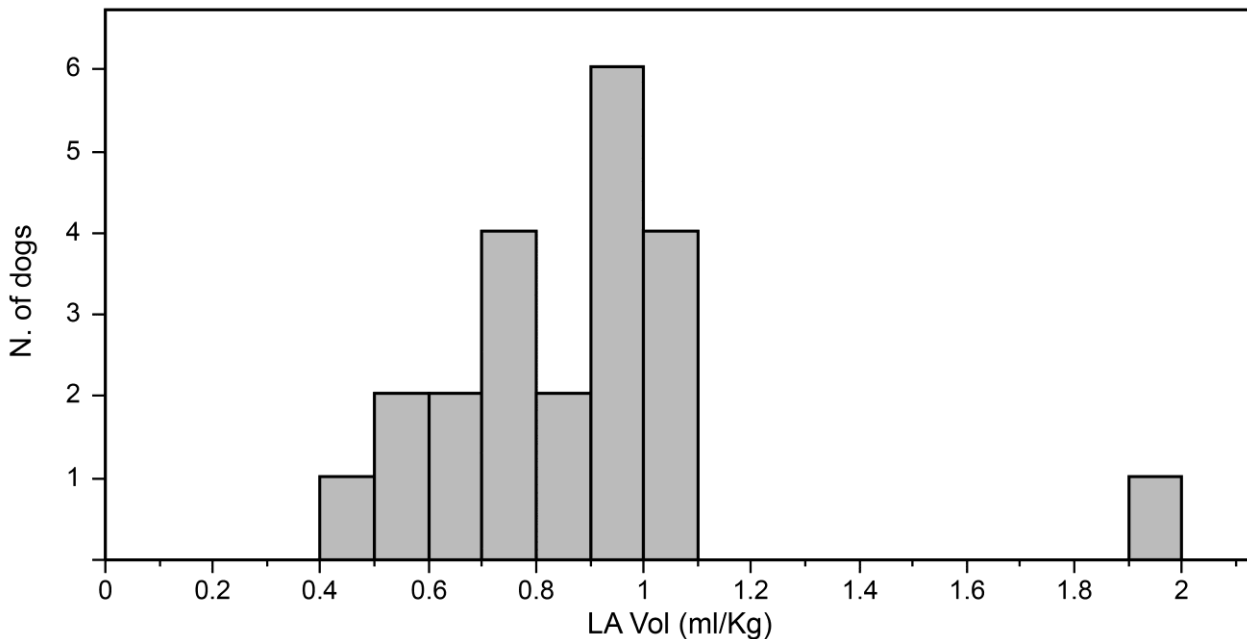


Figure 2: Histogram depicting the empirical distribution of LA Vol/BW (ml/kg) in normal dogs.

The empirical distribution of LA Vol/BW in the control group is summarized in the histogram presented in Figure 2. The mean LA Vol/BW of the control group was 0.88 ml/kg, and the median was 0.89 ml/kg. The 95th percentile value of LA Vol/BW was 1.07 ml/kg; this also was the second-to-last

largest observed value. Thus, a cut-off of 1.1 ml/kg (after rounding) was set as a reasonable upper working limit LA Vol/BW in normal dogs. Based on this cut-off, LA Vol/BW identified LAE in 12 patients in the study group in which LA:Ao was considered normal. The diagnostic disagreement between LA:Ao and LA Vol/BW for identification of LAE was significant ($P= 0.00012$), as illustrated by the scatterplot in Figure 3. Of the 12 patients with discrepant diagnoses, 7 were ACVIM stage B1 and 5 were stage B2. Three of the stage B2 patients were classified as such based on increased echocardiographic left ventricular dimensions, whereas 2 of them had been identified as having cardiomegaly radiographically but had a normal LA:Ao and normal echocardiographic left ventricular dimensions. All 5 of the B2 patients and 3 of 7 of the B1 patients with discrepant diagnoses had a moderate MRSS whereas the remaining 4 of 7 B1 patients had a mild MRSS. No diagnostic discrepancies between LA:Ao and LA Vol/BW were observed in dogs with a severe MRSS. Additionally, there were no cases that had LAE based on LA:Ao in which LA Vol/BW exceeded our cut-off of 1.1 ml/kg.

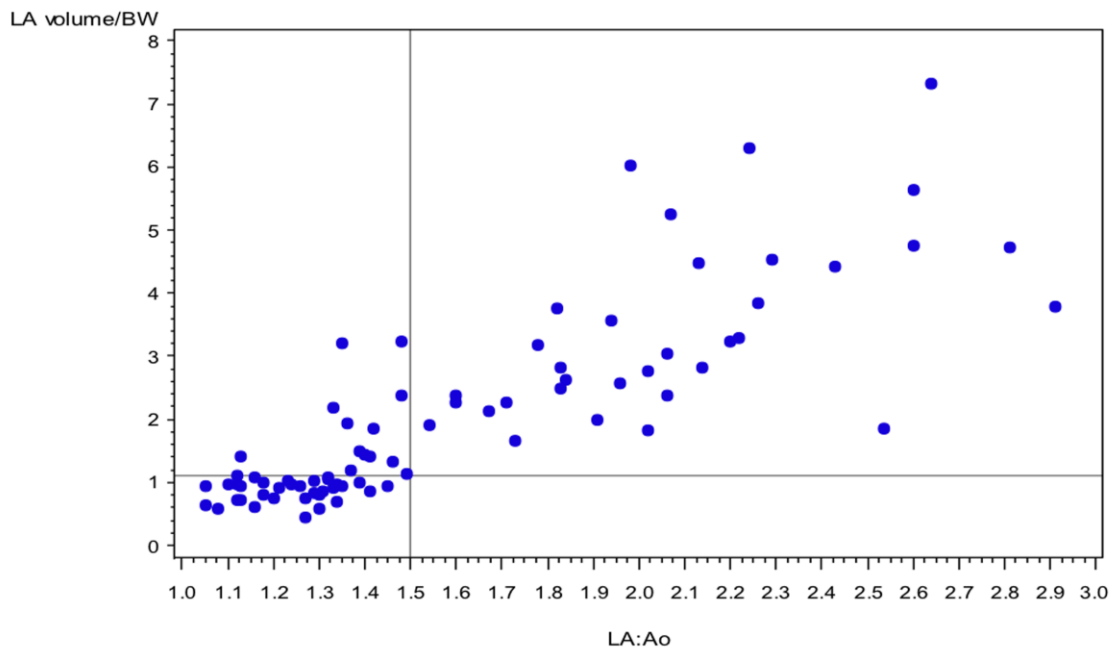


Figure 3: Scatterplot showing classification agreement between LA Vol/BW and LA:Ao. The threshold for identification of LAE was 1.5 for LA:Ao and 1.1mlkg for LA Vol/BW. Twelve dogs are identified in the upper left hand corner of the scatterplot. These dogs were identified as normal based on LA:Ao but exceeded the threshold for LAE based on LA Vol/BW.

For normal patients, most of the variation in the measurement of LA Vol/BW was attributed to variability among dogs. More specifically, the dog-to-dog variation accounted for approximately 90.8% of the total variability in measurement of LA Vol/BW, as indicated by the ratio of the corresponding variance component estimates (i.e. between-dog variance over total variance) and amounted to an estimated standard deviation of 0.45 ml/kg of LA Vol/BW among normal dogs. The remainder of the dispersion was explained by variability between operators (approximately 5.1%) and by measurement error of a single operator over repeated measures (approximately 4.1%).

After accounting for dog-to-dog variability, we assessed repeatability and reproducibility of LA Vol/BW measurements using corresponding variance component estimates.²⁶ Intra-operator repeatability refers to the proportion of the variability explained by repeated measurements taken by the same operator on a given dog and characterizes the variability within operators. It is also referred to as measurement error. After accounting for variability among dogs, repeatability for LA volume within operator was estimated as the ratio of the between-operator variance and the sum of the between- and within-operator variances. Estimated within-operator repeatability in LA Vol/BW observations was approximately 55.6%, such that measurement error on LA Vol/BW among repeated measures taken by the same operator was characterized by an estimated standard deviation of approximately 0.10 ml/kg. This value characterizes measurement error and was obtained as the square root of the estimated within-operator variance component.

In turn, reproducibility between operators in LA Vol/BW measurements was estimated at approximately 44.4% after accounting for dog-to-dog variation. Reproducibility quantifies the relative contribution of measurements by multiple operators to the overall variability in measurement of LA Vol/BW, after taking into consideration between-dog variance. On average, the estimated standard deviation between operators was approximately 0.11 ml/kg of LA Vol/BW. This value was obtained as the square root of the estimated between-operator variance component.

Dogs were the primary source of variability in the measurement of LA Vol/BW and explained >90% of the variability. After accounting for dog-to-dog variability, the point estimate for repeatability

within operators was larger than that for reproducibility between operators, and both point estimates were very similar (55.6 vs 44.4%, respectively). These estimates support the consistency of measurement of LA Vol/BW by different operators, because the relative magnitude of the variability due to multiple operators was not any larger than the proportion of the variability observed when a single operator was collecting repeated measurements. In addition, the magnitudes of the variance component estimates for between-operator (i.e. $[0.11 \text{ ml/kg}]^2$) and within-operator variability (i.e. $[0.10 \text{ ml/kg}]^2$) were small.

g. Discussion

This study identified a significant diagnostic disagreement between LA Vol/BW as determined by the biplane area-length method and LA:Ao in identification of LAE in the dog. Specifically, LA Vol/BW was superior to LA:Ao in identification of mild LAE. The ability of volumetric methods to account for enlargement of the left atrium in more than just 1 dimension may explain why LA Vol/BW identified LAE in a subset of dogs that was not identified by LA:Ao. A unidimensional measurement of left atrial size must reflect a consistent relationship to the other dimensions of the left atrial chamber in order to accurately reflect true left atrial size.²⁷ In humans, physical constraints imposed by the sternum and spine limit the amount of LAE that can occur in the anteroposterior dimension, thus this single dimension may underestimate true atrial size.²⁸ Similarly, limitations specific to canine anatomy or simple variability from individual to individual may contribute to asymmetric enlargement of the left atrium in the dog. This is further supported by our finding that most of the variability observed in LA Vol/BW measurements was explained by dog-specific factors (i.e. dog-to-dog variance).

In both human and veterinary cardiology, multiple echocardiographic methods have been used to quantify left atrial size including M-mode linear dimensions, 2-D linear dimensions, left atrial areas and left atrial volumes. As of 2005, the American Society of Echocardiography established left atrial volume measured by either the biplane area-length method or the biplane Simpson's method of discs as the standard for left atrial size assessment.¹⁶ The shift toward biplane volumetric assessment is based on the superiority of these measurements as prognostic markers and predictors of future cardiovascular risk in

people,²⁹⁻³¹ as well as their correlation with various imaging modalities^{9-11,13}. Recent work in people suggests that, relative to the biplane Simpson's method of discs, the biplane area-length method may provide superior estimates of left atrial volume.⁸

The MRSS system developed for this study was based on previously published recommendations for echocardiographic evaluation of the severity of native valvular regurgitation in humans²⁴, with modifications to simplify the scoring system in such a way that the selected parameters could easily be evaluated in every patient. Additionally, parameters related to left atrial size were eliminated to allow the MRSS to serve as an independent reflection of disease severity when comparing severity score to LA:Ao or LA Vol/BW obtained from individual patients. Eight of the 12 patients in which diagnostic disagreement was identified had a moderate MRSS. This suggests that in many of these discrepant cases there was echocardiographic evidence unrelated to left atrial size that was consistent with advanced MMVD. This observation lends support to the conclusion that LAE identified by the LA Vol/BW method in these discrepant cases actually was present. There was no diagnostic disagreement in those dogs with a severe MRSS, suggesting that in cases of advanced MMVD, LA Vol/BW and LA:Ao both reliably detect severe LAE.

Additional study is needed to determine whether the prognostic value of LA Vol/BW is superior to that of LA:Ao. The traditional LA:Ao measurement is simpler and less time consuming to calculate than is LA Vol/BW, thus an advantage in patient monitoring, prognostic relevance or both should be sought before exclusive use of LA Vol/BW can be recommended. A prospective longitudinal study investigating the use of LA Vol/BW in dogs affected with MMVD is warranted.

Limitations of this study include a significantly older study group relative to the control group. Given the acquired and highly prevalent nature of MMVD in dogs, an age-matched control group could not be obtained. Some studies in humans have detected an age-related increase in left atrial size^{32,33} whereas others have not.^{11,34} Increasing left atrial size may not reflect normal aging, but rather subclinical pathology³⁵. Recent research in dogs found no evidence for correlation between left atrial volume and age but the median age of the dogs in that study was relatively low at 3.5 years.¹⁴

Furthermore, in this study, we did not consider breed-related differences in left atrial volume between control and study populations. Significant differences in left atrial volume have been documented in dogs with normal cardiovascular status of different breeds¹⁴. Notably, none of the previously reported breed-specific left atrial volumes in normal dogs were above our established cut-off of 1.1 ml/kg with the exception of the Petit Basset Griffon Vendeen which had an upper 95% percentile volume of 1.12 ml/kg.¹⁴ Despite the many breeds represented in our study, we believe our suggested cut-off of 1.1 ml/kg for LA Vol/BW provided a reasonable delineation between normal and abnormal dogs. More work is needed to further characterize this proposed threshold.

Finally, we did not include assessment of left atrial size by gold standard diagnostic imaging such as MSCT or CMR, nor did we compare 2-D echocardiography and RT3D echocardiography. Comparison to MSCT or CMR would have better elucidated the accuracy of both LA:Ao and LA Vol/BW in their assessment of estimated left atrial size, and evaluation of RT3D echocardiography would have permitted assessment of agreement between 2D LA volume estimates obtained using a biplane method and RT3D-derived LA volume. Although relationships between linear 2D measures of left atrial size and RT3D LA volumes have been described, correlations generally were weak.³⁶ Agreement between estimates of left atrial volume from RT3D and 2D echocardiography has not been investigated. Ideally, further research should be conducted to provide such comparisons, however the more clinically relevant questions are related to the ease and accessibility of obtaining the measurements as well as their prognostic value, not necessarily to their ability to obtain volumes identical to those obtained by RT3D echocardiography, MSCT or CMR.

In conclusion, we propose a cut-off value of 1.1 ml/kg for LA Vol/BW measured in normal dogs using the biplane area-length method. Significant diagnostic disagreement in identification of LAE exists between LA Vol/BW and the traditionally used LA:Ao. LA Vol/BW may be superior to LA:Ao in identification of mild LAE.

Footnotes

^a811-B, Parks Medical Electronics, Inc, Aloha, OR

^b Vivid 7; GE-Medical, Milwaukee, WI

h. References

1. Borgarelli M, Haggstrom J. Canine degenerative myxomatous mitral valve disease: natural history, clinical presentation and therapy. *Vet Clin North Am Small Anim Pract* 2010;40:651-663.
2. Detweiler DK, Patterson DF. The prevalence and types of cardiovascular disease in dogs. *Ann N Y Acad Sci* 1965;127:481-516.
3. Borgarelli M, Savarino P, Crosara S, et al. Survival characteristics and prognostic variables of dogs with mitral regurgitation attributable to myxomatous valve disease. *J Vet Intern Med* 2008;22:120-128.
4. Haggstrom J, Boswood A, O'Grady M, et al. Effect of pimobendan or benazepril hydrochloride on survival times in dogs with congestive heart failure caused by naturally occurring myxomatous mitral valve disease: the QUEST study. *J Vet Intern Med* 2008;22:1124-1135.
5. Hansson K, Haggstrom J, Kvarn C, et al. Left atrial to aortic root indices using two-dimensional and M-mode echocardiography in cavalier King Charles spaniels with and without left atrial enlargement. *Veterinary Radiology & Ultrasound* 2002;43:568-575.
6. Rishniw M, Erb HN. Evaluation of four 2-dimensional echocardiographic methods of assessing left atrial size in dogs. *Journal of Veterinary Internal Medicine* 2000;14:429-435.
7. Tsang MY, Barnes ME, Tsang TS. Left atrial volume: clinical value revisited. *Curr Cardiol Rep* 2012;14:374-380.
8. Al-Mohaisen MA, Kazmi MH, Chan KL, et al. Validation of Two-Dimensional Methods for Left Atrial Volume Measurement: A Comparison of Echocardiography with Cardiac Computed Tomography. *Echocardiography* 2013.
9. Kircher B, Abbott JA, Pau S, et al. Left atrial volume determination by biplane two-dimensional echocardiography: validation by cine computed tomography. *Am Heart J* 1991;121:864-871.
10. Vandenberg BF, Weiss RM, Kinzey J, et al. Comparison of left atrial volume by two-dimensional echocardiography and cine-computed tomography. *Am J Cardiol* 1995;75:754-757.
11. Messika-Zeitoun D, Bellamy M, Avierinos JF, et al. Left atrial remodelling in mitral regurgitation--methodologic approach, physiological determinants, and outcome implications: a prospective quantitative Doppler-echocardiographic and electron beam-computed tomographic study. *Eur Heart J* 2007;28:1773-1781.
12. Tidholm A, Westling AB, Hoglund K, et al. Comparisons of 3-, 2-dimensional, and M-mode echocardiographical methods for estimation of left chamber volumes in dogs with and without acquired heart disease. *Journal of Veterinary Internal Medicine* 2010;24:1414-1420.
13. Rodevan O, Bjornerheim R, Ljosland M, et al. Left atrial volumes assessed by three- and two-dimensional echocardiography compared to MRI estimates. *Int J Card Imaging* 1999;15:397-410.
14. Hollmer M, Willeisen JL, Tolver A, et al. Left atrial volume and phasic function in clinically healthy dogs of 12 different breeds. *Vet J* 2013.
15. Brown S, Atkins C, Bagley R, et al. Guidelines for the identification, evaluation, and management of systemic hypertension in dogs and cats. *J Vet Intern Med* 2007;21:542-558.
16. Lang RM, Bierig M, Devereux RB, et al. Recommendations for chamber quantification: a report from the American Society of Echocardiography's Guidelines and Standards Committee and the Chamber Quantification Writing Group, developed in conjunction with the European Association of

Echocardiography, a branch of the European Society of Cardiology. *J Am Soc Echocardiogr* 2005;18:1440-1463.

17. Atkins C, Bonagura J, Ettinger S, et al. Guidelines for the diagnosis and treatment of canine chronic valvular heart disease. *J Vet Intern Med* 2009;23:1142-1150.
18. Cornell CC, Kittleson MD, Della Torre P, et al. Allometric scaling of M-mode cardiac measurements in normal adult dogs. *J Vet Intern Med* 2004;18:311-321.
19. Ljungvall I, Hoglund K, Carnabuci C, et al. Assessment of global and regional left ventricular volume and shape by real-time 3-dimensional echocardiography in dogs with myxomatous mitral valve disease. *J Vet Intern Med* 2011;25:1036-1043.
20. Muzzi RA, de Araujo RB, Muzzi LA, et al. Regurgitant jet area by Doppler color flow mapping: quantitative assessment of mitral regurgitation severity in dogs. *J Vet Cardiol* 2003;5:33-38.
21. Borgarelli M, Crosara S, Lamb K, et al. Survival characteristics and prognostic variables of dogs with preclinical chronic degenerative mitral valve disease attributable to myxomatous degeneration. *Journal of Veterinary Internal Medicine* 2012;26:69-75.
22. Hezzell MJ, Boswood A, Chang YM, et al. The combined prognostic potential of serum high-sensitivity cardiac troponin I and N-terminal pro-B-type natriuretic peptide concentrations in dogs with degenerative mitral valve disease. *J Vet Intern Med* 2012;26:302-311.
23. Terzo E, Di Marcello M, McAllister H, et al. Echocardiographic assessment of 537 dogs with mitral valve prolapse and leaflet involvement. *Vet Radiol Ultrasound* 2009;50:416-422.
24. Zoghbi WA, Enriquez-Sarano M, Foster E, et al. Recommendations for evaluation of the severity of native valvular regurgitation with two-dimensional and Doppler echocardiography. *J Am Soc Echocardiogr* 2003;16:777-802.
25. Ljungvall I, Hoglund K, Lilliehook I, et al. Serum serotonin concentration is associated with severity of myxomatous mitral valve disease in dogs. *Journal of Veterinary Internal Medicine* 2013;27:1105-1112.
26. Burdick RK, Borrer CM, Montgomery DC. A review of methods for measurement systems capability analysis. *Journal of Quality Technology* 2003;35:342-354.
27. Lester SJ, Ryan EW, Schiller NB, et al. Best method in clinical practice and in research studies to determine left atrial size. *Am J Cardiol* 1999;84:829-832.
28. Schabelman S, Schiller NB, Silverman NH, et al. Left atrial volume estimation by two-dimensional echocardiography. *Cathet Cardiovasc Diagn* 1981;7:165-178.
29. Tsang TS, Abhayaratna WP, Barnes ME, et al. Prediction of cardiovascular outcomes with left atrial size: is volume superior to area or diameter? *J Am Coll Cardiol* 2006;47:1018-1023.
30. Le Tourneau T, Messika-Zeitoun D, Russo A, et al. Impact of left atrial volume on clinical outcome in organic mitral regurgitation. *J Am Coll Cardiol* 2010;56:570-578.
31. Tamura H, Watanabe T, Nishiyama S, et al. Increased left atrial volume index predicts a poor prognosis in patients with heart failure. *J Card Fail* 2011;17:210-216.
32. Spencer KT, Mor-Avi V, Gorcsan J, 3rd, et al. Effects of aging on left atrial reservoir, conduit, and booster pump function: a multi-institution acoustic quantification study. *Heart* 2001;85:272-277.
33. Nikitin NP, Witte KK, Thackray SD, et al. Effect of age and sex on left atrial morphology and function. *Eur J Echocardiogr* 2003;4:36-42.
34. Thomas L, Levett K, Boyd A, et al. Compensatory changes in atrial volumes with normal aging: is atrial enlargement inevitable? *J Am Coll Cardiol* 2002;40:1630-1635.
35. Lakatta EG, Levy D. Arterial and cardiac aging: major shareholders in cardiovascular disease enterprises: Part II: the aging heart in health: links to heart disease. *Circulation* 2003;107:346-354.
36. Tidholm A, Bodegard-Westling A, Hoglund K, et al. Comparisons of 2- and 3-dimensional echocardiographic methods for estimation of left atrial size in dogs with and without myxomatous mitral valve disease. *Journal of Veterinary Internal Medicine* 2011;25:1320-1327.

4. Conclusions

Despite the frequency with which MMVD is diagnosed, there is a paucity of data regarding the echocardiographic anatomy of both normal canine mitral valves and mitral valves affected by MMVD. The first study presented here proposes reference intervals for the length, width and area of the anterior mitral valve leaflet as well as the diameter of the mitral valve annulus in systole and diastole over a range of body sizes. It also demonstrates that, relative to the control population, dogs with advanced MMVD have significantly greater values of each of the studied mitral valve measurements.

Additionally, left atrial size is one of the most important prognostic factors in dogs with MMVD. At this time the modalities most commonly utilized in human cardiology for measurement of left atrial size have not been thoroughly studied or implemented on a regular basis in veterinary cardiology. The second study presented here proposes a cut-off value of 1.1 ml/kg for LA Vol/BW obtained using the biplane area-length method. It also demonstrates that a significant diagnostic disagreement in identification of left atrial enlargement exists between LA:Ao and LA Vol/BW. Although LA:Ao is the current method of choice for assessment of left atrial size in veterinary cardiology, the data presented here suggests that LA Vol/BW may be a superior measurement for identification of mild left atrial enlargement.

References:

1. Fenoglio JJ, Jr., Tuan Duc P, Wit AL, et al. Canine mitral complex. Ultrastructure and electromechanical properties. *Circ Res* 1972;31:417-430.
2. Borgarelli M, Tursi M, La Rosa G, et al. Anatomic, histologic, and two-dimensional-echocardiographic evaluation of mitral valve anatomy in dogs. *Am J Vet Res* 2011;72:1186-1192.
3. Perloff JK, Roberts WC. The mitral apparatus. Functional anatomy of mitral regurgitation. *Circulation* 1972;46:227-239.
4. McCarthy KP, Ring L, Rana BS. Anatomy of the mitral valve: understanding the mitral valve complex in mitral regurgitation. *Eur J Echocardiogr* 2010;11:i3-9.
5. Frater RW, Ellis FH, Jr. The anatomy of the canine mitral valve, with notes on function and comparisons with other mammalian mitral valves. *J Surg Res* 1961;1:171-178.
6. Fox PR. Pathology of myxomatous mitral valve disease in the dog. *J Vet Cardiol* 2012;14:103-126.
7. Han RI, Black A, Culshaw G, et al. Structural and cellular changes in canine myxomatous mitral valve disease: an image analysis study. *J Heart Valve Dis* 2010;19:60-70.
8. Buchanan JW. Chronic valvular disease (endocardiosis) in dogs. *Adv Vet Sci Comp Med* 1977;21:75-106.
9. Lam JH, Ranganathan N, Wigle ED, et al. Morphology of the human mitral valve. I. Chordae tendineae: a new classification. *Circulation* 1970;41:449-458.
10. Salgo IS, Gorman JH, 3rd, Gorman RC, et al. Effect of annular shape on leaflet curvature in reducing mitral leaflet stress. *Circulation* 2002;106:711-717.
11. Trafny DJ, Freeman LM, Bulmer BJ, et al. Auscultatory, echocardiographic, biochemical, nutritional, and environmental characteristics of mitral valve disease in Norfolk terriers. *J Vet Cardiol* 2012;14:261-267.
12. Detweiler DK, Patterson DF. The prevalence and types of cardiovascular disease in dogs. *Ann N Y Acad Sci* 1965;127:481-516.
13. Borgarelli M, Haggstrom J. Canine degenerative myxomatous mitral valve disease: natural history, clinical presentation and therapy. *Vet Clin North Am Small Anim Pract* 2010;40:651-663.
14. Borgarelli M, Buchanan JW. Historical review, epidemiology and natural history of degenerative mitral valve disease. *J Vet Cardiol* 2012;14:93-101.
15. Whitney JC. Observations on the effect of age on the severity of heart valve lesions in the dog. *Journal of Small Animal Practice* 1974;15:511-522.
16. Pomerance A, Whitney JC. Heart valve changes common to man and dog: a comparative study. *Cardiovasc Res* 1970;4:61-66.
17. Pedersen HD, Haggstrom J. Mitral valve prolapse in the dog: a model of mitral valve prolapse in man. *Cardiovasc Res* 2000;47:234-243.
18. Atkins C, Bonagura J, Ettinger S, et al. Guidelines for the diagnosis and treatment of canine chronic valvular heart disease. *J Vet Intern Med* 2009;23:1142-1150.
19. Borgarelli M, Savarino P, Crosara S, et al. Survival characteristics and prognostic variables of dogs with mitral regurgitation attributable to myxomatous valve disease. *J Vet Intern Med* 2008;22:120-128.
20. Haggstrom J, Boswood A, O'Grady M, et al. Effect of pimobendan or benazepril hydrochloride on survival times in dogs with congestive heart failure caused by naturally occurring myxomatous mitral valve disease: the QUEST study. *J Vet Intern Med* 2008;22:1124-1135.
21. Serres F, Chetboul V, Tissier R, et al. Chordae tendineae rupture in dogs with degenerative mitral valve disease: prevalence, survival, and prognostic factors (114 cases, 2001-2006). *J Vet Intern Med* 2007;21:258-264.

22. Hansson K, Haggstrom J, Kwart C, et al. Left atrial to aortic root indices using two-dimensional and M-mode echocardiography in cavalier King Charles spaniels with and without left atrial enlargement. *Veterinary Radiology & Ultrasound* 2002;43:568-575.
23. Rishniw M, Erb HN. Evaluation of four 2-dimensional echocardiographic methods of assessing left atrial size in dogs. *Journal of Veterinary Internal Medicine* 2000;14:429-435.
24. Tsang MY, Barnes ME, Tsang TS. Left atrial volume: clinical value revisited. *Curr Cardiol Rep* 2012;14:374-380.
25. Lang RM, Bierig M, Devereux RB, et al. Recommendations for chamber quantification: a report from the American Society of Echocardiography's Guidelines and Standards Committee and the Chamber Quantification Writing Group, developed in conjunction with the European Association of Echocardiography, a branch of the European Society of Cardiology. *J Am Soc Echocardiogr* 2005;18:1440-1463.
26. Hollmer M, Willesen JL, Tolver A, et al. Left atrial volume and phasic function in clinically healthy dogs of 12 different breeds. *Vet J* 2013.
27. Tidholm A, Westling AB, Høglund K, et al. Comparisons of 3-, 2-dimensional, and M-mode echocardiographical methods for estimation of left chamber volumes in dogs with and without acquired heart disease. *Journal of Veterinary Internal Medicine* 2010;24:1414-1420.
28. Tidholm A, Bodegard-Westling A, Høglund K, et al. Comparisons of 2- and 3-dimensional echocardiographic methods for estimation of left atrial size in dogs with and without myxomatous mitral valve disease. *Journal of Veterinary Internal Medicine* 2011;25:1320-1327.
29. Al-Mohaisen MA, Kazmi MH, Chan KL, et al. Validation of Two-Dimensional Methods for Left Atrial Volume Measurement: A Comparison of Echocardiography with Cardiac Computed Tomography. *Echocardiography* 2013.
30. Kircher B, Abbott JA, Pau S, et al. Left atrial volume determination by biplane two-dimensional echocardiography: validation by cine computed tomography. *Am Heart J* 1991;121:864-871.
31. Vandenberg BF, Weiss RM, Kinzey J, et al. Comparison of left atrial volume by two-dimensional echocardiography and cine-computed tomography. *Am J Cardiol* 1995;75:754-757.
32. Messika-Zeitoun D, Bellamy M, Avierinos JF, et al. Left atrial remodelling in mitral regurgitation--methodologic approach, physiological determinants, and outcome implications: a prospective quantitative Doppler-echocardiographic and electron beam-computed tomographic study. *Eur Heart J* 2007;28:1773-1781.
33. Terzo E, Di Marcello M, McAllister H, et al. Echocardiographic assessment of 537 dogs with mitral valve prolapse and leaflet involvement. *Vet Radiol Ultrasound* 2009;50:416-422.
34. David TE, Ivanov J, Armstrong S, et al. A comparison of outcomes of mitral valve repair for degenerative disease with posterior, anterior, and bileaflet prolapse. *J Thorac Cardiovasc Surg* 2005;130:1242-1249.